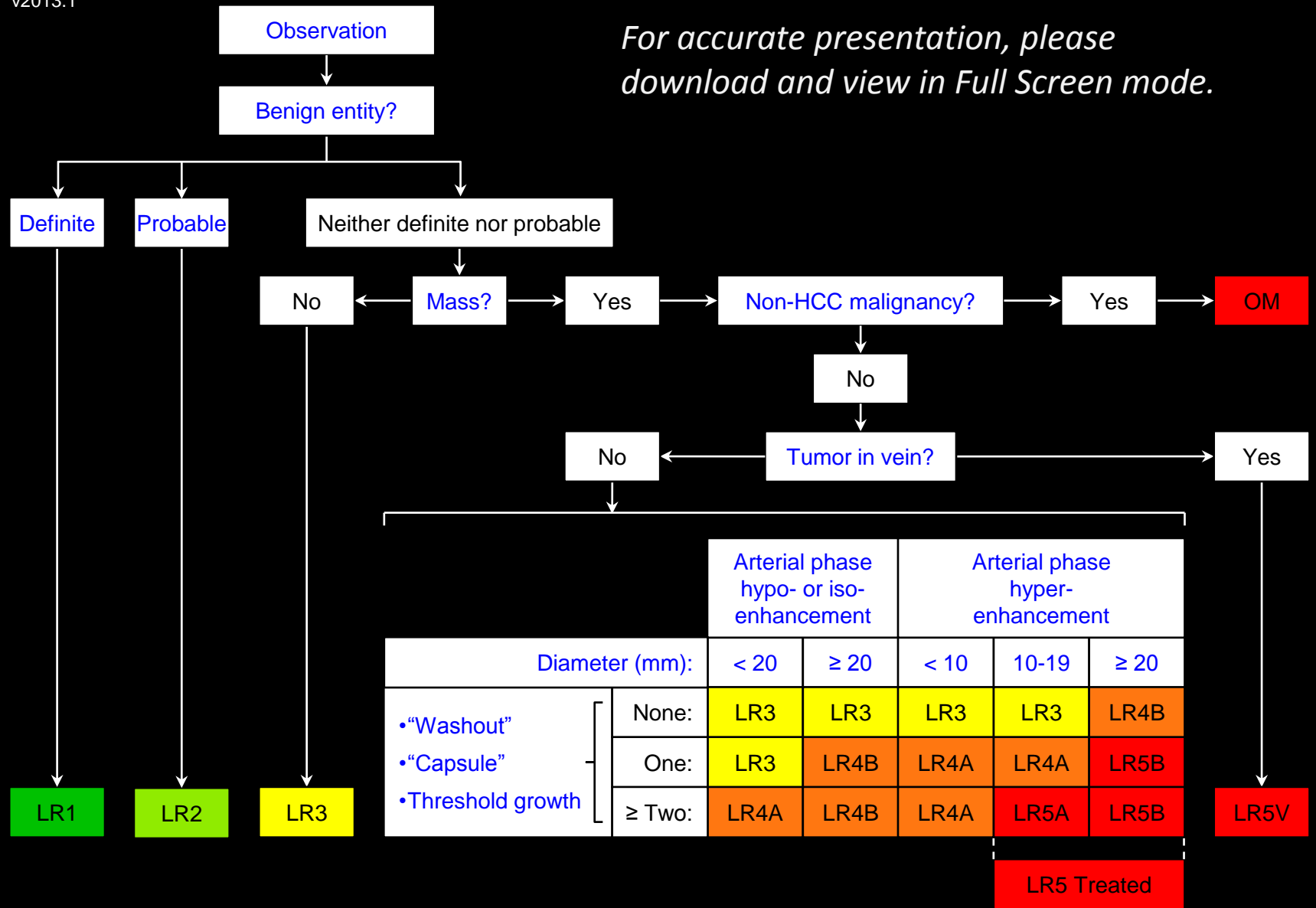




*For accurate presentation, please download and view in Full Screen mode.*



← Apply Ancillary Features and then Tie-Breaking Rules to Adjust Category →



## Introduction

### What is LI-RADS (Liver Imaging Reporting And Data System)?

- A system of standardized terminology and criteria to interpret and report imaging examinations of the liver.
- Supported and endorsed by the American College of Radiology (ACR).
- LI-RADS is a dynamic document: it will be expanded and refined as knowledge accrues and in response to user feedback.

### Who is developing LI-RADS?

- LI-RADS is being developed by an ACR-supported committee of diagnostic radiologists with expertise in liver imaging.
- The committee receives input from hepatobiliary surgeons, hepatologists, hepatopathologists, and interventionalists.

### In what patient population does LI-RADS apply?

- LI-RADS currently applies to patients with cirrhosis or at risk for HCC.

### What imaging modalities are addressed by LI-RADS?

- LI-RADS currently applies to CT and MRI performed with extracellular contrast agents.
- LI-RADS soon will be expanded to apply to hepatobiliary contrast agents.

### Who can use LI-RADS?

- LI-RADS may be used by community and academic radiologists.

### How does LI-RADS work?

- LI-RADS [categorizes observations](#) from LR1 to LR5, reflecting probability of benignity or HCC in at-risk patients.

### [What's new in LI-RADS v2013.1?](#)

Continue to LI-RADS v2013.1 



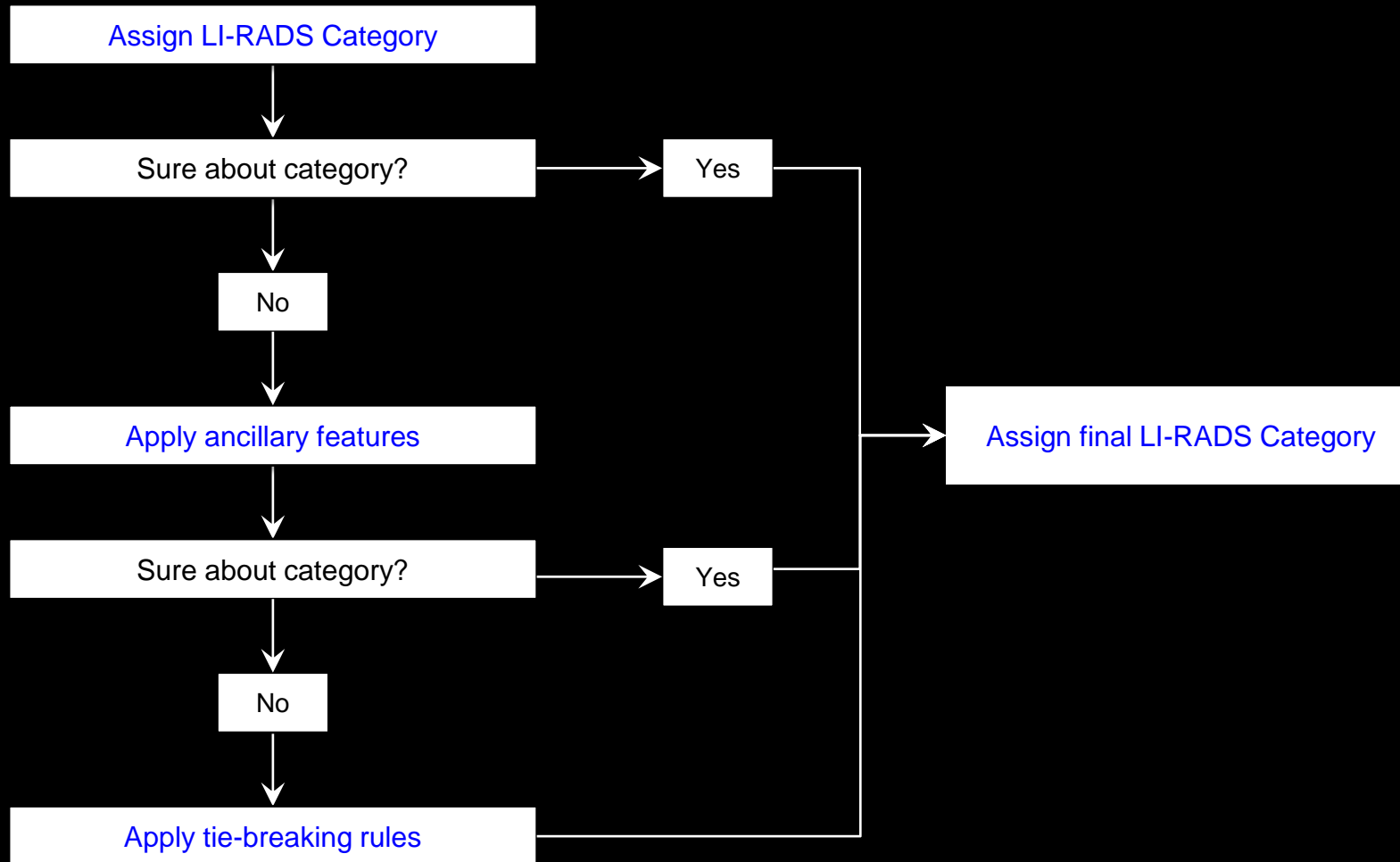
## What's New in LI-RADS v2013.1

### LI-RADS v2013.1 features several enhancements:

- New [algorithmic display](#).
- Expanded and refined LI-RADS lexicon.
- New illustrative atlas.
- New material on imaging [technique](#) and [management](#).
- Updated criterion for [tumor in vein](#).
- New [OM \(Other Malignancy\)](#) category to address malignant entities other than HCC that may occur in patients with cirrhosis or other risk factors for HCC.
- New [tie-breaking rules](#) to guide assignment of final LR category.

### LI-RADS v2013.1 also includes key modifications to achieve congruency between [LR5](#) and [OPTN Class 5](#):

- [Capsule appearance](#), previously an ancillary feature, now is a major feature.
- The major feature, “portal venous phase or later phase hypo-enhancement relative to liver”, has been renamed [washout appearance](#) to more closely match OPTN terminology.
- The definition of [threshold growth](#) was updated.
- [Ancillary features](#) that favor HCC, which previously could be applied to upgrade category up to LR5, now can be applied to upgrade category only up to [LR4](#).
- New [LR5 Treated](#) category to match OPTN 5T category.



### Adjusting LI-RADS category:

Assignment of LI-RADS category is described in [Overview](#).

If unsure about category, apply [ancillary features](#) to upgrade category by one or more categories (up to but not beyond LR4) or to downgrade category by one or more categories.

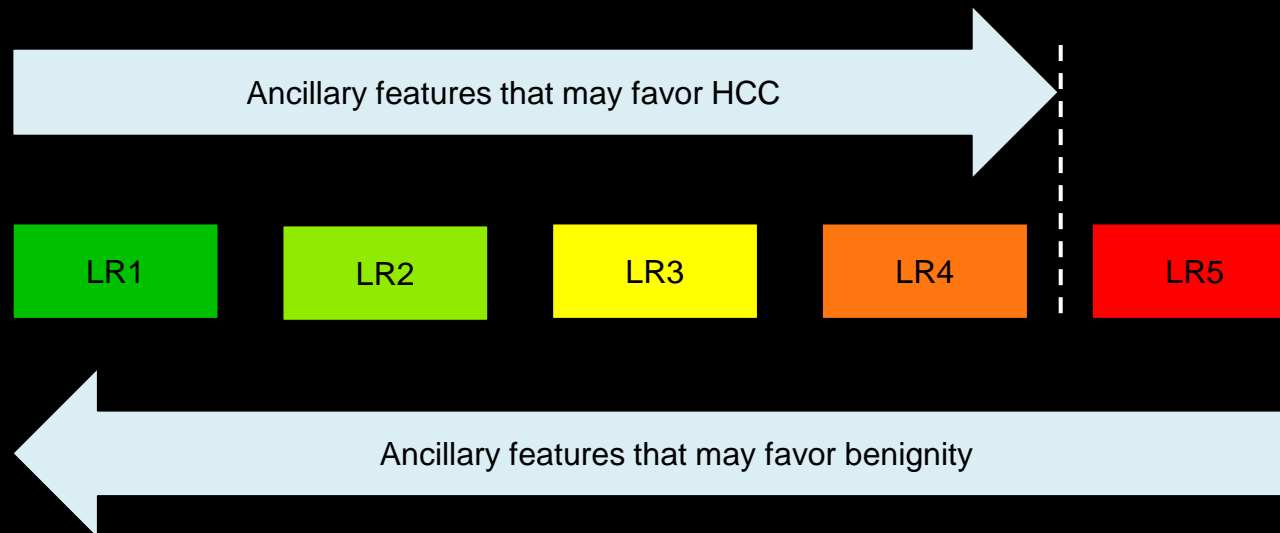
If still unsure after applying ancillary features, then apply [tie-breaking rules](#).

**Adjusting LI-RADS category:** Flow chart illustrates the sequence with which ancillary features and tie-breaking rules may be applied to adjust LI-RADS category. As shown in schematic, ancillary features and tie-breaking rules should be applied if there is uncertainty in the category. Note that tie-breaking rules should be applied if there is still uncertainty after application of ancillary features.





**Ancillary features that may favor HCC** may be applied to upgrade category by one or more categories (up to but not beyond LR4). They cannot be used to upgrade category to LR5. Absence of these features should not be used to downgrade the LR category.



**Ancillary features that may favor benignity** may be applied to downgrade category by one or more categories. Absence of these features should not be used to upgrade the LR category.

### Ancillary features:

Imaging features that modify likelihood of HCC. In isolation, these features do not permit reliable categorization of observations and hence are considered ancillary.

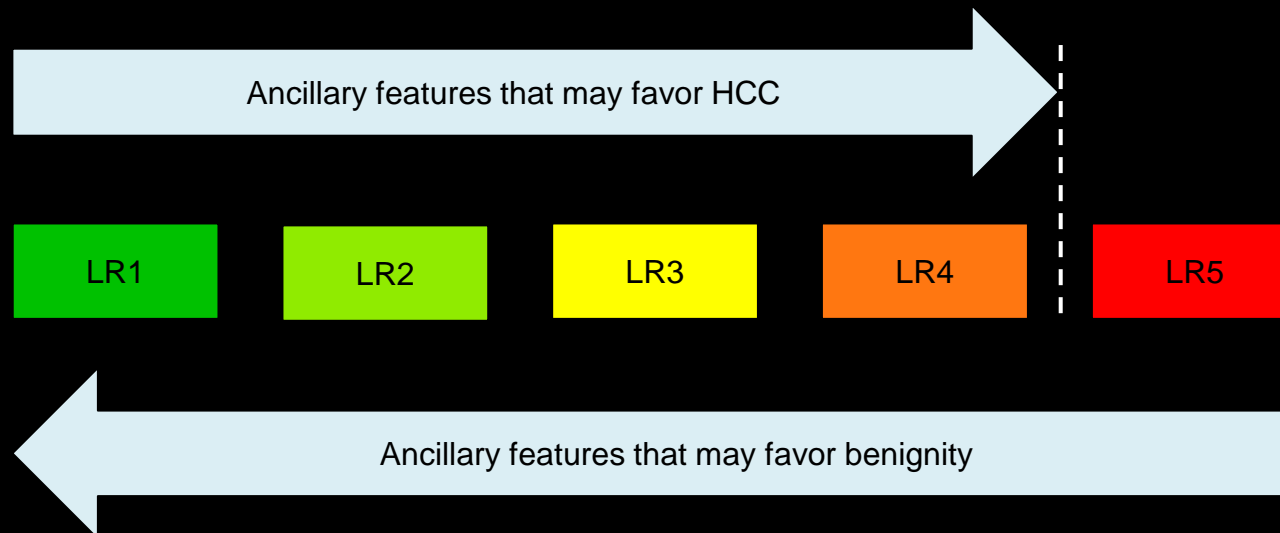
### Comments:

- Radiologists may at their discretion apply ancillary features to adjust category as follows:
  - Features that may favor HCC to upgrade category by one or more categories (up to but not beyond LR4).
  - Features that may favor benignity to downgrade category by one or more categories.
- The reason that ancillary features cannot be used to upgrade category to LR5 is to maintain congruency with OPTN.
- Review when to apply ancillary features to [adjust LI-RADS category](#).

### [Features that may favor HCC vs. features that may favor benignity](#)



**Ancillary features that may favor HCC** may be applied to upgrade category by one or more categories (up to but not beyond LR4). They cannot be used to upgrade category to LR5. Absence of these features should not be used to downgrade the LR category.



**Ancillary features that may favor benignity** may be applied to downgrade category by one or more categories. Absence of these features should not be used to upgrade the LR category.

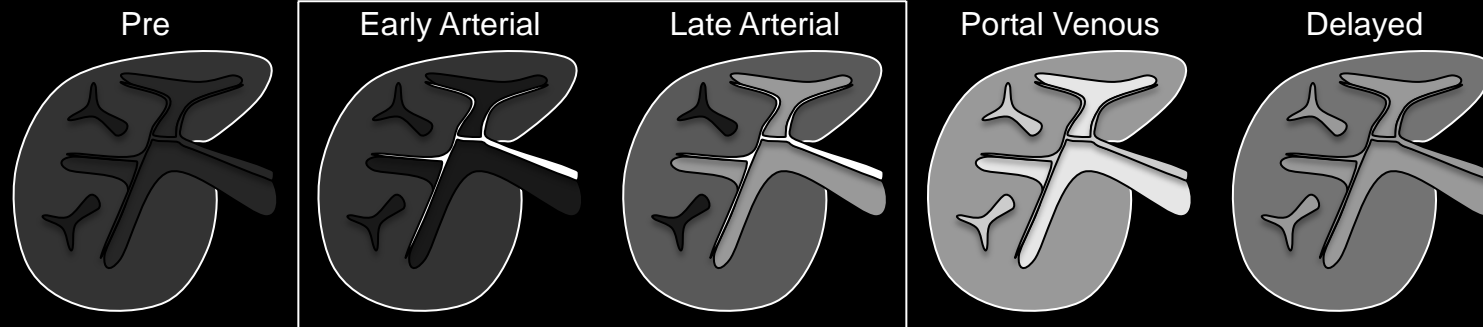
### Ancillary features:

#### Features that may favor HCC:

- [Mild-moderate T2 hyper-intensity](#)
- [Restricted diffusion](#)
- [Corona enhancement](#)
- [Mosaic architecture](#)
- [Nodule-in-nodule architecture](#)
- [Intra-lesional fat](#)
- [Lesional iron sparing](#)
- [Lesional fat sparing](#)
- [Blood products](#)
- [Diameter increase](#) less than [threshold growth](#)

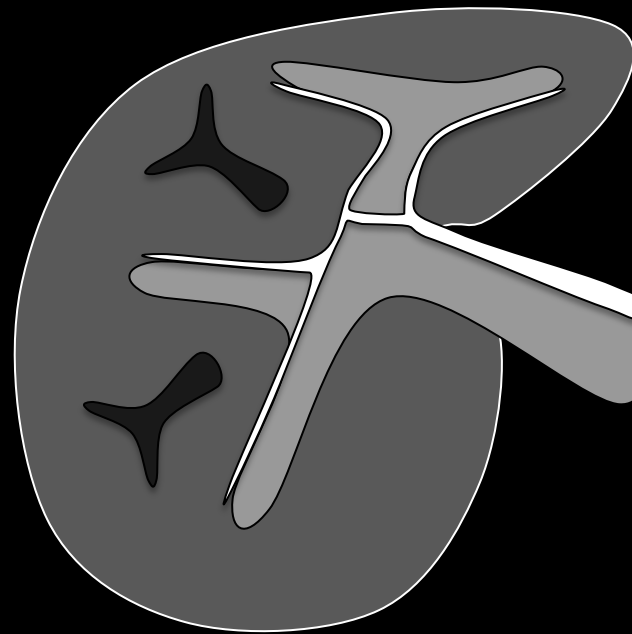
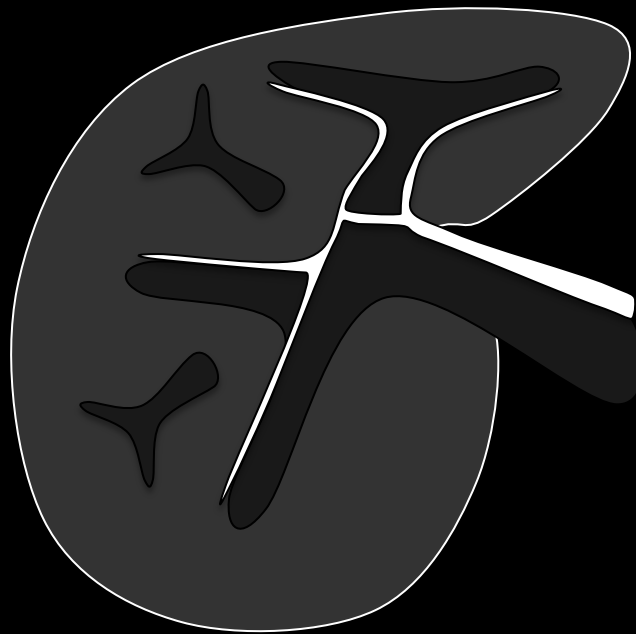
#### Features that may favor benignity:

- [Homogeneous marked T2 hyper-intensity](#)
- [Homogeneous marked T2 or T2\\* hypo-intensity](#)
- [Undistorted vessels](#)
- [Parallels blood pool enhancement](#)
- [Diameter reduction](#)
- [Diameter stability](#)  $\geq 2$  years



Early Arterial Phase

Late Arterial Phase



**Arterial phase:** Schematic diagrams depict pre-contrast and post-extracellular contrast early arterial, late arterial, portal venous, and delayed phase images. Arterial phase is defined by full enhancement of hepatic arteries and absence of antegrade enhancement of hepatic veins. In the early arterial phase, portal vein is unenhanced. In later arterial phase, portal vein is enhanced. Late arterial phase is strongly preferred for HCC diagnosis and staging.

## Arterial phase:

In LI-RADS, the arterial phase refers to the hepatic arterial phase unless otherwise specified. The arterial phase is a post-contrast injection time range in which images have the following characteristics:

- Hepatic artery and branches are fully enhanced.
- Hepatic veins not yet enhanced by antegrade flow.

## Comments:

- Arterial phase imaging is required for both CT and MRI.
- Hepatic arterial phase may be subclassified as early and late hepatic arterial phase.
  - Early hepatic arterial phase: portal vein is not yet enhanced.
  - Late hepatic arterial phase: portal vein is enhanced.
- Late hepatic arterial phase is **strongly** preferred for HCC diagnosis and staging, because the degree of enhancement in HCC usually is higher in the late than in the early hepatic arterial phase. Some HCCs may show hyper-enhancement only in the late hepatic arterial phase.
- At MRI, aorta may not be brightly enhanced.
  - With short bolus durations, contrast material bolus may pass beyond aorta by time of image acquisition.

Atlas: [CT](#), [MR](#)



### Arterial phase:

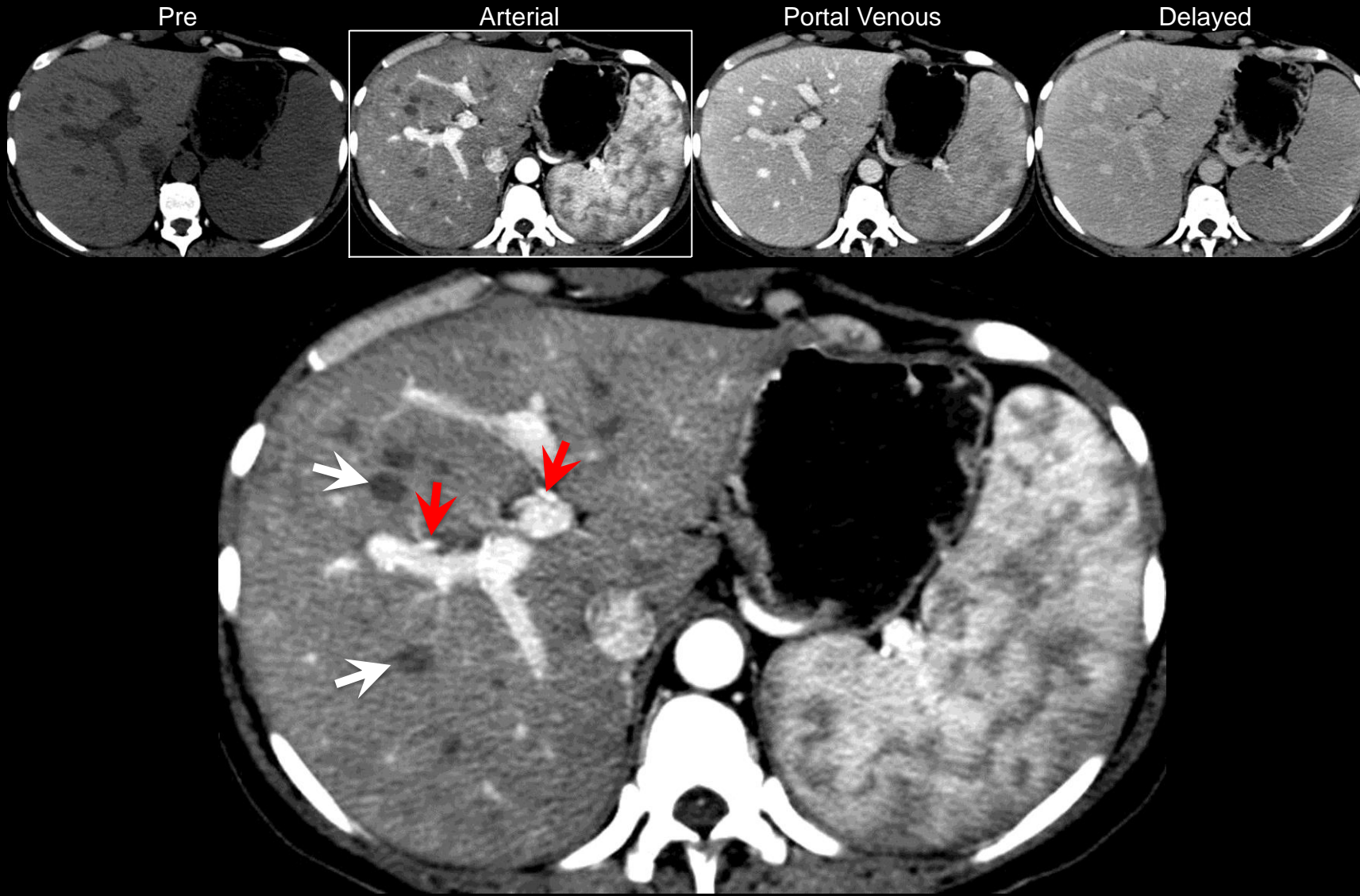
In LI-RADS, the arterial phase refers to the hepatic arterial phase unless otherwise specified. The arterial phase is a post-contrast injection time range in which images have the following characteristics:

- Hepatic artery and branches are fully enhanced.
- Hepatic veins not yet enhanced by antegrade flow.

### Comments:

- Arterial phase imaging is required for both CT and MRI.
- Hepatic arterial phase may be subclassified as early and late hepatic arterial phase.
  - Early hepatic arterial phase: portal vein is not yet enhanced.
  - Late hepatic arterial phase: portal vein is enhanced.
- Late hepatic arterial phase is **strongly** preferred for HCC diagnosis and staging, because the degree of enhancement in HCC usually is higher in the late than in the early hepatic arterial phase. Some HCCs may show hyper-enhancement only in the late hepatic arterial phase.
- At MRI, aorta may not be brightly enhanced.
  - With short bolus durations, contrast material bolus may pass beyond aorta by time of image acquisition.

Atlas: [MR](#), [Schematic](#)



**Arterial phase (CT):** Late arterial phase CT image shows strong enhancement of aorta, hepatic artery branches (red arrows), and intrahepatic portal vein branches. Hepatic veins (white arrows) are not enhanced. Note characteristic heterogeneous enhancement of spleen.



**Arterial phase:**

In LI-RADS, the arterial phase refers to the hepatic arterial phase unless otherwise specified. The arterial phase is a post-contrast injection time range in which images have the following characteristics:

- Hepatic artery and branches are fully enhanced.
- Hepatic veins not yet enhanced by antegrade flow.

**Comments:**

- Arterial phase imaging is required for both CT and MRI.
- Hepatic arterial phase may be subclassified as early and late hepatic arterial phase.
  - Early hepatic arterial phase: portal vein is not yet enhanced.
  - Late hepatic arterial phase: portal vein is enhanced.
- Late hepatic arterial phase is **strongly** preferred for HCC diagnosis and staging, because the degree of enhancement in HCC usually is higher in the late than in the early hepatic arterial phase. Some HCCs may show hyper-enhancement only in the late hepatic arterial phase.
- At MRI, aorta may not be brightly enhanced.
  - With short bolus durations, contrast material bolus may pass beyond aorta by time of image acquisition.

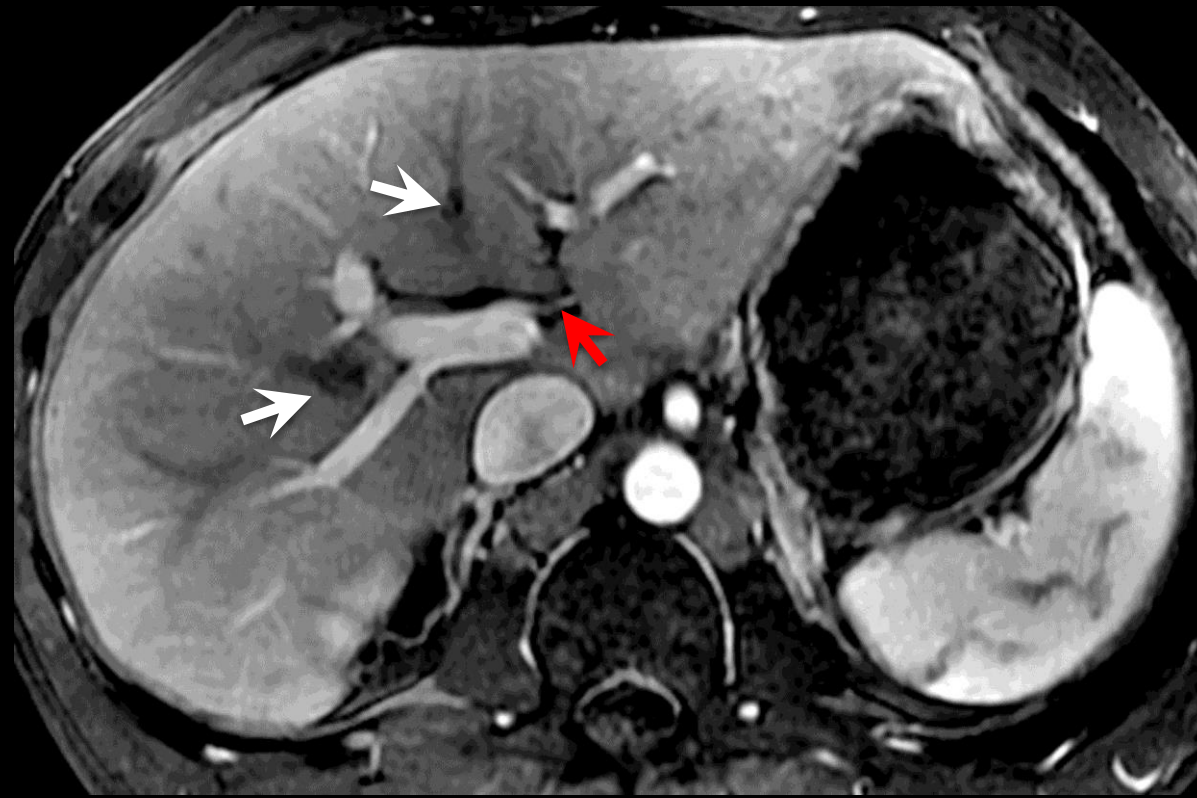
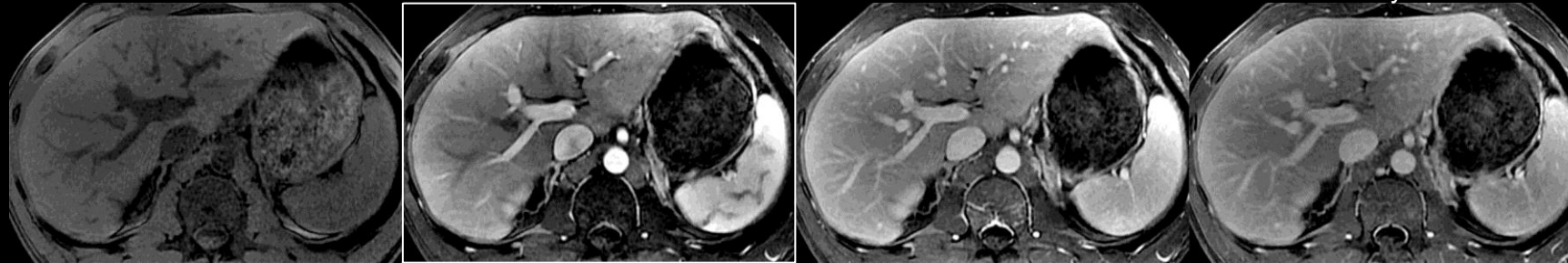Atlas: [CT](#), [Schematic](#)

Pre

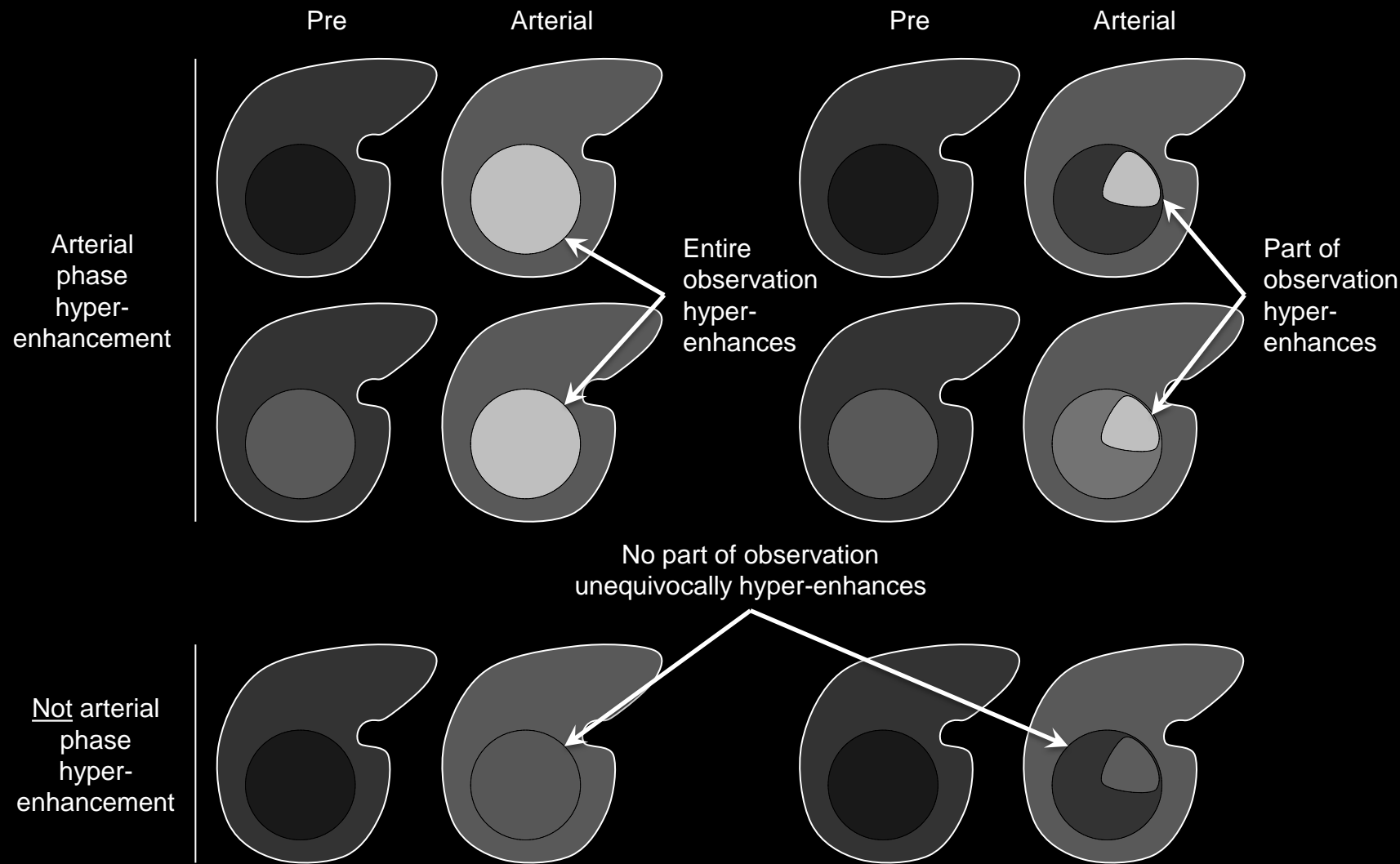
Arterial

Portal Venous

Delayed



**Arterial phase (MRI):** Late arterial phase MR image shows strong enhancement of aorta, hepatic artery branch (red arrow), and intrahepatic portal vein branches. Hepatic veins (white arrows) are not enhanced. Note characteristic heterogeneous enhancement of spleen.



## Arterial phase hyper-enhancement:

Enhancement in the [arterial phase](#) that [unequivocally](#) is greater than that of liver.

### If unsure about arterial phase hyper-enhancement:

- Characterize as hypo- or iso-enhancement.

### Comments:

- Applies to observations that, in the arterial phase, unequivocally:
  - Enhance more than liver AND
  - Are higher in attenuation or intensity than liver
 in whole or in part
- Arterial phase hyper-enhancement is a LI-RADS [major feature](#) used to categorize masses that are neither [definite benign entities](#) nor [probable benign entities](#) and that lack features of [non-HCC malignancy](#) or [tumor in vein](#). For such masses, those with arterial phase hyper-enhancement may be categorized LR3, LR4, or LR5, depending on diameter and other features. As shown in [Table](#), only masses with arterial phase hyper-enhancement can be categorized LR5.

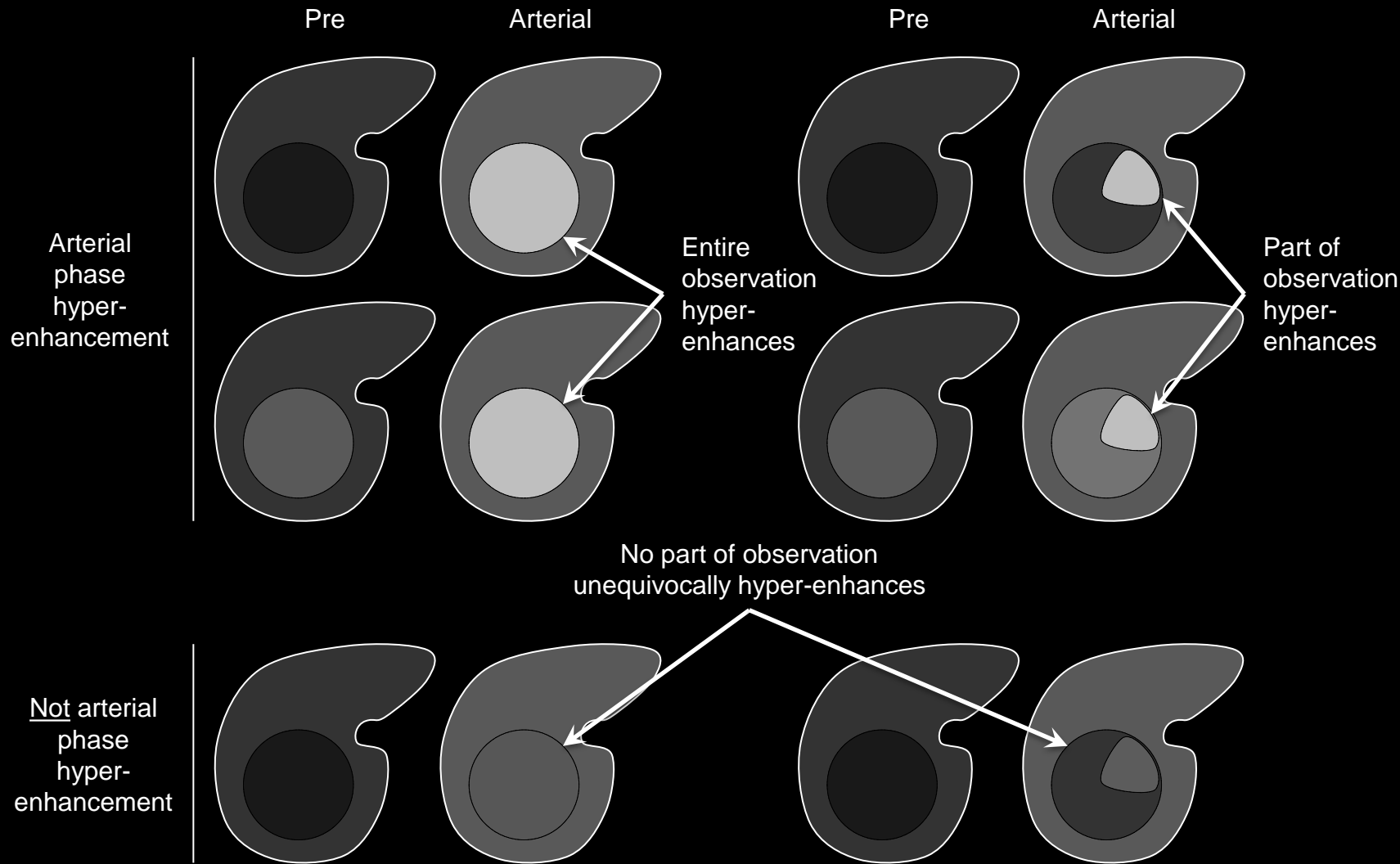
**Arterial phase hyper-enhancement:** Schematic diagrams illustrate observations with (top two rows) and without (bottom row) arterial phase hyper-enhancement. Arterial phase hyper-enhancing observations unequivocally enhance in the arterial phase more than liver, in whole (left set of images) or in part (right set of images). They may be lower (top row), similar, or higher (second row) in attenuation or intensity relative to liver pre-contrast.



## Arterial phase hyper-enhancement:

### Comments (continued):

- At MRI, for observations that are hyper-intense pre-contrast, post-processing with generation of subtraction images may be helpful for characterization of arterial phase hyper-enhancement.
- For subtractions to be valid, arterial phase and pre-contrast images need to be co-registered and acquired with the same technique.

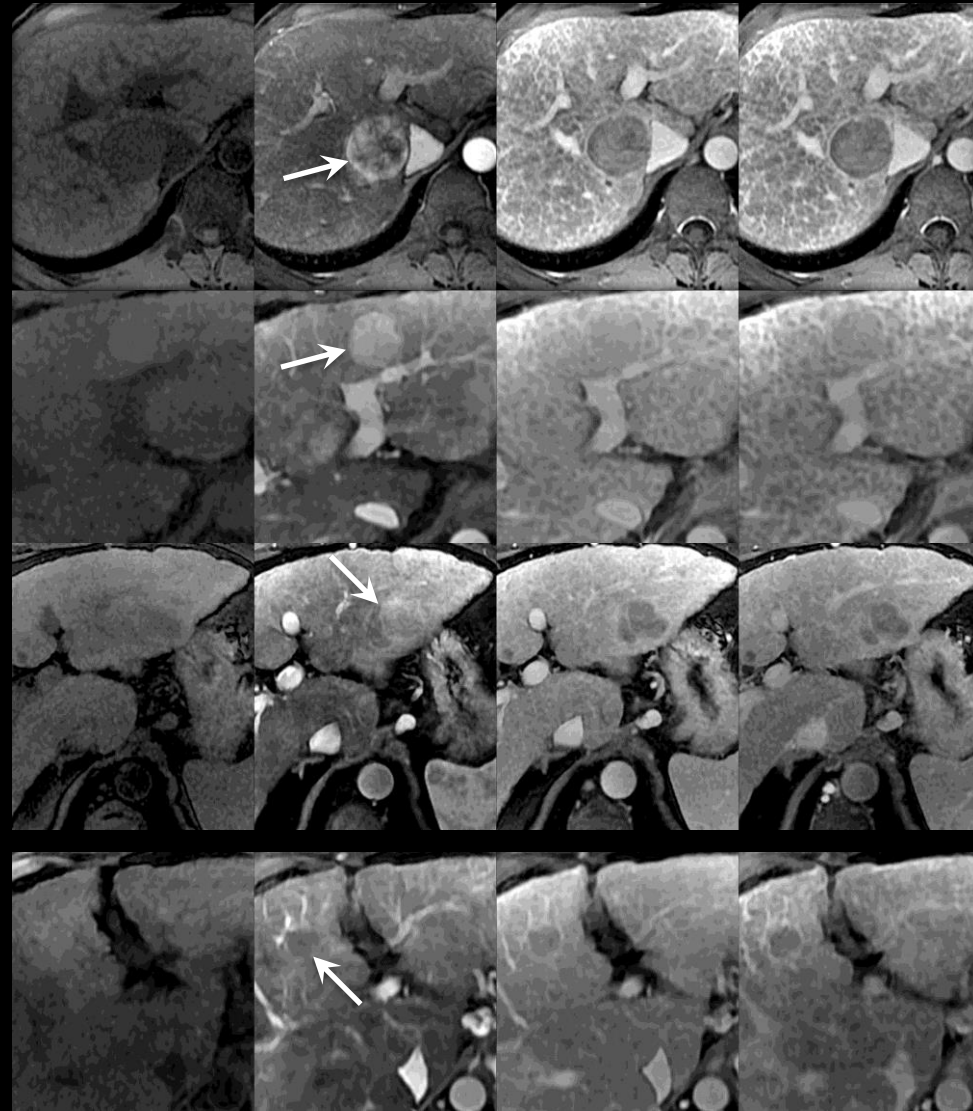


**Arterial phase hyper-enhancement:** Schematic diagrams illustrate observations with (top two rows) and without (bottom row) arterial phase hyper-enhancement. Arterial phase hyper-enhancing observations unequivocally enhance in the arterial phase more than liver, in whole (left set of images) or in part (right set of images). They may be lower (top row), similar, or higher (second row) in attenuation or intensity relative to liver pre-contrast.





Pre      Arterial      Portal Venous      Delayed



First row – mass is hypo-intense pre-contrast and hyper-intense in arterial phase.

Second row – mass is hyper-intense pre-contrast and unequivocally more hyper-intense in arterial phase.

Third row – subtle but unequivocal hyper-enhancement. Notice that part of mass becomes mildly hyper-intense in arterial phase.

Fourth row – mass is iso-intense pre-contrast and in its entirety hypo-intense in arterial phase.

## Arterial phase hyper-enhancement:

Enhancement in the [arterial phase](#) that [unequivocally](#) is greater than that of liver.

### If unsure about arterial phase hyper-enhancement:

- Characterize as hypo- or iso-enhancement.

### Comments:

- Applies to observations that, in the arterial phase, unequivocally:
    - Enhance more than liver AND
    - Are higher in attenuation or intensity than liver
- } in whole or in part
- Arterial phase hyper-enhancement is a LI-RADS [major feature](#) used to categorize masses that are neither [definite benign entities](#) nor [probable benign entities](#) and that lack features of [non-HCC malignancy](#) or [tumor in vein](#). For such masses, those with arterial phase hyper-enhancement may be categorized LR3, LR4, or LR5, depending on diameter and other features. As shown in [Table](#), only masses with arterial phase hyper-enhancement can be categorized LR5.

Arterial phase hyper-enhancement

Not arterial phase hyper-enhancement

**Arterial phase hyper-enhancement (MRI):** Figure collage shows masses with and without arterial-phase hyper-enhancement in four patients at 3T MRI.



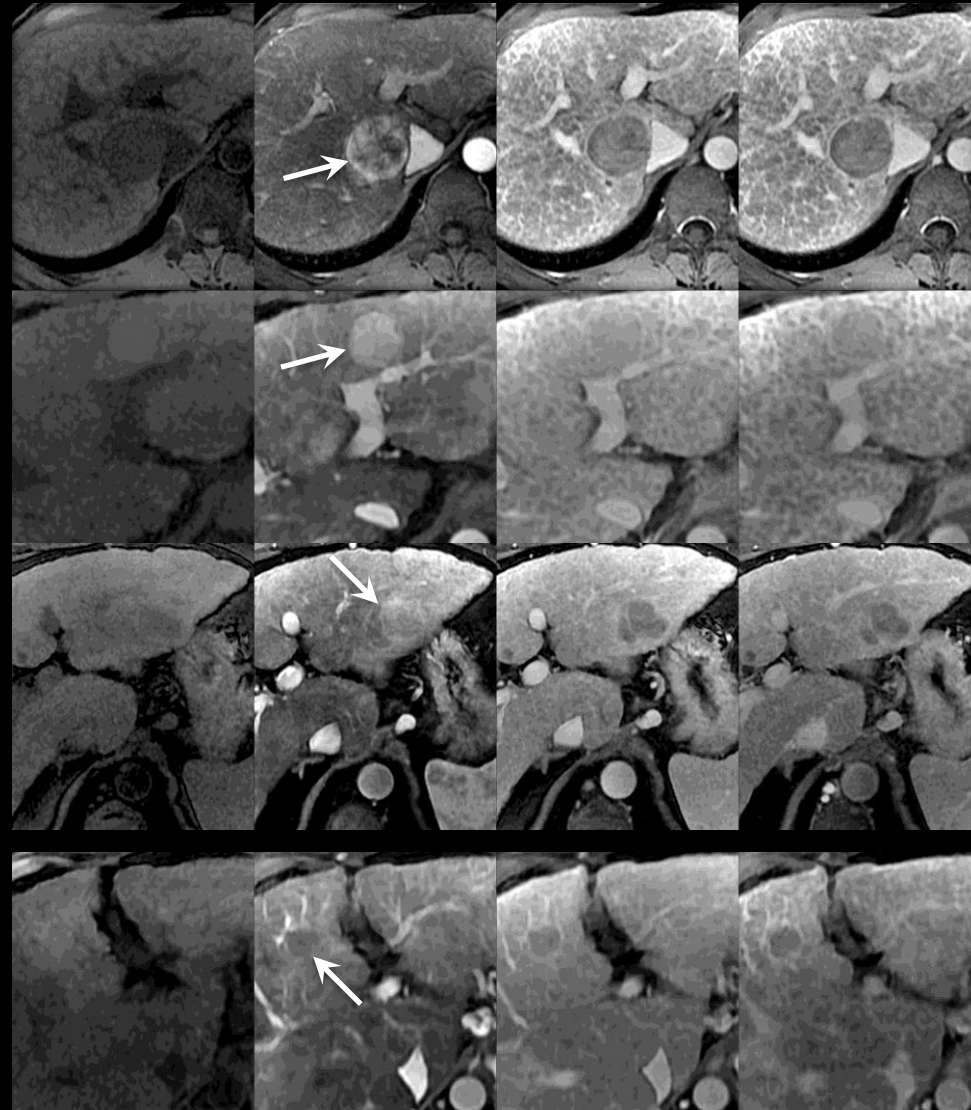


## Arterial phase hyper-enhancement:

### Comments (continued):

- At MRI, for observations that are hyper-intense pre-contrast, post-processing with generation of subtraction images may be helpful for characterization of arterial phase hyper-enhancement.
- For subtractions to be valid, arterial phase and pre-contrast images need to be co-registered and acquired with the same technique.

Pre      Arterial      Portal Venous      Delayed



First row – mass is hypo-intense pre-contrast and hyper-intense in arterial phase.

Second row – mass is hyper-intense pre-contrast and unequivocally more hyper-intense in arterial phase.

Third row – subtle but unequivocal hyper-enhancement. Notice that part of mass becomes mildly hyper-intense in arterial phase.

Fourth row – mass is iso-intense pre-contrast and in its entirety hypo-intense in arterial phase.

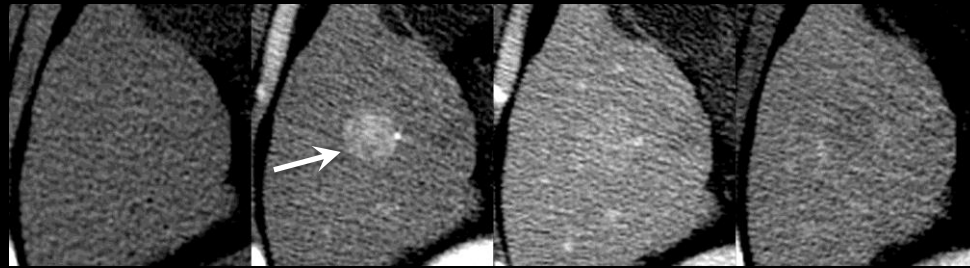
Arterial phase hyper-enhancement

Not arterial phase hyper-enhancement

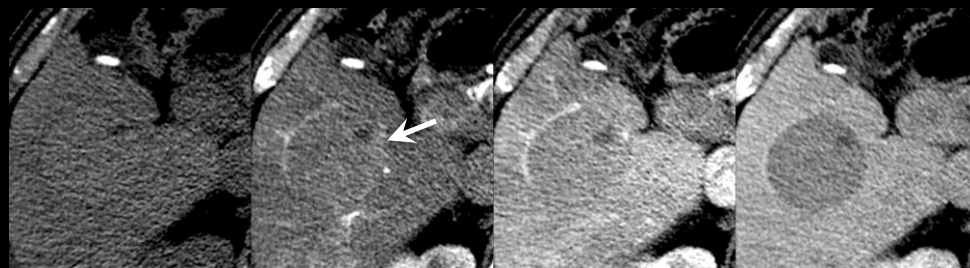
**Arterial phase hyper-enhancement (MRI):** Figure collage shows masses with and without arterial-phase hyper-enhancement in four patients at 3T MRI.



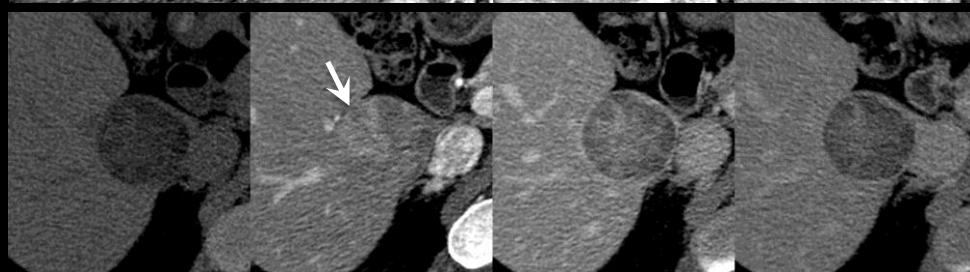
Pre Arterial Portal Venous Delayed



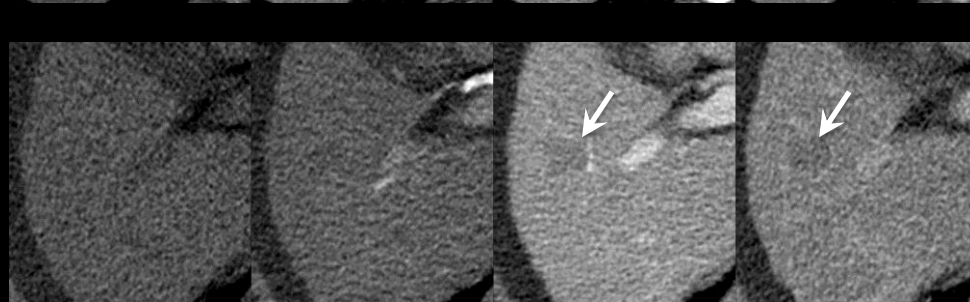
First row – Strong arterial phase hyper-enhancement of whole mass.



Second row – Subtle but unequivocal arterial phase hyper-enhancement of part of mass.



Third row – Subtle but unequivocal hyper-enhancement of part of mass.



Fourth row – Arterial phase iso-enhancement of whole mass. Mass is only seen in portal venous and delayed phases (arrow).

## Arterial phase hyper-enhancement:

Enhancement in the [arterial phase](#) that [unequivocally](#) is greater than that of liver.

### If unsure about arterial phase hyper-enhancement:

- Characterize as hypo- or iso-enhancement.

### Comments:

- Applies to observations that, in the arterial phase, unequivocally:
  - Enhance more than liver AND
  - Are higher in attenuation or intensity than liver
 in whole or in part
- Arterial phase hyper-enhancement is a LI-RADS [major feature](#) used to categorize masses that are neither [definite benign entities](#) nor [probable benign entities](#) and that lack features of [non-HCC malignancy](#) or [tumor in vein](#). For such masses, those with arterial phase hyper-enhancement may be categorized LR3, LR4, or LR5, depending on diameter and other features. As shown in [Table](#), only masses with arterial phase hyper-enhancement can be categorized LR5.

Arterial phase hyper-enhancement

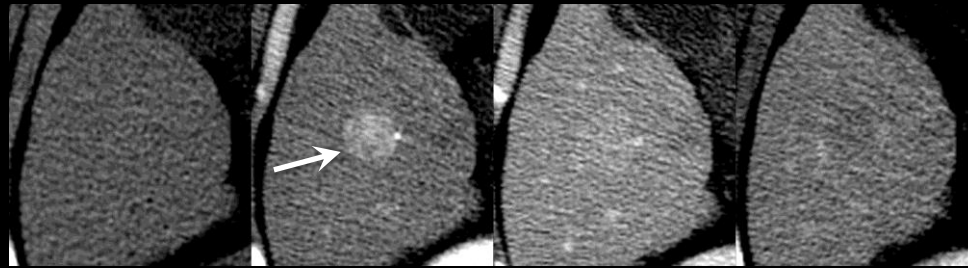
Not arterial phase hyper-enhancement

**Arterial phase hyper-enhancement (CT):** Figure collage shows masses with and without arterial-phase hyper-enhancement in four patients at CT.

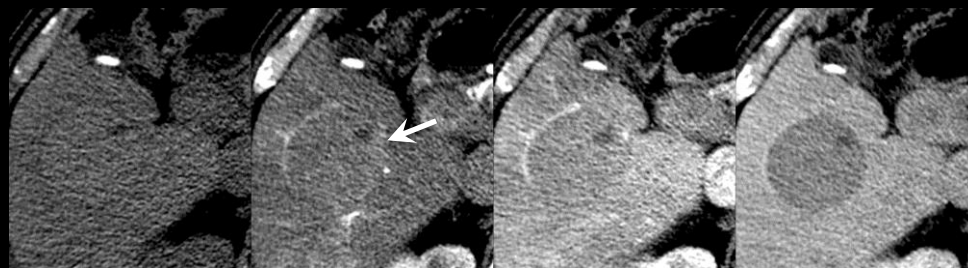




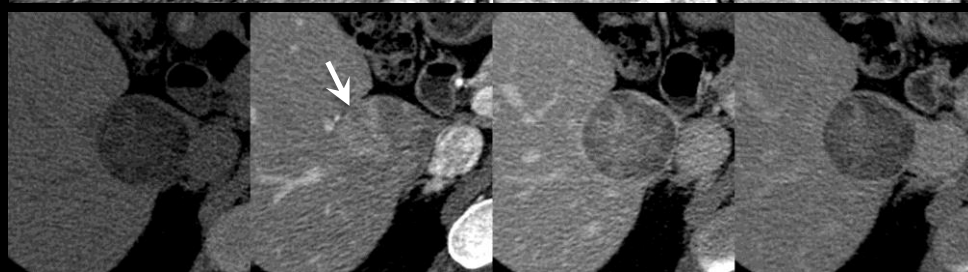
Pre Arterial Portal Venous Delayed



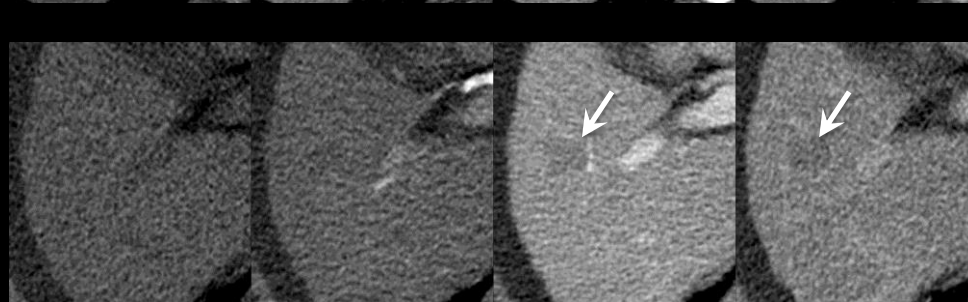
First row – Strong arterial phase hyper-enhancement of whole mass.



Second row – Subtle but unequivocal arterial phase hyper-enhancement of part of mass.



Third row – Subtle but unequivocal hyper-enhancement of part of mass.



Fourth row – Arterial phase iso-enhancement of whole mass. Mass is only seen in portal venous and delayed phases (arrow).

Arterial phase hyper-enhancement

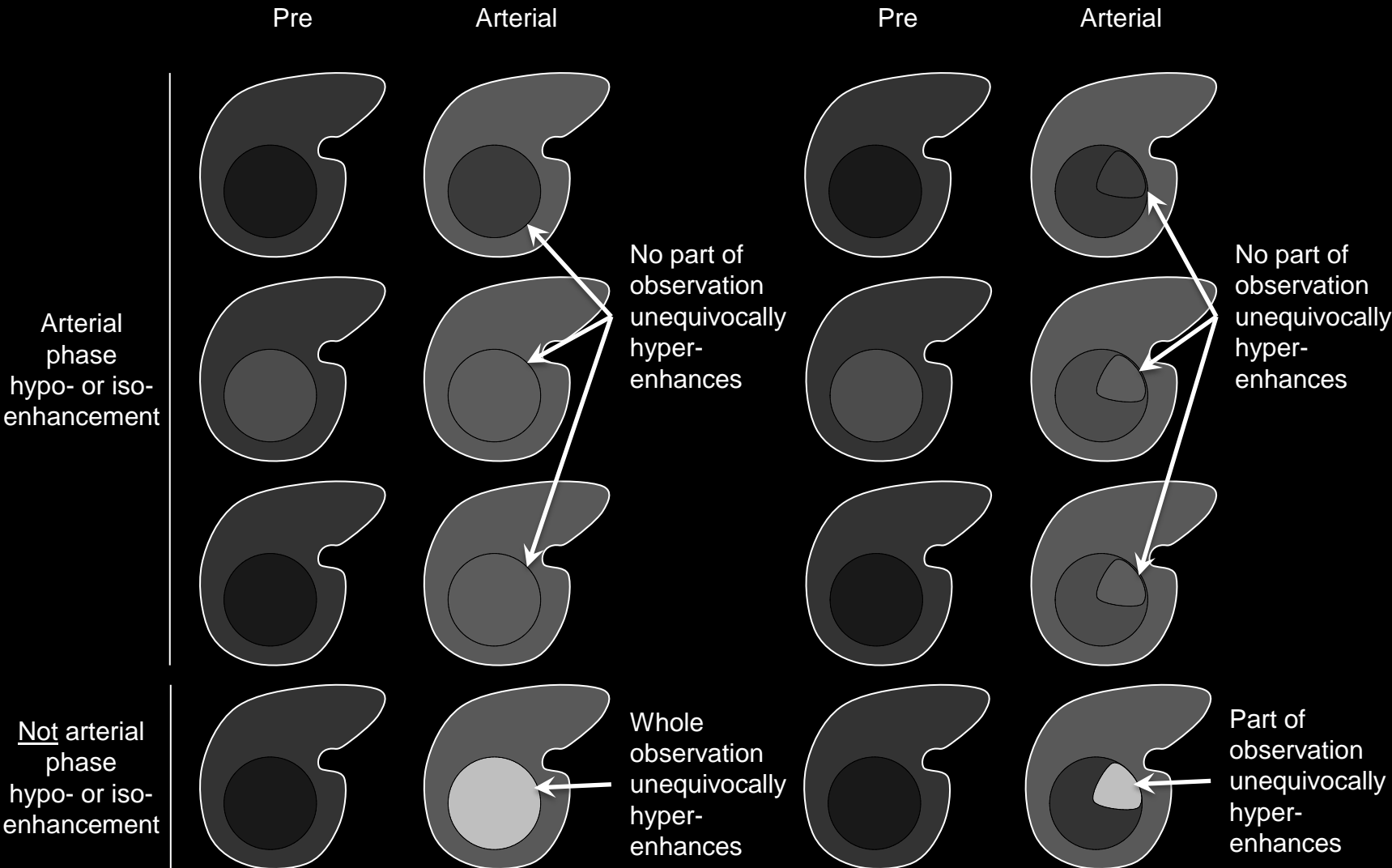
Not arterial phase hyper-enhancement

## Arterial phase hyper-enhancement:

### Comments (continued):

- At MRI, for observations that are hyper-intense pre-contrast, post-processing with generation of subtraction images may be helpful for characterization of arterial phase hyper-enhancement.
- For subtractions to be valid, arterial phase and pre-contrast images need to be co-registered and acquired with the same technique.

**Arterial phase hyper-enhancement (CT):** Figure collage shows masses with and without arterial-phase hyper-enhancement in four patients at CT.



## Arterial phase hypo- or iso-enhancement:

Enhancement in the [arterial phase](#) that is less than that or equivalent to that of liver.

### If unsure whether arterial phase enhancement is hyper-enhancement vs. hypo- or iso-enhancement:

- Characterize as arterial phase hypo- or iso-enhancement.

### Comments:

- Applies to enhancing observations that in the arterial phase do not in any part [unequivocally](#) enhance more than liver.
- Does not apply to [non-enhancing](#) observations.

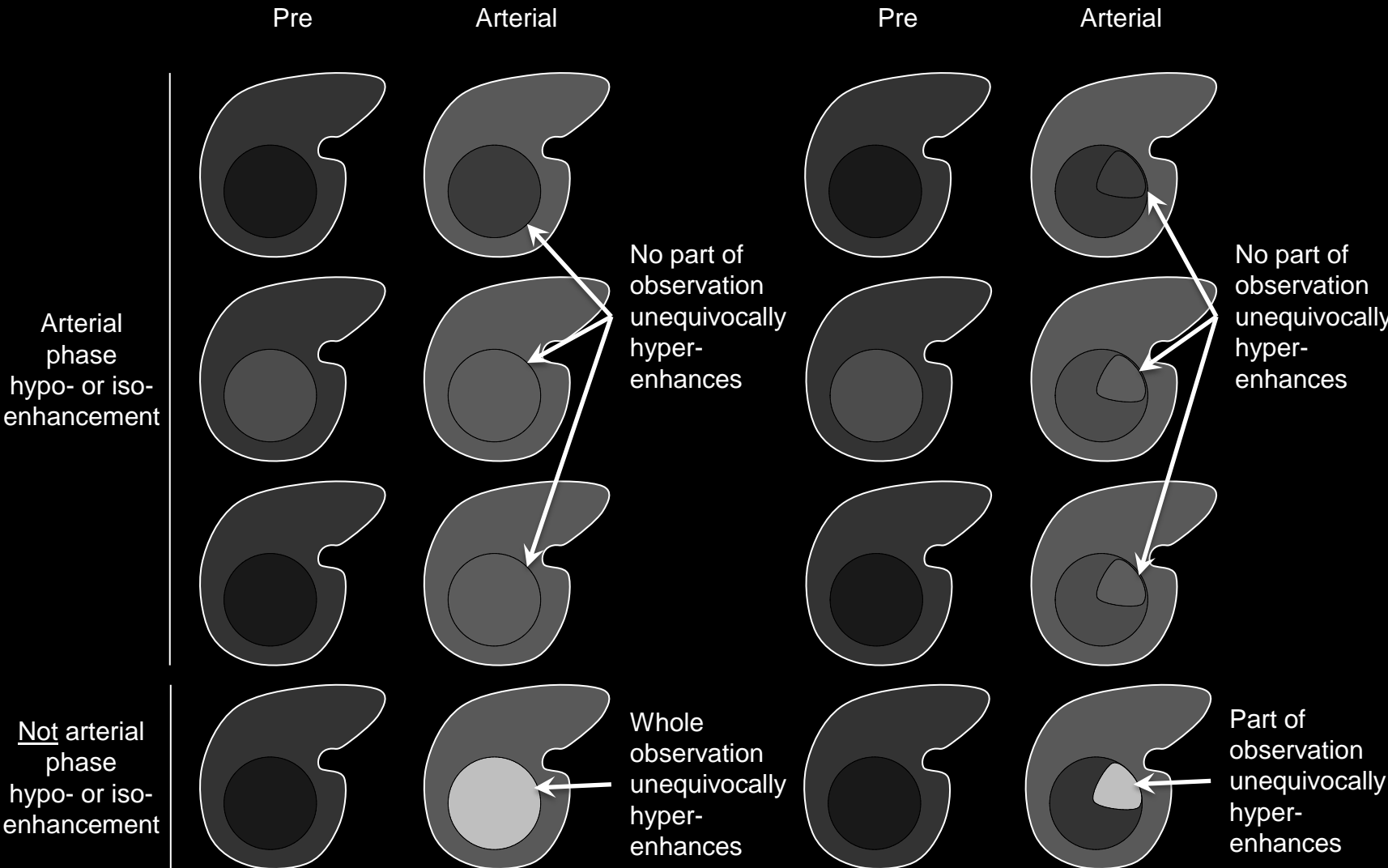
**Arterial phase hypo or iso-enhancement:** Schematic diagrams illustrate observations with arterial phase hypo- or iso-enhancement. No part of the observation unequivocally hyper-enhances in the arterial phase. Compare with schematic diagrams showing [arterial phase hyper-enhancement](#).



## Arterial phase hypo- or iso-enhancement:

### Comments (continued):

- Arterial phase hypo- or iso-enhancement is a LI-RADS [major feature](#) for categorization of masses that are neither [definite benign entities](#) nor [probable benign entities](#) and that lack features of [non-HCC malignancy](#) or [tumor in vein](#). For such masses, those with arterial phase hypo- or iso-enhancement may be categorized LR3 or LR4, depending on diameter and other features. As shown in [Table](#), masses without arterial phase hyper-enhancement cannot be categorized LR5.
- Rationale:** Masses with arterial phase hypo- or iso-enhancement cannot be diagnosed with 100% certainty as HCC based on imaging alone, regardless of other features. While such masses may represent HCC, the differential diagnosis includes non-malignant entities as well as non-HCC malignancy.
- At MRI, for observations that are hyper-intense pre-contrast, post-processing with generation of subtraction images may be helpful for characterization of arterial phase hypo- or iso-enhancement.
- For subtractions to be valid, arterial phase and pre-contrast images need to be co-registered and acquired with the same technique.



**Arterial phase hypo or iso-enhancement:** Schematic diagrams illustrate observations with arterial phase hypo- or iso-enhancement. No part of the observation unequivocally hyper-enhances in the arterial phase. Compare with schematic diagrams showing [arterial phase hyper-enhancement](#).



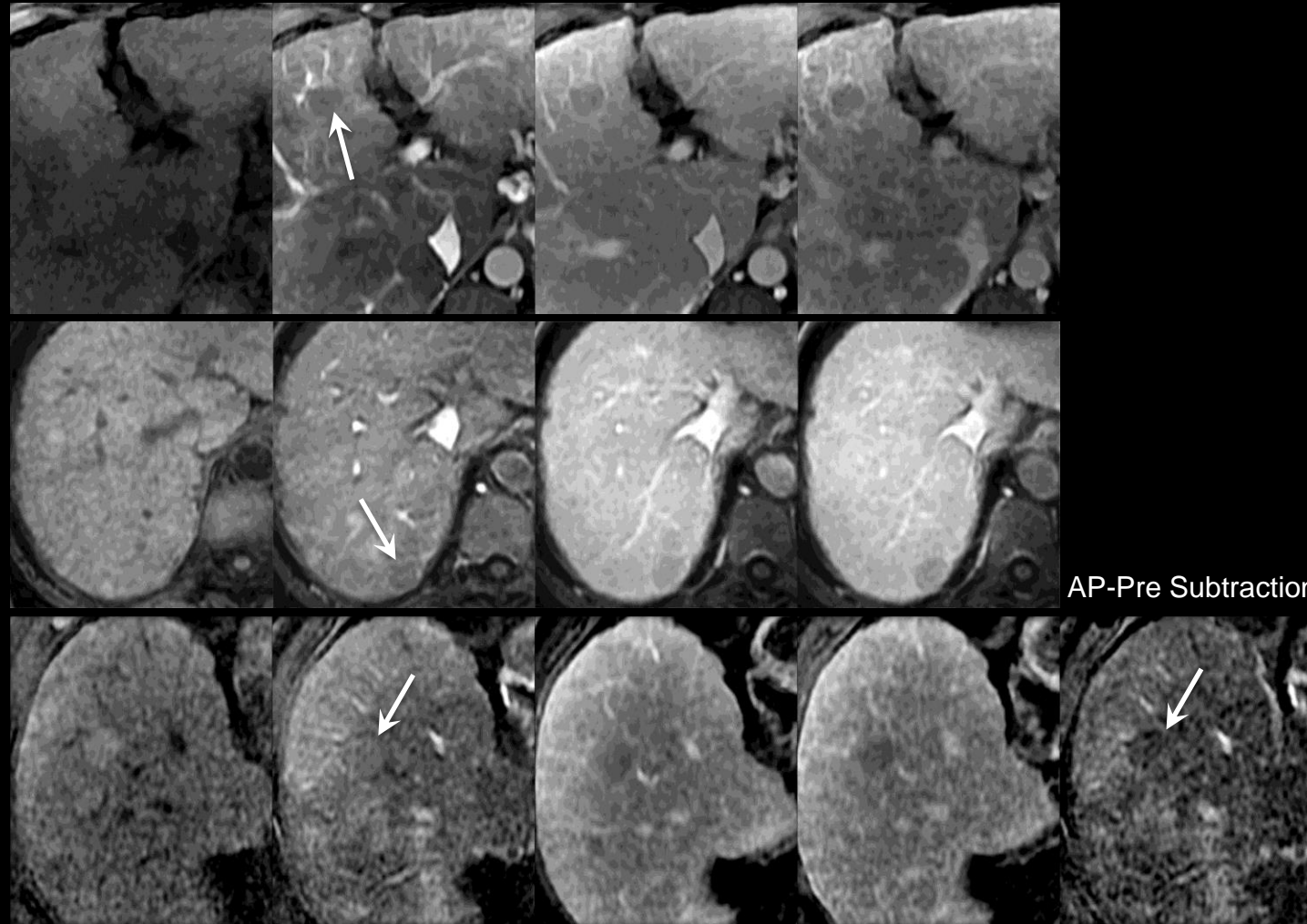


Pre

Arterial

Portal Venous

Delayed

Arterial  
phase  
hypo-  
enhancement

AP-Pre Subtraction

**Arterial phase hypo- or iso-enhancement:**

Enhancement in the [arterial phase](#) that is less than that or equivalent to that of liver.

**If unsure whether arterial phase enhancement is hyper-enhancement vs. hypo- or iso-enhancement:**

- Characterize as arterial phase hypo- or iso-enhancement

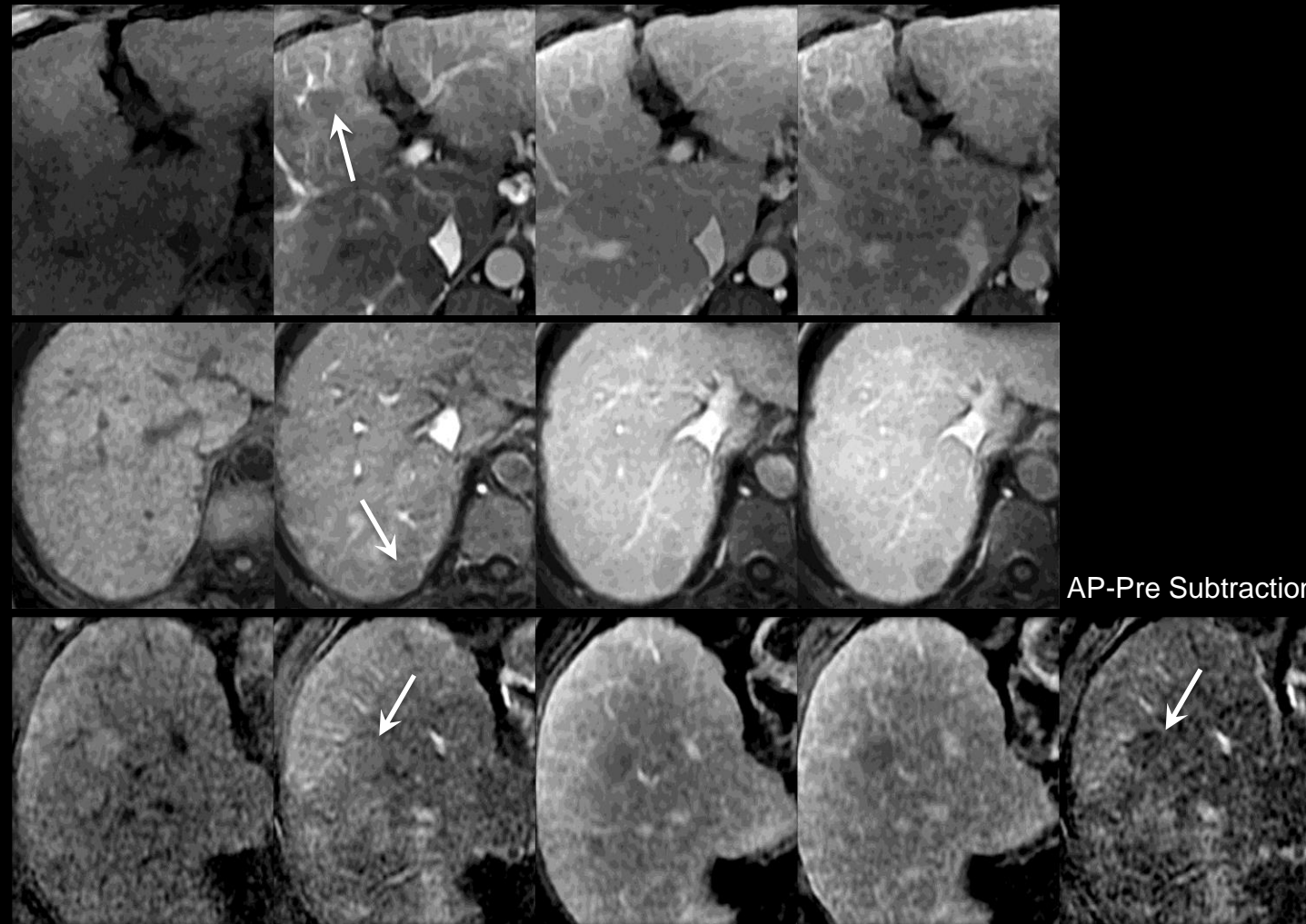
**Comments:**

- Applies to enhancing observations that in the arterial phase do not in any part [unequivocally](#) enhance more than liver.
- Does not apply to [non-enhancing](#) observations.

**Arterial phase hypo- or iso-enhancement (MRI):** Figure collage shows masses with arterial-phase hypo-enhancement in three patients at MRI. Top two rows: masses are iso-intense to liver pre-contrast and hypo-intense in the arterial phase. Bottom row: mass is hyper-intense to liver pre-contrast and iso-intense in the arterial phase; subtraction image confirms mass hypo-enhances compared to background liver in the arterial phase.



Pre      Arterial      Portal Venous      Delayed



**Arterial phase hypo- or iso-enhancement (MRI):** Figure collage shows masses with arterial-phase hypo-enhancement in three patients at MRI. Top two rows: masses are iso-intense to liver pre-contrast and hypo-intense in the arterial phase. Bottom row: mass is hyper-intense to liver pre-contrast and iso-intense in the arterial phase; subtraction image confirms mass hypo-enhances compared to background liver in the arterial phase.

**Arterial phase hypo- or iso-enhancement:**

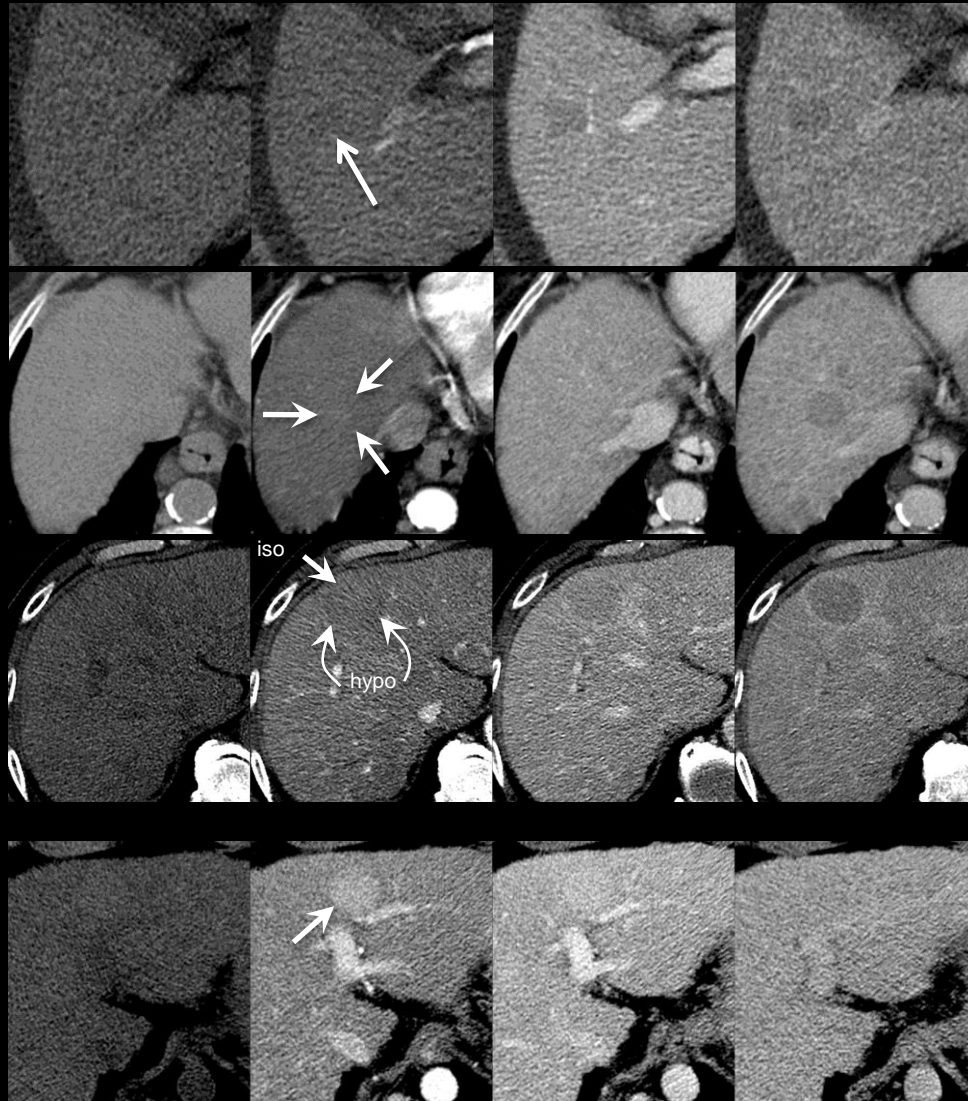
**Comments (continued):**

- Arterial phase hypo- or iso-enhancement is a LI-RADS [major feature](#) for categorization of masses that are neither [definite benign entities](#) nor [probable benign entities](#) and that lack features of [non-HCC malignancy](#) or [tumor in vein](#). For such masses, those with arterial phase hypo- or iso-enhancement may be categorized LR3 or LR4, depending on diameter and other features. As shown in [Table](#), masses without arterial phase hyper-enhancement cannot be categorized LR5.
- **Rationale:** Masses with arterial phase hypo- or iso-enhancement cannot be diagnosed with 100% certainty as HCC based on imaging alone, regardless of other features. While such masses may represent HCC, the differential diagnosis includes non-malignant entities as well as non-HCC malignancy.
- At MRI, for observations that are hyper-intense pre-contrast, post-processing with generation of subtraction images may be helpful for characterization of arterial phase hypo- or iso-enhancement.
- For subtractions to be valid, arterial phase and pre-contrast images need to be co-registered and acquired with the same technique.





Pre      Arterial      Portal Venous      Delayed



Arterial phase hypo- or iso-enhancement

Not arterial phase hypo- or iso-enhancement

First row – Arterial phase hypo-enhancement. Mass is iso-attenuating pre-contrast and slightly hypo-attenuating in arterial phase.

Second row – Arterial phase iso-enhancement. Mass is iso-attenuating pre-contrast and iso-attenuating in arterial phase.

Third row – Mixed arterial phase hypo- and iso-enhancement. Part of mass hypo-enhances (curved arrows) and part of mass iso-enhances (straight arrow) in arterial phase.

Fourth row – Arterial phase hyper-enhancement.

## Arterial phase hypo- or iso-enhancement:

Enhancement in the [arterial phase](#) that is less than that or equivalent to that of liver.

### If unsure whether arterial phase enhancement is hyper-enhancement vs. hypo- or iso-enhancement:

- Characterize as arterial phase hypo- or iso-enhancement.

### Comments:

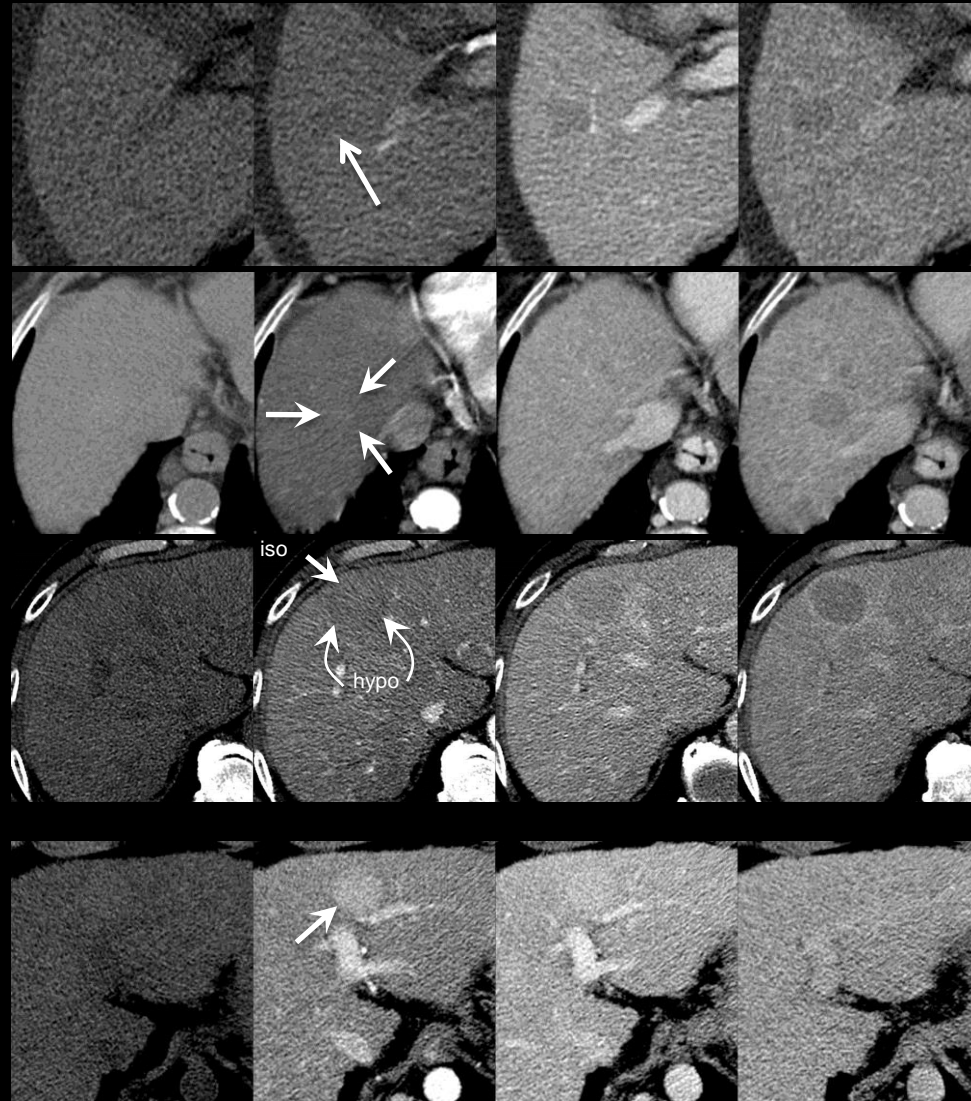
- Applies to enhancing observations that in the arterial phase do not in any part [unequivocally](#) enhance more than liver.
- Does not apply to [non-enhancing](#) observations.

**Arterial phase hyper-enhancement (CT):** Figure collage shows masses with and without arterial phase hypo- or iso-enhancement in four patients at CT.





Pre      Arterial      Portal Venous      Delayed



Arterial phase hypo- or iso-enhancement

Not arterial phase hypo- or iso-enhancement

First row – Arterial phase hypo-enhancement. Mass is iso-attenuating pre-contrast and slightly hypo-attenuating in arterial phase.

Second row – Arterial phase iso-enhancement. Mass is iso-attenuating pre-contrast and iso-attenuating in arterial phase.

Third row – Mixed arterial phase hypo- and iso-enhancement. Part of mass hypo-enhances (curved arrows) and part of mass iso-enhances (straight arrow) in arterial phase.

Fourth row – Arterial phase hyper-enhancement.

## Arterial phase hypo- or iso-enhancement:

### Comments (continued):

- Arterial phase hypo- or iso-enhancement is a LI-RADS [major feature](#) for categorization of masses that are neither [definite benign entities](#) nor [probable benign entities](#) and that lack features of [non-HCC malignancy](#) or [tumor in vein](#). For such masses, those with arterial phase hypo- or iso-enhancement may be categorized LR3 or LR4, depending on diameter and other features. As shown in [Table](#), masses without arterial phase hyper-enhancement cannot be categorized LR5.
- **Rationale:** Masses with arterial phase hypo- or iso-enhancement cannot be diagnosed with 100% certainty as HCC based on imaging alone, regardless of other features. While such masses may represent HCC, the differential diagnosis includes non-malignant entities as well as non-HCC malignancy.
- At MRI, for observations that are hyper-intense pre-contrast, post-processing with generation of subtraction images may be helpful for characterization of arterial phase hypo- or iso-enhancement.
- For subtractions to be valid, arterial phase and pre-contrast images need to be co-registered and acquired with the same technique.

**Arterial phase hyper-enhancement (CT):** Figure collage shows masses with and without arterial phase hypo- or iso-enhancement in four patients at CT.

**Atypical:**

Appearance that differs in one or more features from the most common appearance.

**Comments:**

- If possible, describe the manner in which the appearance differs. For example, “atypical, slow-filling hemangioma” or “atypical hemangioma with continuous peripheral enhancement”.

**Atlas:** CT, MR

**Benign entity:**

Condition or entity that is not cancerous. The condition or entity does not spread to other parts of the body (metastasize) and, except for infections, does not invade into and destroy adjacent tissues.

**Comments:**

- Benign entities that frequently are encountered in patients with cirrhosis or other risk factors for HCC include:
  - [Cysts](#)
  - [Hemangiomas](#)
  - [Vascular anomalies](#)
  - [Perfusion alterations](#)
  - [Hepatic fat deposition](#) or [sparing](#)
  - [Hypertrophic pseudomasses](#)
  - [Confluent fibrosis](#)
  - [Focal scars](#)
- In addition, the cirrhotic liver is characterized by the presence of innumerable [cirrhosis-associated nodules](#). While these nodules represent a histological spectrum, in most patients the vast majority of these nodules are cirrhotic nodules (CNs). CNs have benign histological features without cellular atypia or other evidence of dysplasia/malignancy.
- Benign entities usually are categorized [LR1](#) (definitely benign) or [LR2](#) (probably benign), depending on radiologist's level of certainty. Benign entities with [atypical](#) or nonspecific features may be categorized [LR3](#) or higher.

**Atlas:** CT, MR

**Blood products:**

Presence of intra-lesional or peri-lesional hemorrhage in absence of biopsy, trauma or intervention.


**Comments:**

- Blood products in or around a lesion in the absence of biopsy, trauma, or intervention is an [ancillary feature](#) favoring HCC.
- Radiologists at their discretion may apply this ancillary feature to upgrade category (up to LR4).
- MRI is more sensitive and specific for detection of blood products than CT.
- At MRI, blood products usually manifest as areas of heterogeneous, predominantly high signal intensity on T1w images and heterogeneous, predominantly low signal intensity on T2w images. Due to T2\* shortening, there may be signal loss on the second echo of a dual-echo gradient-echo sequence.
- At CT, blood products usually manifest as areas of heterogeneous hyper-attenuation.

**Atlas:** CT, MR



Pre      Arterial      Portal Venous      Delayed



Observation with diffuse arterial phase hyper-enhancement and “capsule”.

Observation with arterial phase iso-enhancement and “capsule”.

Observation with diffuse arterial phase hyper-enhancement, superimposed arterial phase rim enhancement, and “capsule”.

Observation with rim enhancement only in the arterial phase. Do not characterize as “capsule”.

## Capsule appearance

Peripheral rim of smooth hyper-enhancement in the [portal venous phase](#) or [delayed phase](#) that [unequivocally](#) is thicker or more conspicuous than the rims surrounding background nodules.

### If unsure about capsule appearance:

- Do not characterize as capsule appearance.

### Comments:

- Applies to observations that, in the [portal venous phase](#) or [delayed phase](#), unequivocally have a peripheral rim of smooth hyper-enhancement that is thicker or more conspicuous than the rims surrounding background nodules.
- Capsule appearance is a LI-RADS [major feature](#) for categorization of masses that are neither [definite benign entities](#) nor [probable benign entities](#) and that lack features of [non-HCC malignancy](#) or [tumor in vein](#). For such masses, those with capsule appearance may be categorized LR3, LR4, or LR5, depending on the observation’s arterial phase enhancement, diameter, and other features. As shown in [Table](#), masses with capsule appearance but without arterial phase hyper-enhancement cannot be categorized LR5.

Capsule appearance

Not capsule appearance

**Capsule appearance:** Schematic diagrams illustrate observations with (top three rows) and without (bottom row) “capsules”. Observations with “capsules” show unequivocal peripheral rim enhancement in portal venous phase or delayed phase. The degree of enhancement usually is greater in the delayed phase than in the portal venous phase. Such observations may have arterial phase hyper-enhancement (top and third row) or arterial phase iso- or hypo-enhancement (second row). A rim of arterial phase hyper-enhancement also may be present. However, if rim enhancement is present only in the arterial phase (bottom row), do not characterize as “capsule”.



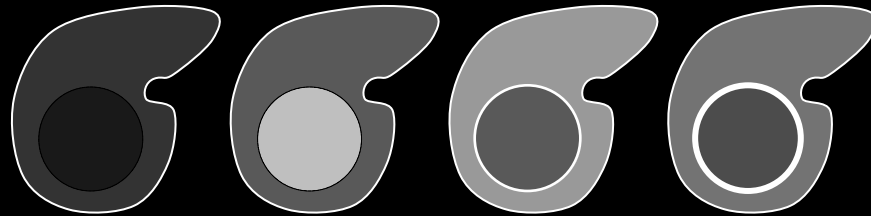


## Capsule appearance

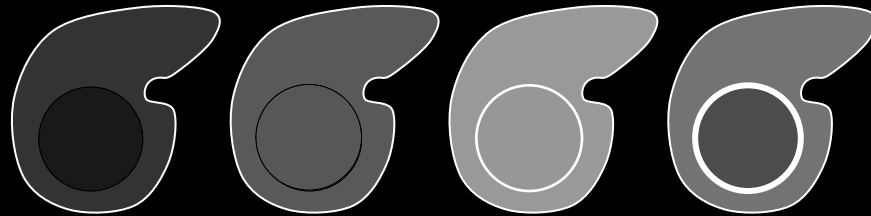
## Comments (continued):

- The degree of enhancement of the “capsule” usually increases from early to later phases.
- The delayed phase may be superior to the portal venous phase for depicting this feature.
- Multiplanar images also may help demonstrate capsule appearance.
- The rim’s degree of arterial phase enhancement is not relevant for characterization of this feature.
- The rim’s attenuation/intensity on non-vascular phase images is not relevant for characterization of this feature.
  - **Rationale:** To maintain congruency with OPTN definition of “capsule”, which is based only on vascular phase features.
- The terms capsule appearance and “capsule” (with quotation marks) are preferred over the term capsule.
- **Rationale:** the rim of enhancement does not always represent a [true tumor capsule](#) and may instead represent a [pseudocapsule](#).
- The distinction between true tumor capsule and pseudocapsule can only be made at pathology.


Pre Arterial Portal Venous Delayed



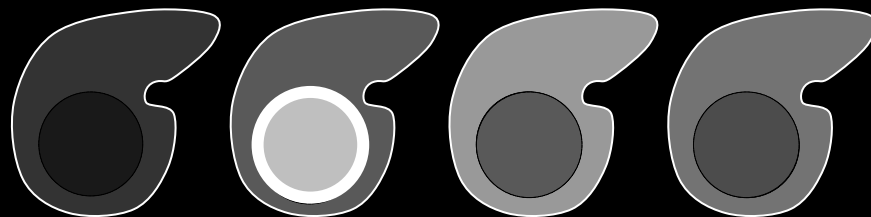
Observation with diffuse arterial phase hyper-enhancement and “capsule”.



Observation with arterial phase iso-enhancement and “capsule”.



Observation with diffuse arterial phase hyper-enhancement, superimposed arterial phase rim enhancement, and “capsule”.



Observation with rim enhancement only in the arterial phase. Do not characterize as “capsule”.

Capsule appearance

Not capsule appearance

**Capsule appearance:** Schematic diagrams illustrate observations with (top three rows) and without (bottom row) “capsules”. Observations with “capsules” show unequivocal peripheral rim enhancement in portal venous phase or delayed phase. The degree of enhancement usually is greater in the delayed phase than in the portal venous phase. Such observations may have arterial phase hyper-enhancement (top and third row) or arterial phase iso- or hypo-enhancement (second row). A rim of arterial phase hyper-enhancement also may be present. However, if rim enhancement is present only in the arterial phase (bottom row), do not characterize as “capsule”.




## Capsule appearance


### Comments (continued):

- In at-risk patients, capsule appearance has high positive predictive value for HCC, regardless of whether rim of enhancement represents [true tumor capsule](#) or [pseudocapsule](#).
- In observations with diffuse arterial phase hyper-enhancement, “capsule” and [corona enhancement](#) may overlap in imaging appearance. If rim enhancement increases in portal venous phase or delayed phase, characterize as “capsule”. If rim enhancement occurs in arterial phase and then [fades](#), characterize as corona enhancement.
- [Cirrhosis-associated nodules](#) are surrounded by mixed fibrous tissue. The mixed fibrous tissue around these nodules may enhance at imaging and be mistaken for a “capsule”. Characterize as “capsule” only if rim enhancement is unequivocally thicker or more conspicuous than the mixed fibrous tissue surrounding background nodules ([click here for MRI example](#)).


Pre      Arterial      Portal Venous      Delayed



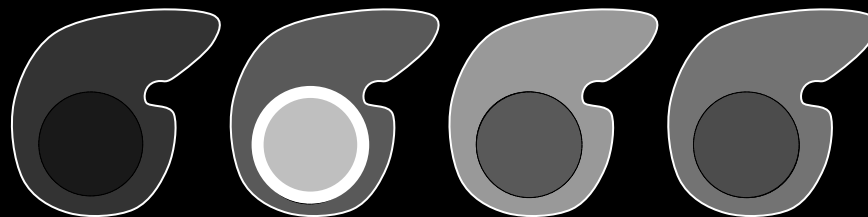
Observation with diffuse arterial phase hyper-enhancement and “capsule”.



Observation with arterial phase iso-enhancement and “capsule”.



Observation with diffuse arterial phase hyper-enhancement, superimposed arterial phase rim enhancement, and “capsule”.



Observation with rim enhancement only in the arterial phase. Do not characterize as “capsule”.

Capsule appearance

Not capsule appearance

**Capsule appearance:** Schematic diagrams illustrate observations with (top three rows) and without (bottom row) “capsules”. Observations with “capsules” show unequivocal peripheral rim enhancement in portal venous phase or delayed phase. The degree of enhancement usually is greater in the delayed phase than in the portal venous phase. Such observations may have arterial phase hyper-enhancement (top and third row) or arterial phase iso- or hypo-enhancement (second row). A rim of arterial phase hyper-enhancement also may be present. However, if rim enhancement is present only in the arterial phase (bottom row), do not characterize as “capsule”.

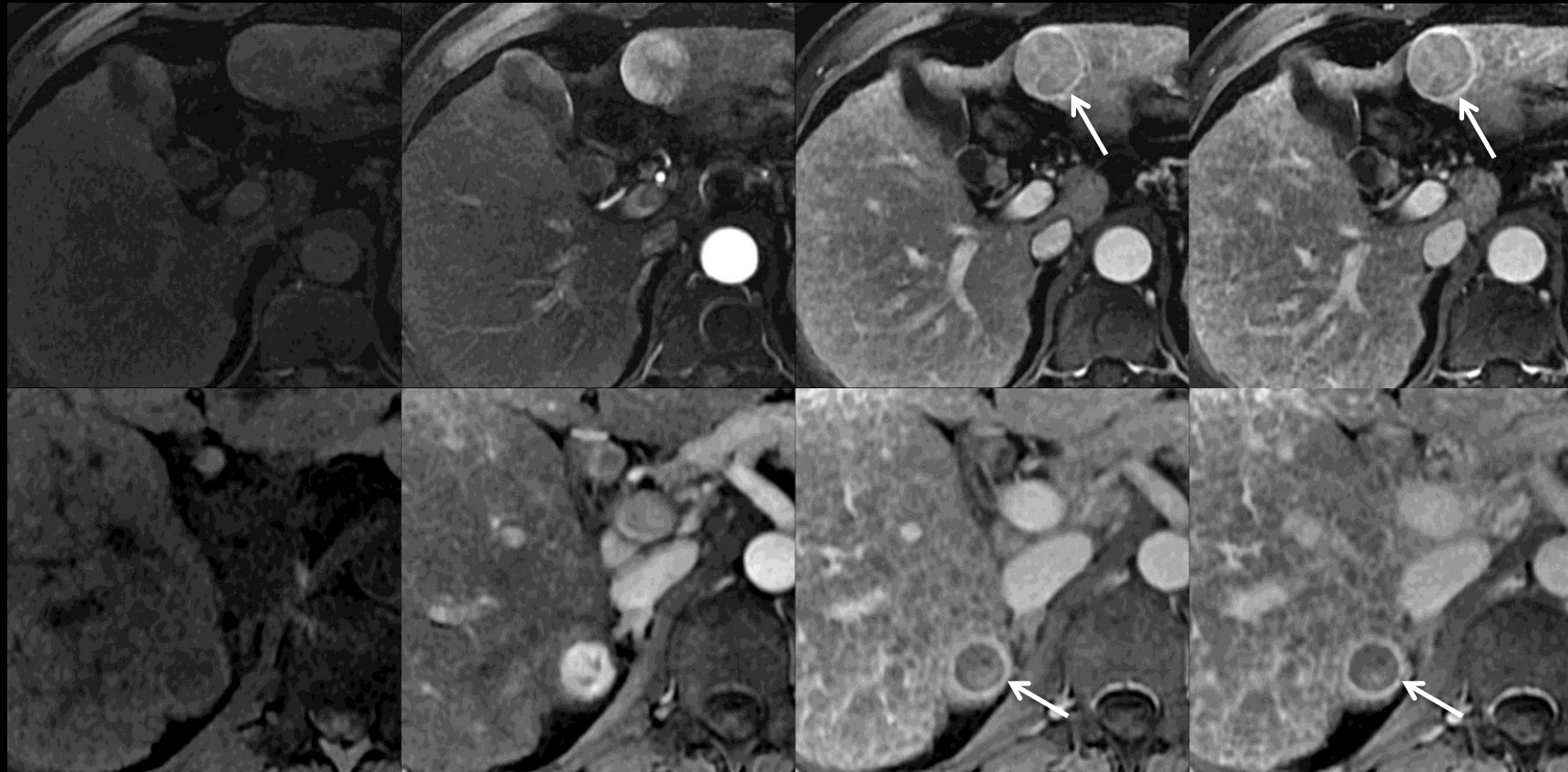


Pre

Arterial

Portal Venous

Delayed



## Capsule appearance

Peripheral rim of smooth hyper-enhancement in the [portal venous phase](#) or [delayed phase](#) that [unequivocally](#) is thicker or more conspicuous than the rims surrounding background nodules.

### If unsure about capsule appearance:

- Do not characterize as capsule appearance.

### Comments:

- Applies to observations that, in the [portal venous phase](#) or [delayed phase](#), unequivocally have a peripheral rim of smooth hyper-enhancement that is thicker or more conspicuous than the rims surrounding background nodules.
- Capsule appearance is a LI-RADS [major feature](#) for categorization of masses that are neither [definite benign entities](#) nor [probable benign entities](#) and that lack features of [non-HCC malignancy](#) or [tumor in vein](#). For such masses, those with capsule appearance may be categorized LR3, LR4, or LR5, depending on the observation's arterial phase enhancement, diameter, and other features. As shown in [Table](#), masses with capsule appearance but without arterial phase hyper-enhancement cannot be categorized LR5.

**Capsule appearance (MRI):** Figure collage shows masses with capsule appearance in two patients at 3T MRI. Masses show peripheral rim enhancement in portal venous and delayed phases (capsule appearance). The rim of enhancement unequivocally is thicker and more conspicuous than the mixed fibrous tissue (fibrotic septa) surrounding background [cirrhosis-associated nodules](#). Both masses show diffuse arterial phase hyper-enhancement.



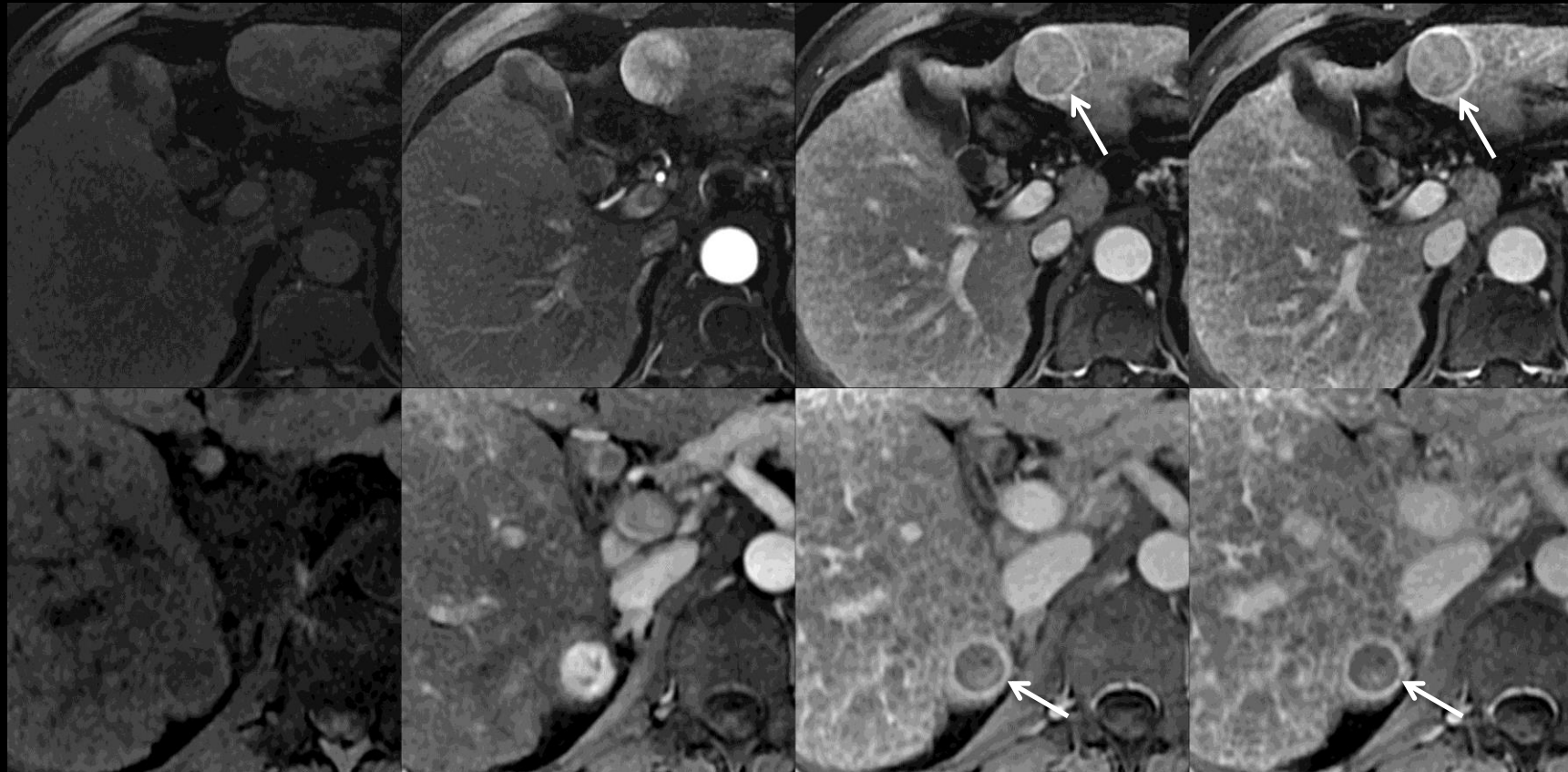


Pre

Arterial

Portal Venous

Delayed



**Capsule appearance (MRI):** Figure collage shows masses with capsule appearance in two patients at 3T MRI. Masses show peripheral rim enhancement in portal venous and delayed phases (capsule appearance). The rim of enhancement unequivocally is thicker and more conspicuous than the mixed fibrous tissue (fibrotic septa) surrounding background [cirrhosis-associated nodules](#). Both masses show diffuse arterial phase hyper-enhancement.

## Capsule appearance

### Comments (continued):

- The degree of enhancement of the “capsule” usually increases from early to later phases.
- The delayed phase may be superior to the portal venous phase for depicting this feature.
- Multiplanar images also may help demonstrate capsule appearance.
- The rim’s degree of arterial phase enhancement is not relevant for characterization of this feature.
- The rim’s attenuation/intensity on non-vascular phase images is not relevant for characterization of this feature.
  - **Rationale:** To maintain congruency with OPTN definition of “capsule”, which is based only on vascular phase features.
- The terms capsule appearance and “capsule” (with quotation marks) are preferred over the term capsule.
- **Rationale:** the rim of enhancement does not always represent a [true tumor capsule](#) and may instead represent a [pseudocapsule](#).
- The distinction between true tumor capsule and pseudocapsule can only be made at pathology.

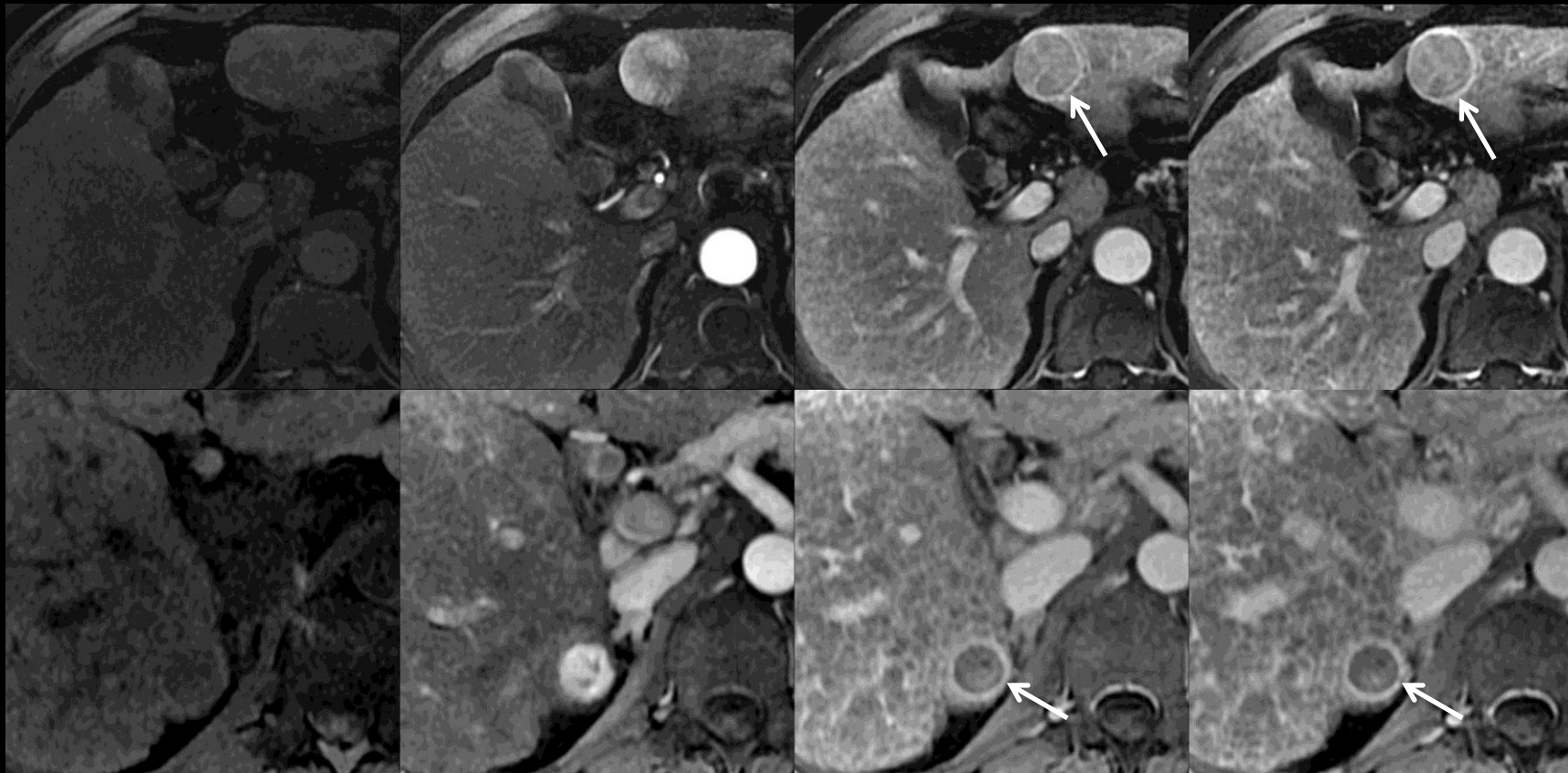


Pre

Arterial

Portal Venous

Delayed



## Capsule appearance

### Comments (continued):

- In at-risk patients, capsule appearance has high positive predictive value for HCC, regardless of whether rim of enhancement represents [true tumor capsule](#) or [pseudocapsule](#).
- In observations with diffuse arterial phase hyper-enhancement, “capsule” and [corona enhancement](#) may overlap in imaging appearance. If rim enhancement increases in portal venous phase or delayed phase, characterize as “capsule”. If rim enhancement occurs in arterial phase and then [fades](#), characterize as corona enhancement.
- [Cirrhosis-associated nodules](#) are surrounded by mixed fibrous tissue (fibrotic septa). The mixed fibrous tissue around these nodules may enhance at imaging and be mistaken for a “capsule”. Characterize as “capsule” only if rim enhancement is unequivocally thicker or more conspicuous than the mixed fibrous tissue surrounding background nodules.

**Capsule appearance (MRI):** Figure collage shows masses with capsule appearance in two patients at 3T MRI. Masses show peripheral rim enhancement in portal venous and delayed phases (capsule appearance). The rim of enhancement unequivocally is thicker and more conspicuous than the mixed fibrous tissue (fibrotic septa) surrounding background [cirrhosis-associated nodules](#). Both masses show diffuse arterial phase hyper-enhancement.



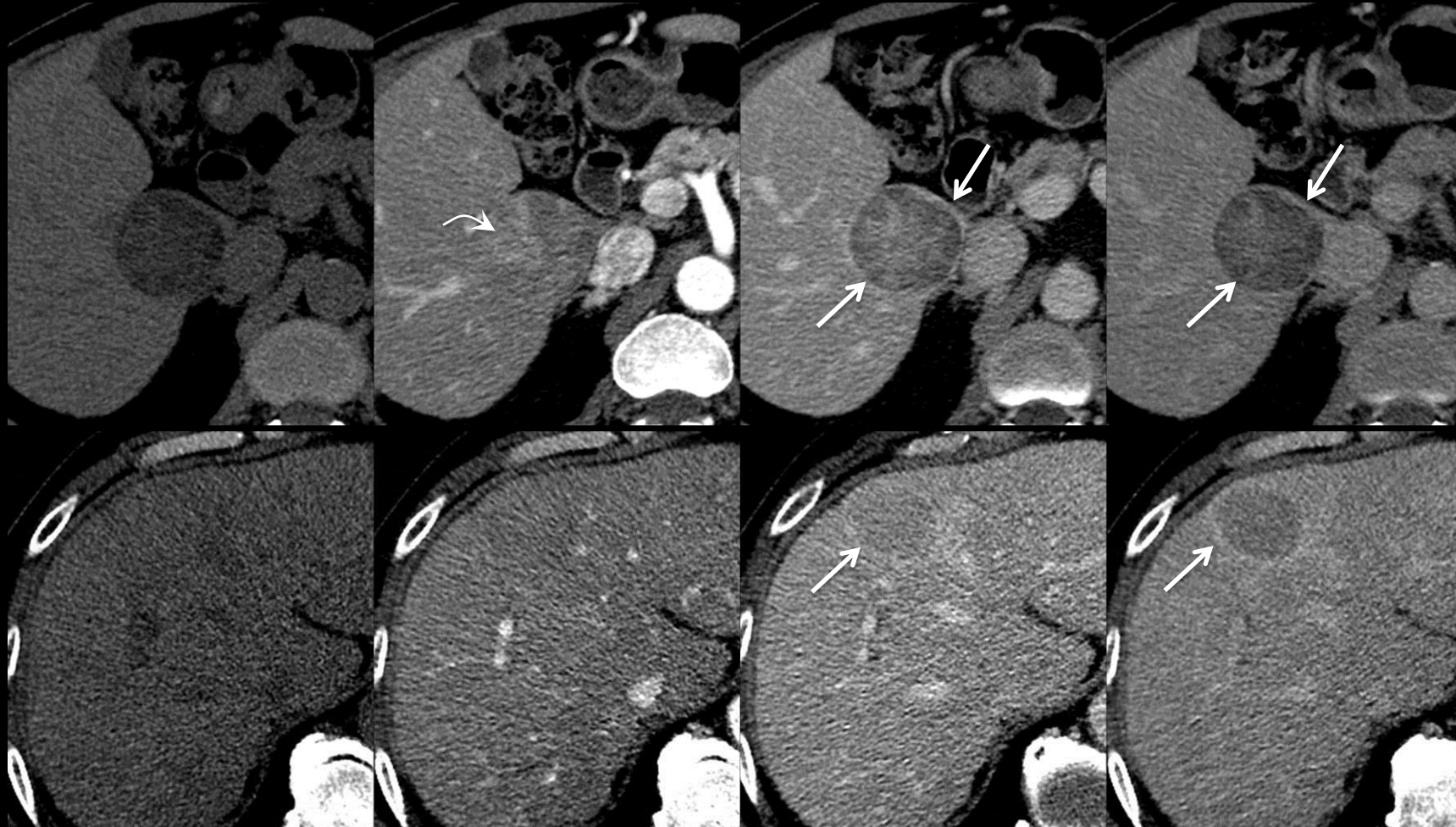


Pre

Arterial

Portal Venous

Delayed



## Capsule appearance

Peripheral rim of smooth hyper-enhancement in the [portal venous phase](#) or [delayed phase](#) that [unequivocally](#) is thicker or more conspicuous than the rims surrounding background nodules.

### If unsure about capsule appearance:

- Do not characterize as capsule appearance.

### Comments:

- Applies to observations that, in the [portal venous phase](#) or [delayed phase](#), unequivocally have a peripheral rim of smooth hyper-enhancement that is thicker or more conspicuous than the rims surrounding background nodules.
- Capsule appearance is a LI-RADS [major feature](#) for categorization of masses that are neither [definite benign entities](#) nor [probable benign entities](#) and that lack features of [non-HCC malignancy](#) or [tumor in vein](#). For such masses, those with capsule appearance may be categorized LR3, LR4, or LR5, depending on the observation's arterial phase enhancement, diameter, and other features. As shown in [Table](#), masses with capsule appearance but without arterial phase hyper-enhancement cannot be categorized LR5.

**Capsule appearance (CT):** Figure shows masses with capsule appearance at CT. Masses show peripheral rim enhancement in portal venous and delayed phases (capsule appearance). One mass (top row) also shows arterial phase hyper-enhancement (curved arrow).



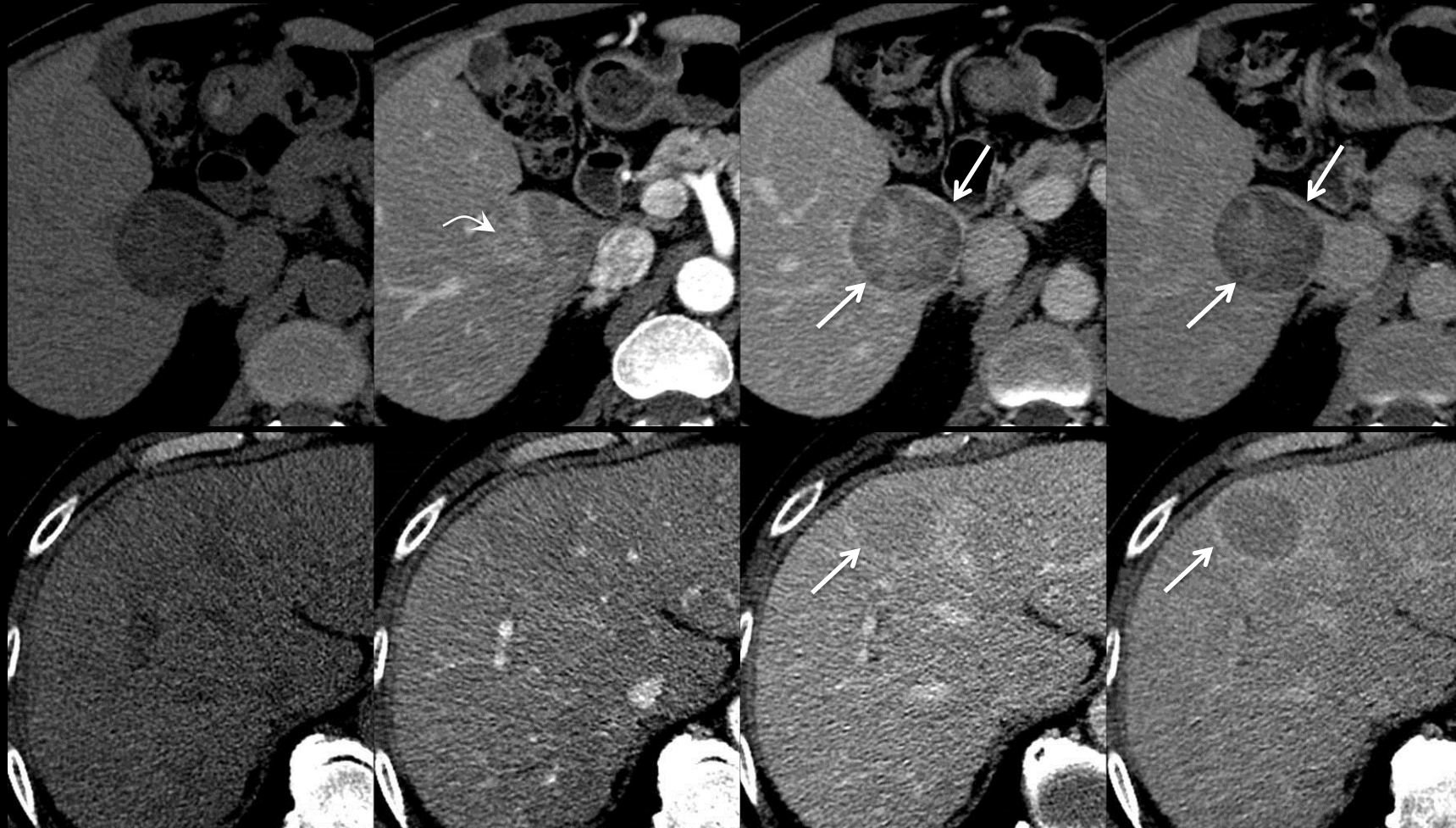


Pre

Arterial

Portal Venous

Delayed



**Capsule appearance (CT):** Figure shows masses with capsule appearance at CT. Masses shows peripheral rim enhancement in portal venous and delayed phases (capsule appearance). One mass (top row) also shows arterial phase hyper-enhancement (curved arrow).

## Capsule appearance

### Comments (continued):

- The degree of enhancement of the “capsule” usually increases from early to later phases.
- The delayed phase may be superior to the portal venous phase for depicting this feature.
- Multiplanar images also may help demonstrate capsule appearance.
- The rim’s degree of arterial phase enhancement is not relevant for characterization of this feature.
- The rim’s attenuation/intensity on non-vascular phase images is not relevant for characterization of this feature.
  - **Rationale:** To maintain congruency with OPTN definition of “capsule”, which is based only on vascular phase features.
- The terms capsule appearance and “capsule” (with quotation marks) are preferred over the term capsule.
- **Rationale:** the rim of enhancement does not always represent a [true tumor capsule](#) and may instead represent a [pseudocapsule](#).
- The distinction between true tumor capsule and pseudocapsule can only be made at pathology.



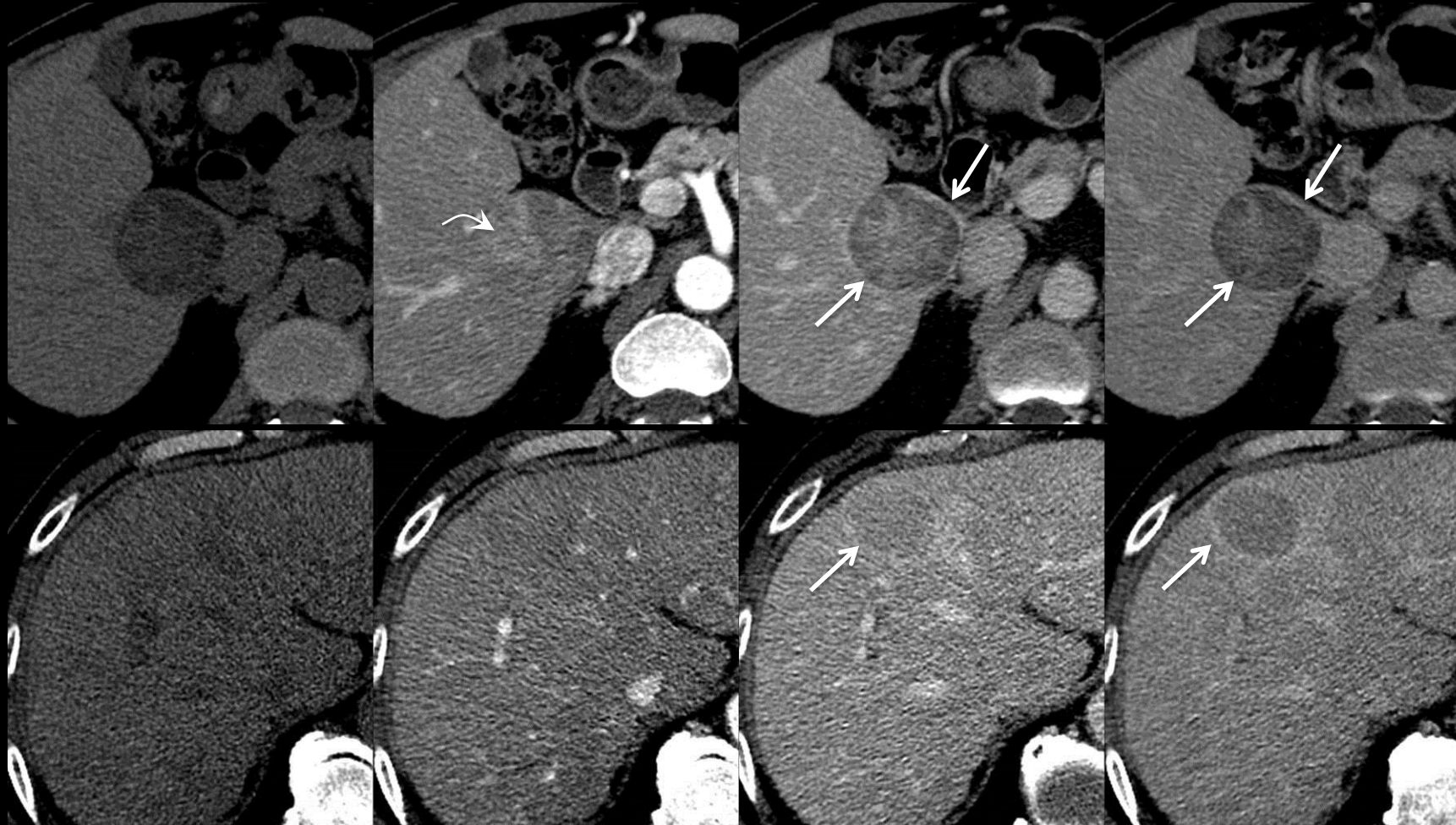


Pre

Arterial

Portal Venous

Delayed



**Capsule appearance (CT):** Figure shows masses with capsule appearance at CT. Masses show peripheral rim enhancement in portal venous and delayed phases (capsule appearance). One mass (top row) also shows arterial phase hyper-enhancement (curved arrow).

## Capsule appearance

### Comments (continued):

- In at-risk patients, capsule appearance has high positive predictive value for HCC, regardless of whether rim of enhancement represents [true tumor capsule](#) or [pseudocapsule](#).
- In observations with diffuse arterial phase hyper-enhancement, “capsule” and [corona enhancement](#) may overlap in imaging appearance. If rim enhancement increases in portal venous phase or delayed phase, characterize as “capsule”. If rim enhancement occurs in arterial phase and then [fades](#), characterize as corona enhancement.
- [Cirrhosis-associated nodules](#) are surrounded by mixed fibrous tissue. The mixed fibrous tissue around these nodules is not a true capsule, but rather condensation of cirrhotic scarring. This scar tissue may enhance at imaging and be mistaken for a “capsule”. Characterize as “capsule” only if rim enhancement is unequivocally thicker or more conspicuous than the mixed fibrous tissue surrounding background nodules ([click here for MRI example](#)).

**Categories:**

Ordinal score (1, 2, 3, 4, 5) assigned to an [observation](#) indicating its likelihood of HCC. Alternatively, the Other Malignancy (OM) category may be assigned to an observation with features [suggestive](#) of non-HCC malignancy.



## Cholangiocellular carcinoma (CCC):

A primary hepatic malignancy of cholangiocellular origin.

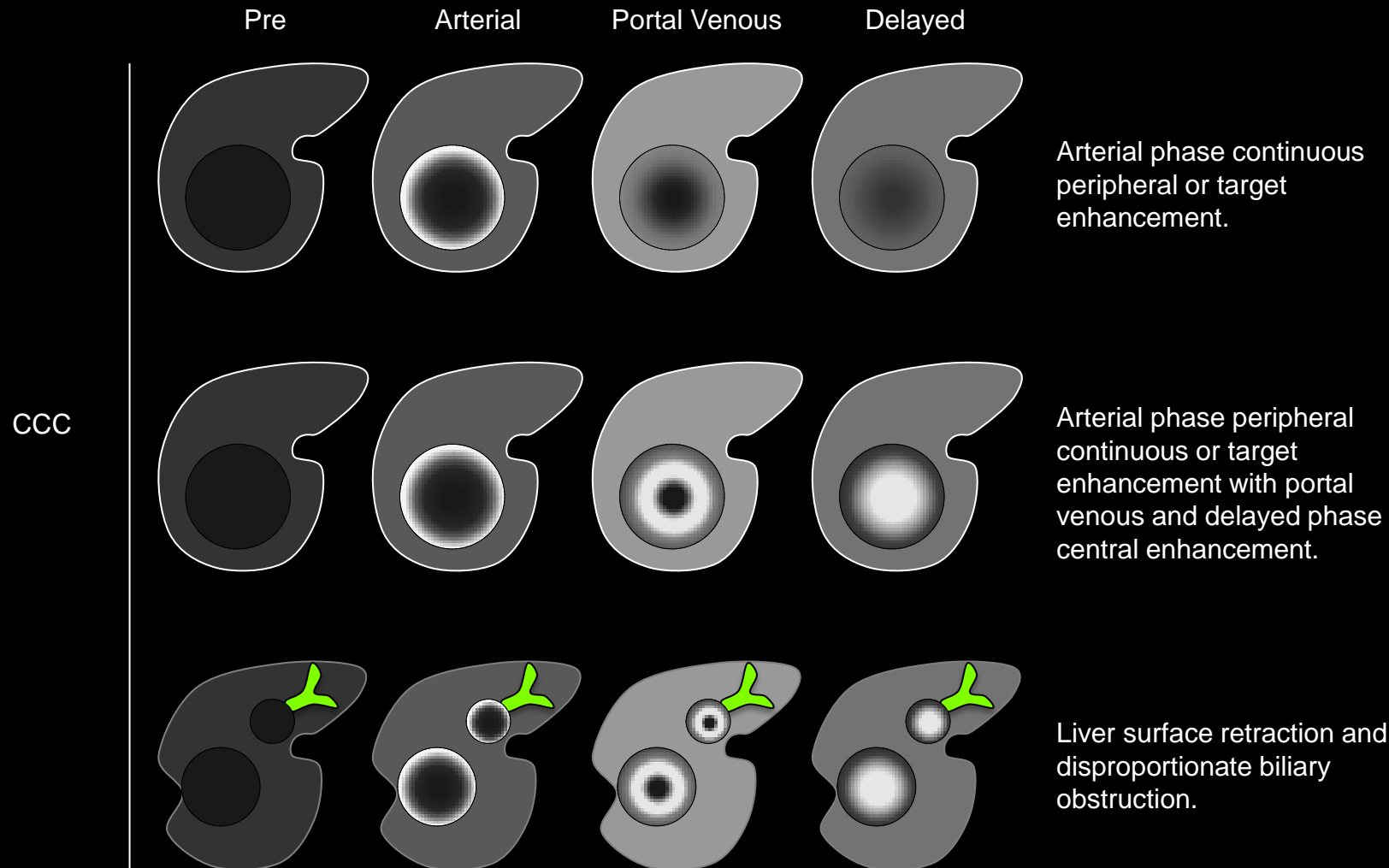
### LI-RADS Categorization:

- Observations thought to represent CCC should be categorized [OM](#).

### Comments:

- CCC is the second most common malignancy in patients with cirrhosis or other risk factors for HCC.
- Differentiation between HCC and CCC is important as the management and prognosis differ. In general, patients with CCC should not undergo liver transplant, due to unacceptably high post-transplant recurrence risk.

### [Features that favor CCC vs. features that favor HCC](#)



**Cholangiocellular carcinoma (CCC):** Schematic diagrams illustrate features that favor CCC over HCC. These include arterial phase peripheral continuous or target enhancement (top row), arterial phase peripheral continuous or target enhancement with portal venous and delayed phase central enhancement (middle row), and liver surface retraction and biliary obstruction disproportionate to size of mass (bottom row).



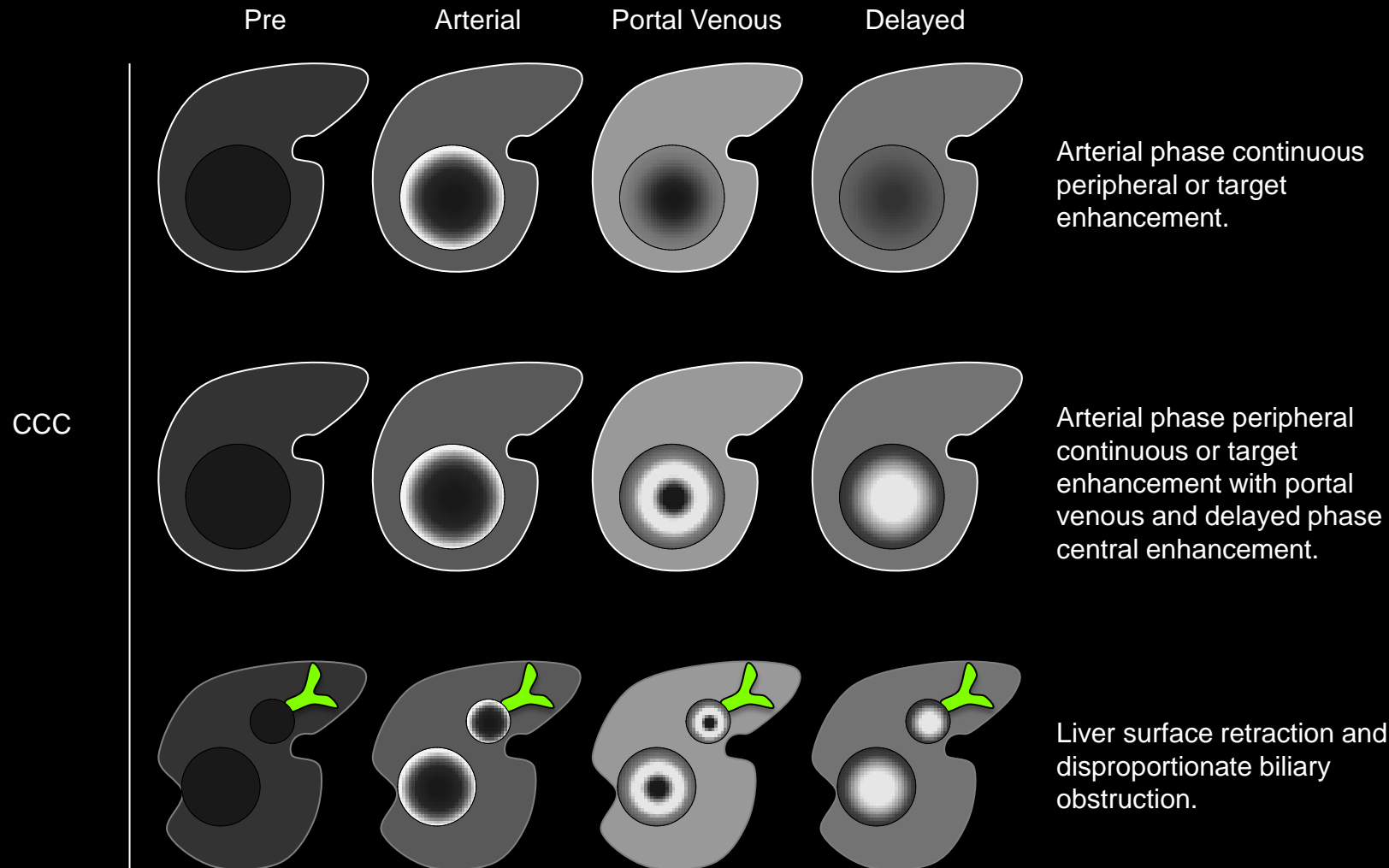
## Cholangiocellular carcinoma (CCC):

### Features that favor CCC over HCC include (partial list):

- Arterial phase target enhancement
- Portal venous and delayed phase central enhancement
- Liver surface retraction
- Biliary obstruction disproportionate to that expected based on size of mass
- Elevated CA19-9, CEA

### Features that favor HCC over CCC include (partial list):

- Diffuse arterial phase hyper-enhancement
- Arterial phase hyper-enhancement with portal venous or delayed phase washout appearance
- Intra-lesional fat
- Blood products
- Capsule appearance
- Mosaic architecture
- Tumor in vein
- Elevated AFP, AFP-L3, PIVKA/DCP



**Cholangiocellular carcinoma (CCC):** Schematic diagrams illustrate features that favor CCC over HCC. These include arterial phase peripheral continuous or target enhancement (top row), arterial phase peripheral continuous or target enhancement with portal venous and delayed phase central enhancement (middle row), and liver surface retraction and biliary obstruction disproportionate to size of mass (bottom row).





### Cholangiocellular carcinoma (CCC):

A primary hepatic malignancy of cholangiocellular origin.

#### LI-RADS Categorization:

- Observations thought to represent CCC should be categorized [OM](#).

#### Comments:

- CCC is the second most common malignancy in patients with cirrhosis or other risk factors for HCC.
- Differentiation between HCC and CCC is important as the management and prognosis differ. In general, patients with CCC should not undergo liver transplant, due to unacceptably high post-transplant recurrence risk.

#### [Features that favor CCC vs. features that favor HCC](#)

Pre

AP

PVP

Delayed 3 minutes

Pre

AP

PVP

Delayed 3 minutes

Delayed 10 minutes

**CCC (CT and MRI 3T):** 55yo woman with 6.2 cm mass. Top row: CT images. Bottom row: MR images. The mass shows target enhancement in the arterial phase and central enhancement in the 3-minute (CT and MRI) and 10-minute (MRI) delayed phase images. Notice that the 10-minute delayed phase MR image also shows hypo-enhancement along the periphery of the mass (arrow) (“peripheral washout sign”). These features suggest CCC over HCC.



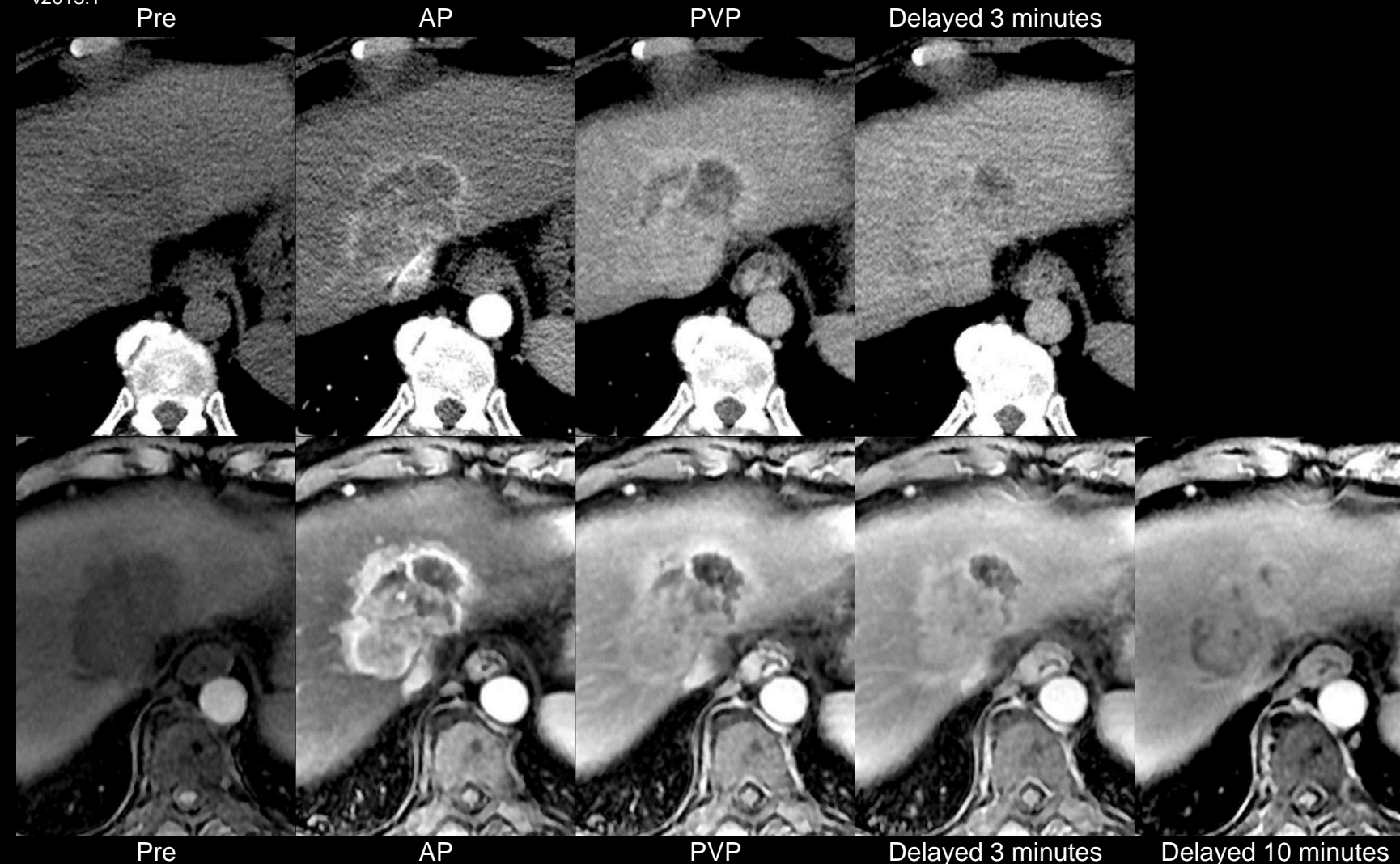
## Cholangiocellular carcinoma (CCC):

### Features that favor CCC over HCC include (partial list):

- Arterial phase target enhancement
- Portal venous and delayed phase central enhancement
- Liver surface retraction
- Biliary obstruction disproportionate to that expected based on size of mass
- Elevated CA19-9, CEA

### Features that favor HCC over CCC include (partial list):

- Diffuse arterial phase hyper-enhancement
- Arterial phase hyper-enhancement with portal venous or delayed phase washout appearance
- Intra-lesional fat
- Blood products
- Capsule appearance
- Mosaic architecture
- Tumor in vein
- Elevated AFP, AFP-L3, PIVKA/DCP



**CCC (CT and MRI 3T):** 55yo woman with 6.2 cm mass. Top row: CT images. Bottom row: MR images. The mass shows target enhancement in the arterial phase and central enhancement in the 3-minute (CT and MRI) and 10-minute (MRI) delayed phase images. Notice that the 10-minute delayed phase MR image also shows hypo-enhancement along the periphery of the mass (arrow) ("peripheral washout sign"). These features suggest CCC over HCC.





## Cirrhosis-associated nodules:

Cirrhosis-associated nodules represent a histological spectrum that includes cirrhotic nodules (CNs), also known as regenerative nodules (RNs), low-grade dysplastic nodules (LGDNs), high-grade dysplastic nodules (HGDNs), and HCC.

The cirrhotic liver contains innumerable cirrhosis-associated nodules. Except in cases of highly advanced HCC in which most of the hepatic parenchyma is replaced by tumor, the vast majority of such nodules are CNs. In patients with cirrhosis, CNs are diffusely distributed throughout the liver, but depending on imaging technique and other factors may not be discernible as discrete lesions. When visible at CT or MRI as discrete lesions, CNs tend to be uniform in size and other imaging features. Hence, while CT and MRI usually cannot provide a specific histological diagnosis, cirrhosis-associated nodules that are uniform in size and other imaging features are highly likely to be CNs. Such nodules are expected findings in cirrhosis and require no LI-RADS [categorization](#).

Nodules distinctly different from background nodules in one or more imaging features (e.g., size, attenuation/signal intensity, enhancement pattern, morphology/architecture, fat content, iron content) usually require LI-RADS categorization, as there is greater likelihood that the nodules represent LGDNs, HGDNs, or HCCs. Such nodules should be categorized LR2 or greater.

### [LI-RADS Categorization](#)

Atlas: CT, MR

1|2|3 >





## Cirrhosis-associated nodules:

### LI-RADS Categorization:

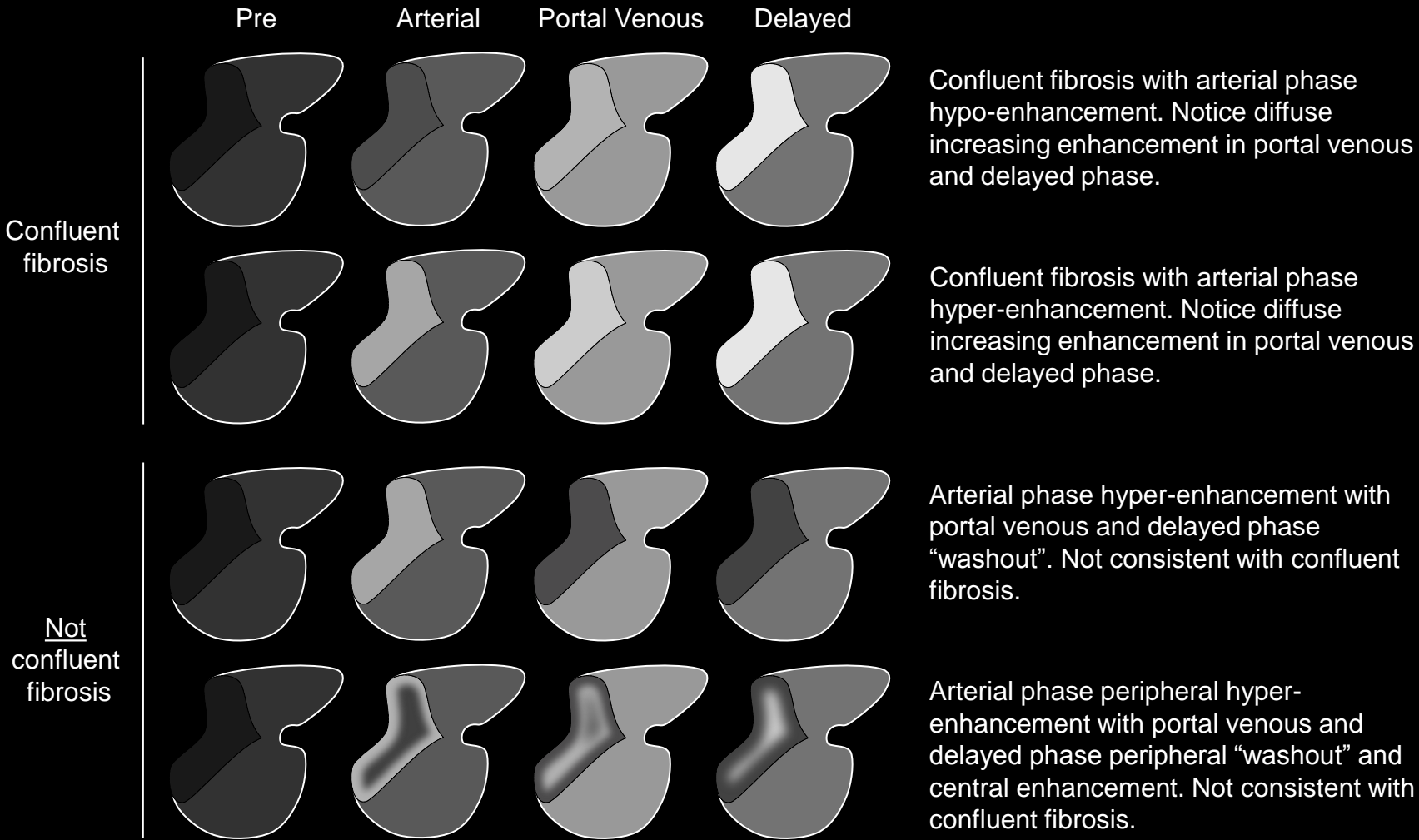
#### LR2 cirrhosis-associated nodules

- Cirrhosis-associated nodules with the imaging features below may be considered probably benign (all of the following):
  - [Diameter < 20mm](#) AND
  - [Homogeneous](#) AND
  - [Iso-enhancement](#) to background cirrhotic nodules in all phases AND
  - Differ from background nodules by having one or more of the following features:
    - Distinctly larger than background nodules (but still < 20mm)
    - Mild to moderate CT hyper-attenuation
    - Mild to moderate T1 hyper-intensity
    - Mild T2 or T2\* hypo-intensity
    - Moderate or marked T2 or T2\* hypo-intensity (e.g., [Iron-rich cirrhosis associated nodules](#))
- **Categorization:**
  - Such nodules should be categorized LR2.
- **Reporting:**
  - LR2 cirrhosis-associated nodules are common in cirrhosis and generally do not require LI-RADS reporting. Radiologists at their discretion may report them.

#### LR≥3 cirrhosis-associated nodules

**Cirrhosis-associated nodules:****LI-RADS Categorization (continued):****LR $\geq$ 3 cirrhosis-associated nodules**

- Cirrhosis-associated nodules that are distinct in imaging appearance from background nodules but that do not meet LR2 criteria cannot be considered probably benign. These include nodules with any of the following features:
  - [Diameter  \$\geq\$  20mm](#) OR
  - [Heterogeneous](#) in one or more sequences or phases OR
  - Enhancement that differs from liver in one or more phases OR
  - Any [ancillary feature](#) that favors HCC
- **Categorization:**
  - Such nodules should be categorized [LR3](#), [LR4](#), or [LR5](#) depending on size and other imaging features.
- **Reporting:**
  - The reporting of cirrhosis-associated nodules categorized LR3 depends on the presence of LR4, LR5, or [OM](#) observations elsewhere in the liver. Click [here](#) for details.
  - LR4 and LR5 observations must be reported.



**Confluent fibrosis** : Schematic diagrams illustrate observations consistent with (top two rows) and not consistent with (bottom two rows) confluent fibrosis. Confluent fibrosis typically is peripherally located, associated with liver surface retraction, and demonstrates increasing enhancement in the portal venous and delayed phase. In the arterial phase confluent fibrosis typically hypo- or iso-enhances; atypically, it hyper-enhances. Observations associated with surface retraction but without homogeneous increasing enhancement are not consistent with confluent fibrosis.

## Confluent fibrosis:

Macroscopically evident benign process of scarring in the liver parenchyma.

## LI-RADS Categorization:

- Observations thought to [definitely](#) represent confluent fibrosis should be categorized LR1.
- Observations thought to [probably](#) represent confluent fibrosis should be categorized LR2.
- Observations that are indeterminate for confluent fibrosis versus HCC should be categorized LR3 or LR4.

## [Imaging Manifestations](#)

## [Pitfalls, Challenges, Differential Diagnosis](#)

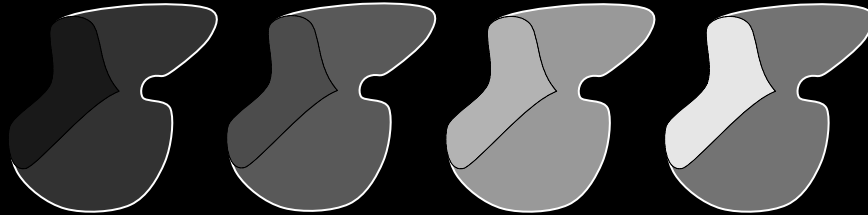
## [Other Comments](#)



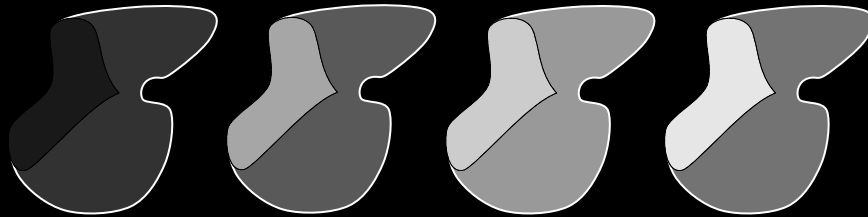


Confluent fibrosis

Pre      Arterial      Portal Venous      Delayed

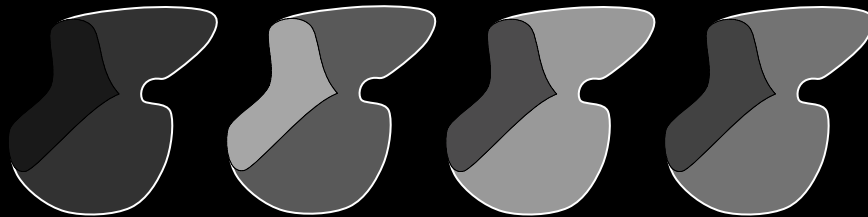


Confluent fibrosis with arterial phase hypo-enhancement. Notice diffuse increasing enhancement in portal venous and delayed phase.




Confluent fibrosis with arterial phase hyper-enhancement. Notice diffuse increasing enhancement in portal venous and delayed phase.

Not confluent fibrosis



Arterial phase hyper-enhancement with portal venous and delayed phase "washout". Not consistent with confluent fibrosis.



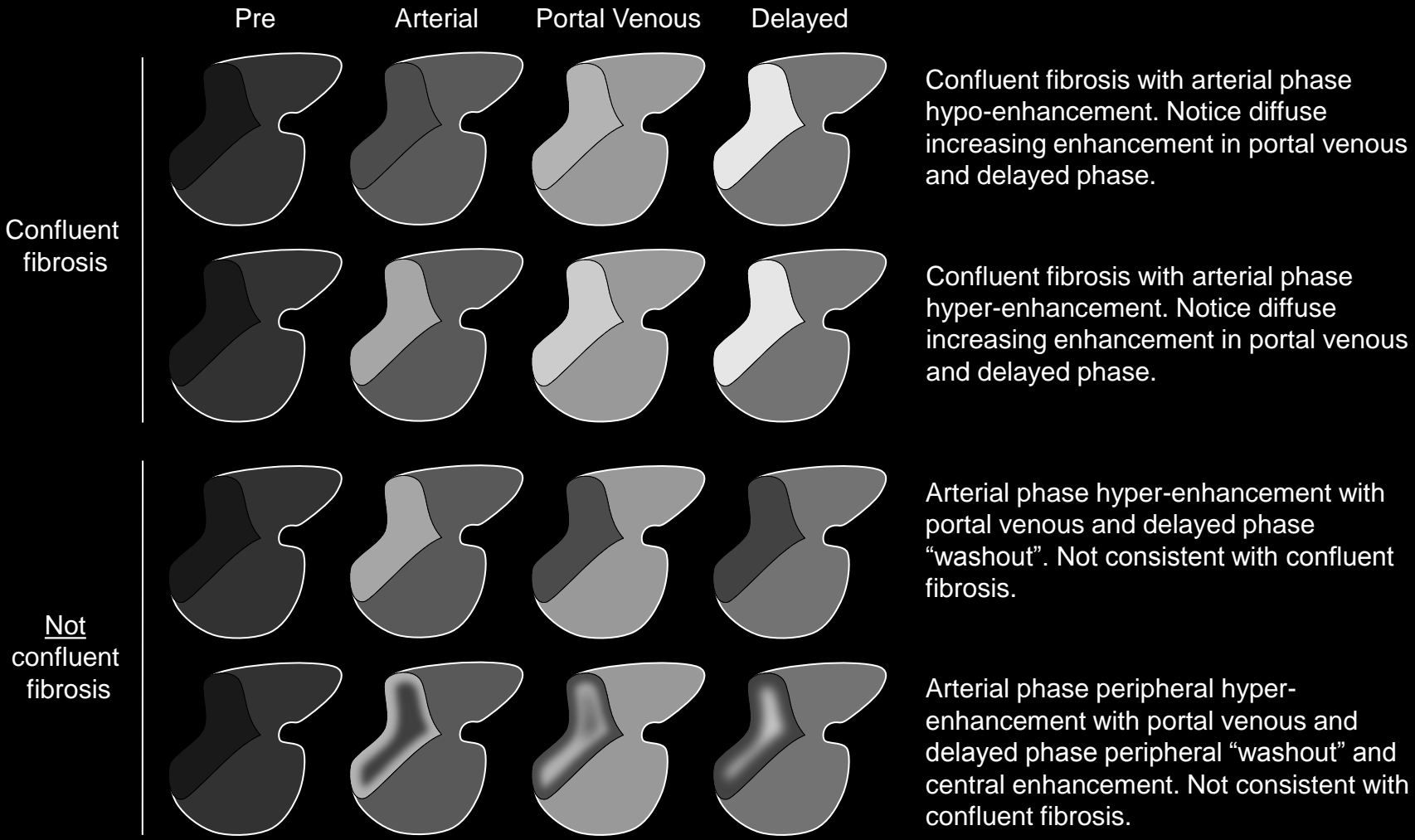
Arterial phase peripheral hyper-enhancement with portal venous and delayed phase peripheral "washout" and central enhancement. Not consistent with confluent fibrosis.

**Confluent fibrosis** : Schematic diagrams illustrate observations consistent with (top two rows) and not consistent with (bottom two rows) confluent fibrosis. Confluent fibrosis typically is peripherally located, associated with liver surface retraction, and demonstrates increasing enhancement in the portal venous and delayed phase. In the arterial phase confluent fibrosis typically hypo- or iso-enhances; atypically, it hyper-enhances. Observations associated with surface retraction but without homogeneous increasing enhancement are not consistent with confluent fibrosis.

## Confluent fibrosis:

### Imaging Manifestations:

- Confluent fibrosis typically has the following features:
  - Band-like, wedge-like, or geographic shape
  - Straight or concave borders
  - Radiates from portal hilus to contact liver surface
  - Peripherally located
  - Often involves central segments (4, 5, 8)
  - Associated with parenchymal volume loss and liver surface retraction; the volume loss often progresses on follow-up studies
- Unenhanced CT
  - Hypo-attenuating
- Unenhanced MRI
  - T1 hypo-intense
  - T2 hyper-intense
  - DW hyper-intense (due at least in part to T2 shine-through).
- [Hypo- or iso-enhancing in the arterial phase](#)
- [Increasing enhancement](#) in portal venous and delayed phases (if extra-cellular contrast agent is administered).
- Multiplanar images may help to depict the characteristic morphology: band-like or wedge-like shape; straight or concave borders.

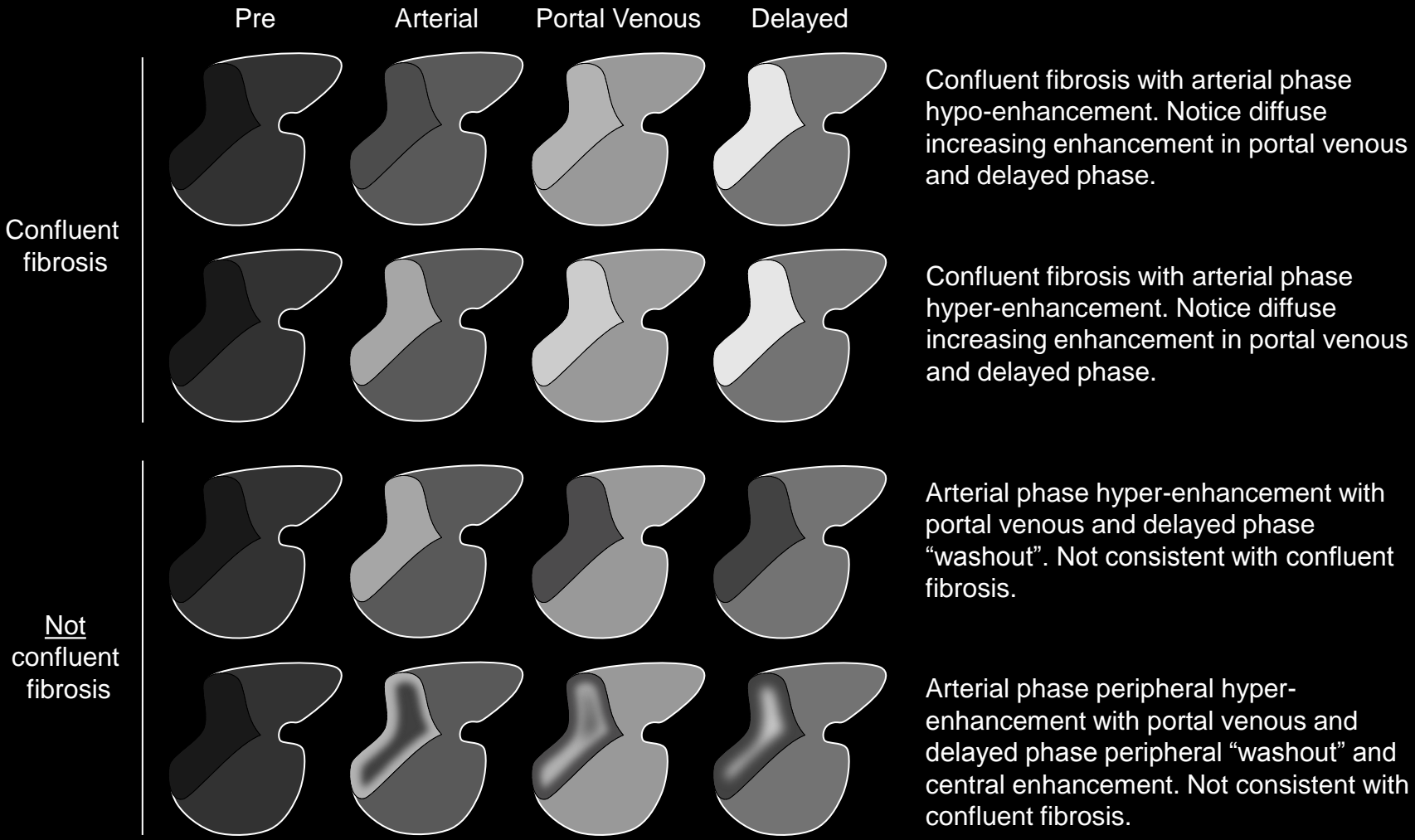


**Confluent fibrosis** : Schematic diagrams illustrate observations consistent with (top two rows) and not consistent with (bottom two rows) confluent fibrosis. Confluent fibrosis typically is peripherally located, associated with liver surface retraction, and demonstrates increasing enhancement in the portal venous and delayed phase. In the arterial phase confluent fibrosis typically hypo- or iso-enhances; atypically, it hyper-enhances. Observations associated with surface retraction but without homogeneous increasing enhancement are not consistent with confluent fibrosis.

## Confluent fibrosis:

### Pitfalls, Challenges, Differential Diagnosis:

- While confluent fibrosis typically is arterial phase hypo- or iso-enhancing, it may be arterial phase hyper-enhancing. Characteristic morphology and location usually permit correct interpretation and appropriate LI-RADS categorization as, depending on level of confidence, LR1 or LR2.
- Confluent fibrosis may overlap in imaging appearance with HCC. Features that favor confluent fibrosis: band-like or [wedge-like](#) shape with straight or concave borders (rather than round shape); liver surface retraction; and [increasing enhancement](#). Features that favor HCC: rounded shape; diffuse [arterial phase hyper-enhancement](#); [washout appearance](#); [capsule appearance](#); [intra-lesional fat](#); and presence of intra-lesional or peri-lesional hemorrhage ([blood products](#)).
- Confluent fibrosis may overlap in imaging appearance with CCC. Features that favor confluent fibrosis: band-like or wedge-like shape with straight or concave borders; extension from portal hilus to contact liver surface; and [homogeneous delayed enhancement](#). Features that favor CCC: rounded shape and peripheral or target [heterogeneous enhancement](#).



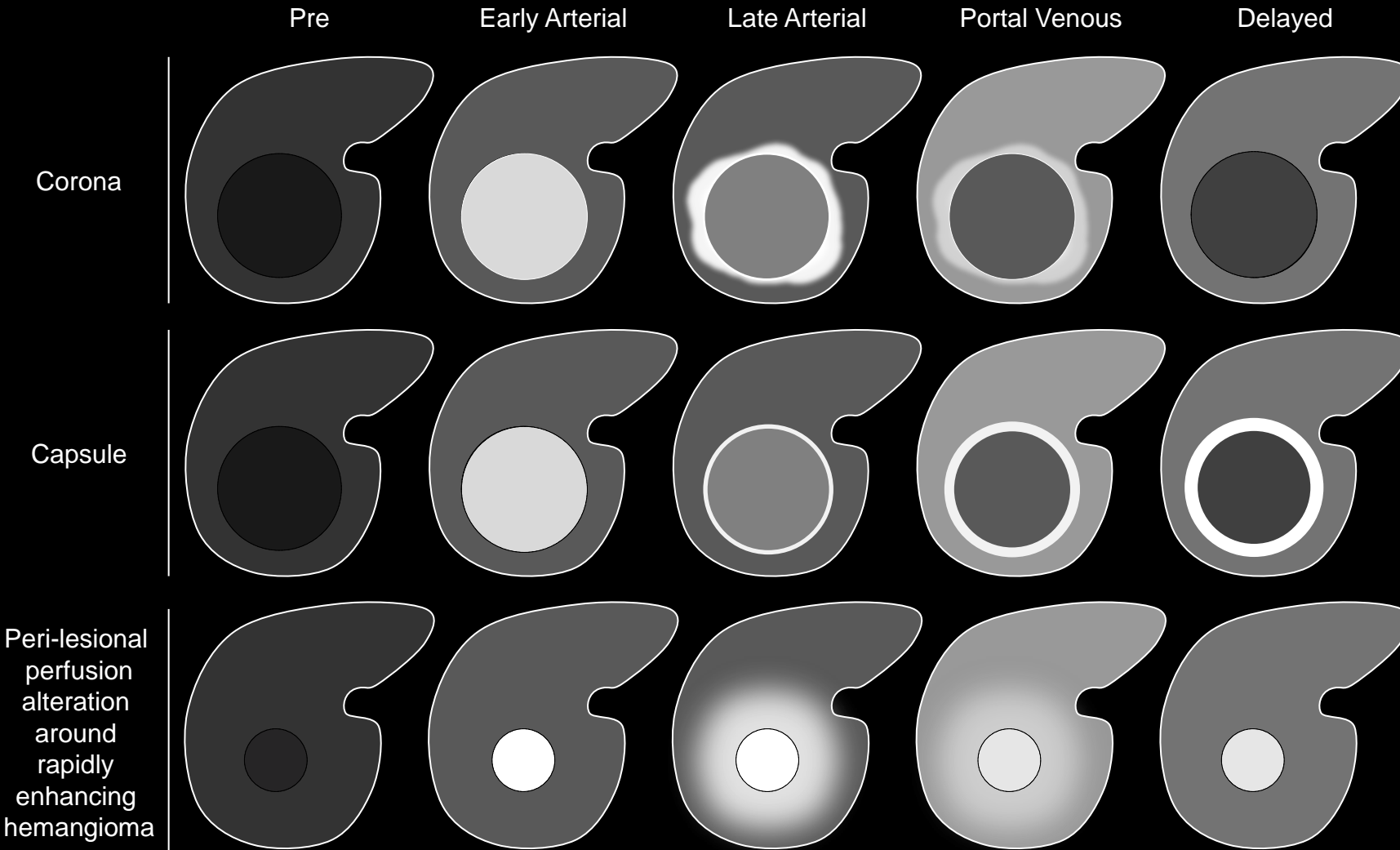
**Confluent fibrosis:**

**Other Comments:**

- Confluent fibrosis is more common in PSC, secondary biliary cirrhosis, and alcoholic liver disease than in viral liver disease.

**Confluent fibrosis** : Schematic diagrams illustrate observations consistent with (top two rows) and not consistent with (bottom two rows) confluent fibrosis. Confluent fibrosis typically is peripherally located, associated with liver surface retraction, and demonstrates increasing enhancement in the portal venous and delayed phase. In the arterial phase confluent fibrosis typically hypo- or iso-enhances; atypically, it hyper-enhances. Observations associated with surface retraction but without homogeneous increasing enhancement are not consistent with confluent fibrosis.





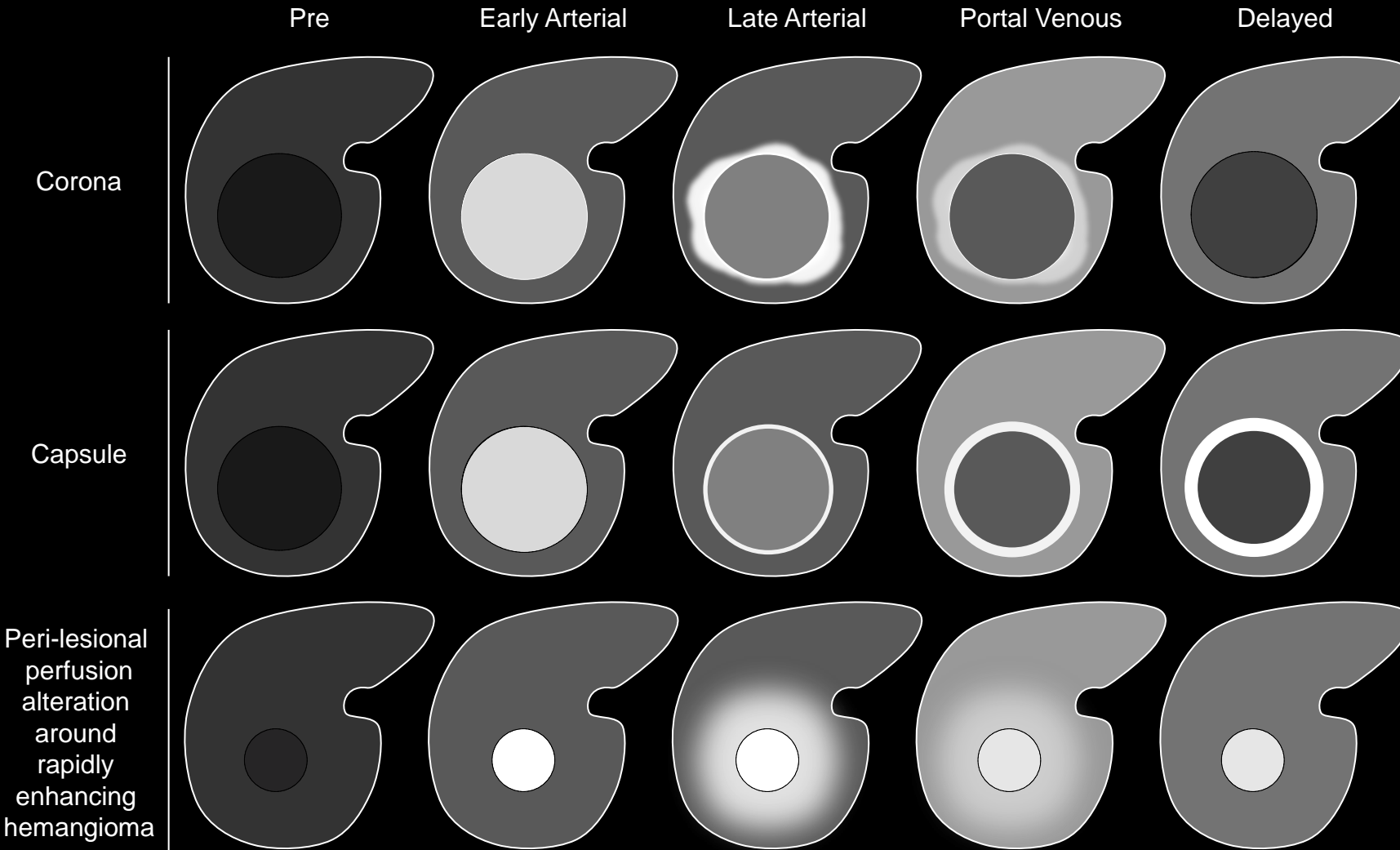
**Corona enhancement:** Corona enhancement is a zone or rim of peri-observation enhancement in the late arterial or early portal venous phase occurring after rapid dissipation of contrast material from an arterial phase hyper-enhancing mass. The corona may have variable thickness and uniformity. It typically fades toward iso-attenuation/iso-intensity in the late portal venous and delayed phase. Shown for comparison are a mass with capsule appearance (second row) and a rapidly enhancing hemangioma with peri-lesional perfusion alteration (third row).

### Corona enhancement:

Zone or rim of peri-observation enhancement in the late [arterial phase](#) or early [portal venous phase](#) occurring after rapid dissipation of contrast material from an arterial phase hyper-enhancing mass.

### Comments:

- Applies to masses that diffusely hyper-enhance in the arterial phase initially and then develop a zone or rim of peri-lesional enhancement as the enhancement of the mass itself declines.
- Does not apply to masses without diffuse arterial phase hyper-enhancement or to masses without rapid reduction in enhancement after the arterial phase.
- Corona enhancement is an [ancillary feature](#) that favors HCC.
- Radiologists at their discretion may apply corona enhancement to upgrade category (up to LR4).
- Corona enhancement usually [fades](#) to iso-enhancement in the [portal venous phase](#) or [delayed phase](#).
- Corona enhancement may have variable thickness and uniformity. It may be circumferential or eccentric/non-symmetric.
- Corona enhancement is attributed to early drainage of contrast material from hypervascular tumor such as HCC (or metastasis) into surrounding sinusoids/portal venules.



**Corona enhancement:** Corona enhancement is a zone or rim of peri-observation enhancement in the late arterial or early portal venous phase occurring after rapid dissipation of contrast material from an arterial phase hyper-enhancing mass. The corona may have variable thickness and uniformity. It typically fades toward iso-attenuation/iso-intensity in the late portal venous and delayed phase. Shown for comparison are a mass with capsule appearance (second row) and a rapidly enhancing hemangioma with peri-lesional perfusion alteration (third row).

## Corona enhancement:

### Comments (continued):

- Corona enhancement is seen most frequently if multiple arterial phases are acquired with high temporal resolution. It is seen infrequently if a single arterial phase is acquired.
- Presence of corona enhancement differentiates hypervascular tumor (e.g., HCC) from vascular pseudolesion (e.g., arterio-portal shunt).
- In masses with diffuse arterial phase hyper-enhancement, corona enhancement and [capsule appearance](#) may overlap in appearance. If rim enhancement occurs in the arterial phase or portal venous phase and subsequently fades in later phases, characterize as corona enhancement. If rim enhancement increases in portal venous phase and delayed phase, characterize as capsule appearance.
- Corona enhancement associated with HCC may overlap in appearance with peri-lesional perfusional alterations associated with rapidly enhancing hemangiomas. If the mass itself fades to iso-enhancement in the portal venous or delayed phase or “washes out” to hypo-enhancement (i.e., the mass may be an HCC), characterize as corona enhancement. If the mass shows persistent delayed enhancement approximately paralleling that of the blood pool (i.e., the mass is definitely or probably a rapidly enhancing hemangioma), do not characterize as corona enhancement.



LI-RADS Category	Concept and Definition	Reporting and Management
<b>LR1</b> Definitely Benign	<b>Concept:</b> 100% certainty observation is benign. <b>Definition:</b> Observation with imaging features diagnostic of a benign entity, or definite disappearance at follow up in absence of treatment.	<b>Reporting:</b> May be reported at radiologist's discretion. Exception: If reported LR3, LR4, or LR5 on the prior exam, usually should be reported. <b>Management:</b> Continued routine surveillance usually is appropriate.
<b>LR2</b> Probably Benign	<b>Concept:</b> High probability observation is benign. <b>Definition:</b> Observation with imaging features suggestive but not diagnostic of a benign entity.	<b>Reporting:</b> May be reported at radiologist's discretion. Exception: If reported LR3, LR4, or LR5 on the prior exam, usually should be reported. <b>Management:</b> Continued routine surveillance usually is appropriate.
<b>LR3</b> Intermediate probability for HCC	<b>Concept:</b> Both HCC and benign entity have moderate probability. <b>Definition:</b> Observation that does not meet criteria for other LI-RADS categories.	<b>Reporting:</b> Should be reported if no LR4, LR5, or OM observations are present elsewhere in the liver. If LR4, LR5, or OM observations are present, may be reported at radiologist's discretion. <b>Management:</b> Variable follow-up (depends on observation size, stability, and clinical considerations)
<b>LR4</b> Probably HCC	<b>Concept:</b> High probability observation is HCC but there is not 100% certainty. <b>Definition:</b> Observation with imaging features suggestive but not diagnostic of HCC.	<b>Reporting:</b> Must be reported. <b>Management:</b> Close follow up, additional imaging, biopsy, or treatment. Does not contribute to radiologic T-staging unless multiple LR4 observations in aggregate are interpreted as multifocal HCC.
<b>LR5</b> Definitely HCC	<b>Concept:</b> 100% certainty observation is HCC. <b>Definition:</b> Observation with imaging features diagnostic of HCC or proven to be HCC at histology.	<b>Reporting:</b> Must be reported. <b>Management:</b> Treatment without biopsy. Contributes to radiologic T-staging.
<b>LR5V</b> Definitely HCC with Tumor in Vein	<b>Concept:</b> 100% certainty that observation is HCC invading vein. <b>Definition:</b> Observation with imaging features diagnostic of HCC invading vein.	<b>Reporting:</b> Must be reported. <b>Management:</b> Treatment without biopsy. Denotes radiologic T-stage 4b.
<b>LR5 Treated</b> Treated HCC	<b>Concept:</b> A loco-regionally treated HCC. <b>Definition:</b> LR5A or 5B observation or biopsy-proven HCC lesion that has undergone loco-regional treatment.	<b>Reporting:</b> Must be reported. <b>Management:</b> Close follow up to assess treatment response.
<b>OM</b> Other Malignancy	<b>Concept:</b> High probability that observation is a malignancy other than HCC. <b>Definition:</b> Observation with features suggestive of non-HCC malignancy.	<b>Reporting:</b> Must be reported. <b>Management:</b> Variable, depending on clinical history and type of malignancy suspected. Appropriate management may include close follow-up, additional imaging, biopsy, or treatment.



**Cyst:**

Fluid-filled closed cavity lined by benign epithelium.

**LI-RADS Categorization:**

- Observations thought to [definitely](#) represent cysts should be categorized LR1.
  - e.g., cysts with typical imaging features and large enough to characterize
- Observations thought to [probably](#) represent cysts should be categorized LR2.
  - e.g., cysts with mildly atypical features or low density lesions too small to characterize at CT
- Observations that are indeterminate for cysts versus HCC should be categorized LR3 or LR4.

**Comments:**

- Most cysts are easily recognized, cause no diagnostic confusion, and do not require reporting. Radiologists may choose at their discretion to report cyst(s).
- The two most common cysts in the liver are hepatic cysts and cystic biliary hamartomas. Peribiliary cysts are rare cysts associated with advanced cirrhosis. In cirrhosis, they represent cystic dilatation of the extramural glands in the periductal connective tissue. They parallel the bile ducts; they may be misinterpreted as dilated bile ducts. Hepatic cysts, cystic biliary hamartomas, and peribiliary cysts do not communicate with the bile ducts.

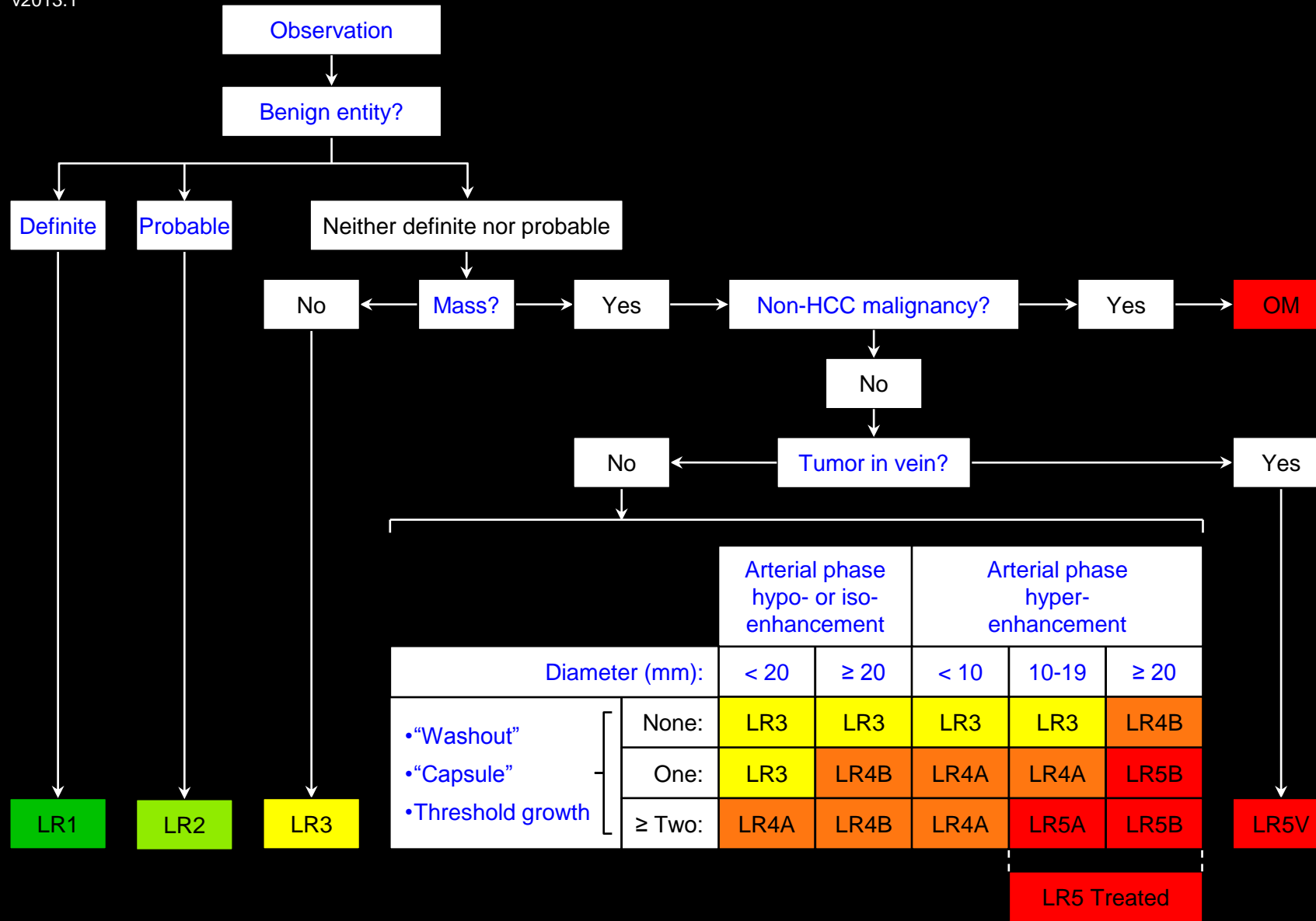
**Atlas:** CT, MR

**Definite:**

With 100% confidence or absolute certainty.  
Synonymous with [unequivocal](#).

**Comments:**

- When an observation is described as a *definite* HCC (i.e., categorized [LR5](#)), no additional evaluation such as biopsy is needed to establish the diagnosis of HCC.



Apply Ancillary Features and then Tie-Breaking Rules to Adjust Category

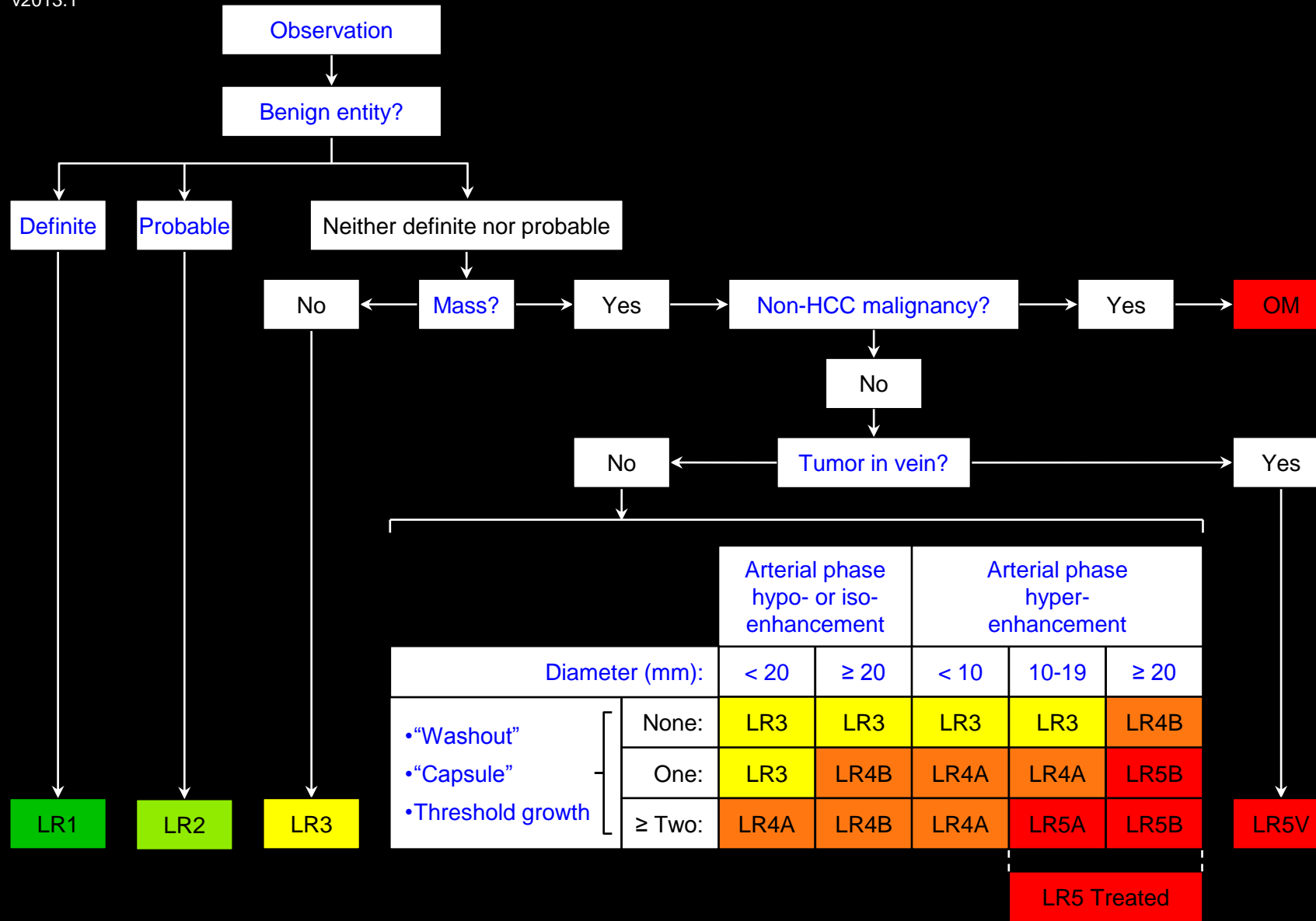
## Definite benign entities (examples):

- [Cyst](#)
- [Hemangioma](#)
- [Vascular anomaly](#)
- [Perfusion alteration](#)
- [Hepatic fat deposition](#) or [sparing](#)
- [Hypertrophic pseudomass](#)
- [Confluent fibrosis](#)
- [Focal scar](#)
- Observation that spontaneously [disappears](#) at follow-up

## Comments:

- With few exceptions, the list of definite benign entities and [probable benign entities](#) is the same. The categorization as LR1 or LR2 depends on the level of certainty.
- Observations with features [diagnostic](#) of a benign entity are categorized LR1.
- Observations with features [suggestive](#) of but not [diagnostic](#) of a benign entity are categorized LR2. For example, an observation thought to be a benign entity but with [atypical](#) imaging features is appropriately categorized LR2.
- Observations with features equivocal for benign entities, that do not meet LR4 or LR5 criteria, and that do not have features suggestive of [non-HCC malignancy](#) should be categorized LR3.



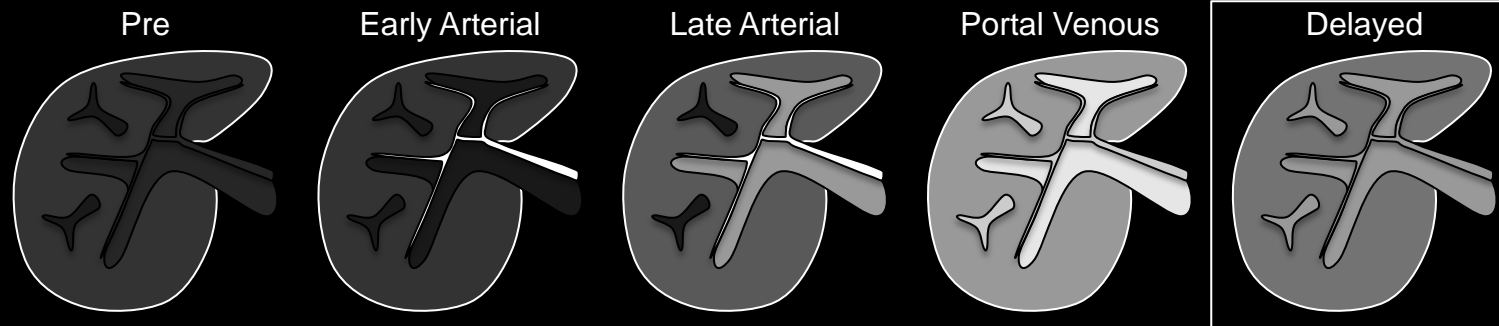


Apply Ancillary Features and then Tie-Breaking Rules to Adjust Category

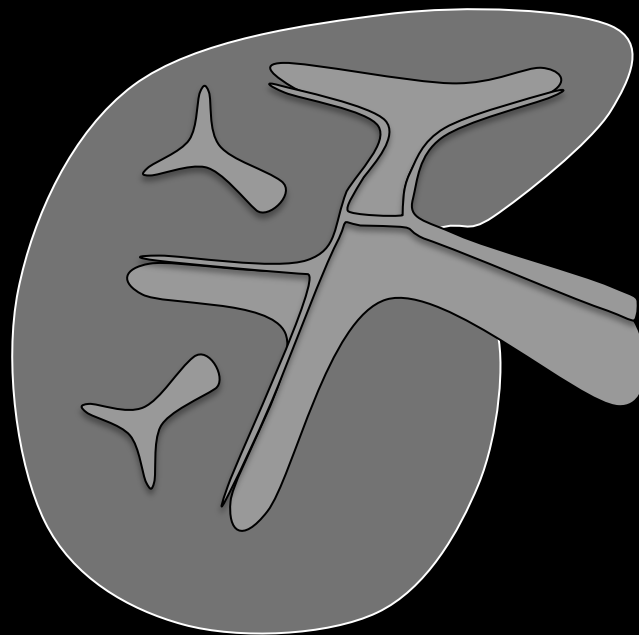
## Definite benign entities (examples):

### Comments (continued):

- LI-RADS v2013.1 does not list focal nodular hyperplasia (FNH) or hepatocellular adenoma (HCA) as examples of benign entities.
- Rationale:** Although FNH-like lesions may occur in cirrhosis, they are rare and difficult to diagnose reliably by non-invasive imaging. HCAs are rare in cirrhosis.



Delayed Phase



**Delayed phase:** Schematic diagrams depict pre-contrast and post-extracellular contrast early arterial, late arterial, portal venous, and delayed phase images. Delayed phase is defined by enhancement to similar degree of portal veins and hepatic veins. Liver parenchyma usually is enhanced to lesser degree than in portal venous phase.

### Delayed phase:

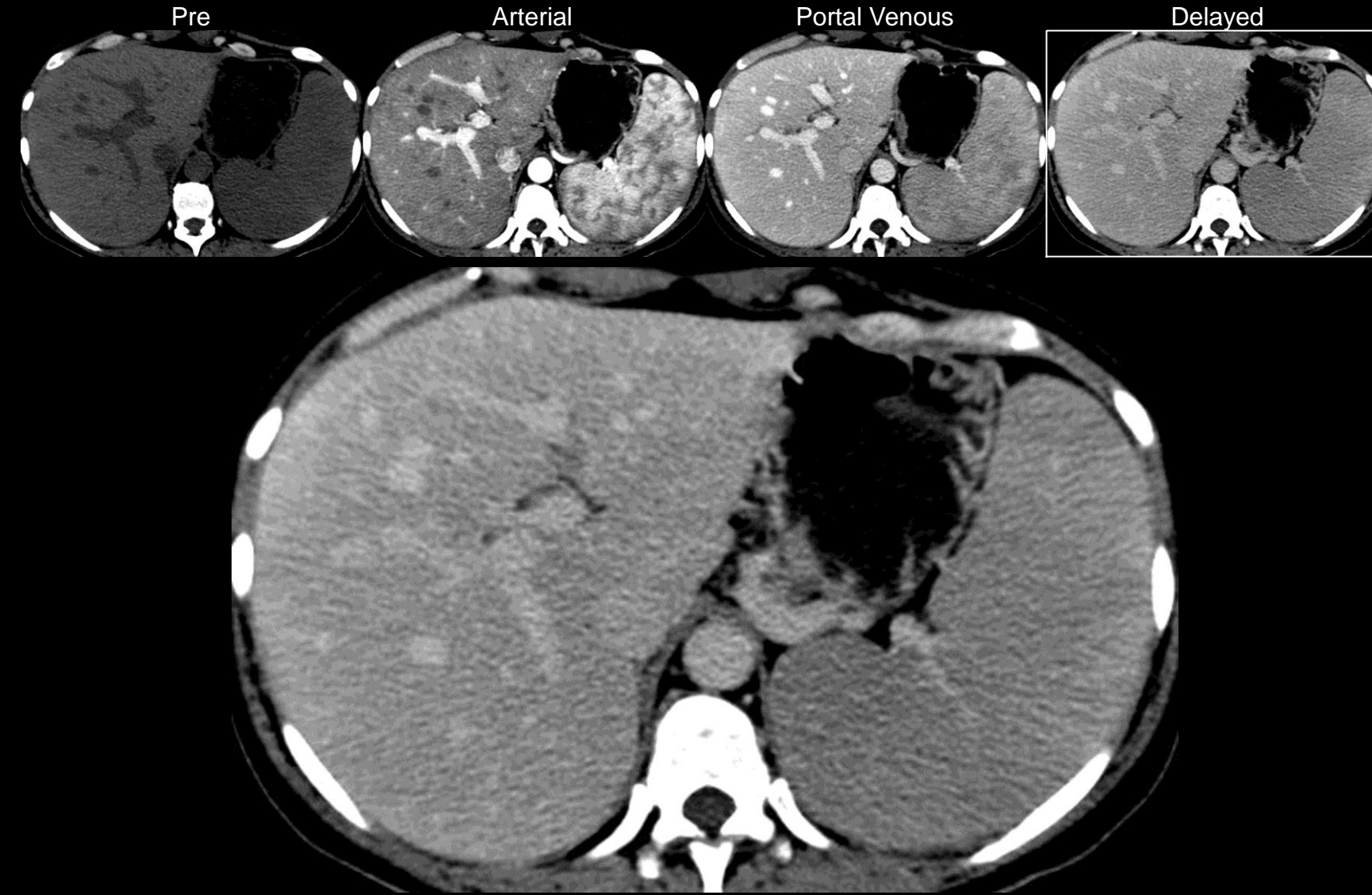Post-contrast phase acquired with extracellular agents after the [portal venous phase](#) and with the following characteristics:

- Portal and hepatic veins are enhanced but less than in portal venous phase.
- Liver parenchyma is enhanced but usually less than in portal venous phase.

### Comments:

- Delayed phase is required for MRI and suggested for CT (it is required by OPTN for both CT and MRI).
- Delayed phase usually should be acquired at around 3-5 minutes.
- The term delayed phase applies to CT or MRI with extracellular agents and to MRI with extracellular agents with modest hepatocellular uptake (e.g., gadobenate).
- It does not apply to MRI with agents with strong hepatocellular uptake (e.g., gadoxetate). With such agents:
  - The term “transitional phase” or “late dynamic phase” is preferred for images acquired shortly after portal venous phase.
  - The term “hepatobiliary phase” or “hepatocyte phase” is preferred for even more delayed images showing biliary excretion and peak enhancement of liver parenchyma.

**Atlas:** [CT](#), [MR](#)



**Delayed phase (CT):** Delayed phase CT image shows enhancement of portal and hepatic veins and of liver parenchyma. The enhancement of the portal and hepatic veins and of the liver parenchyma is less than in the portal venous phase.

### Delayed phase:

Post-contrast phase acquired with extracellular agents after the [portal venous phase](#) and with the following characteristics:

- Portal and hepatic veins are enhanced but less than in portal venous phase.
- Liver parenchyma is enhanced but usually less than in portal venous phase.

### Comments:

- Delayed phase is required for MRI and suggested for CT (it is required by OPTN for both CT and MRI).
- Delayed phase usually should be acquired at around 3-5 minutes.
- The term delayed phase applies to CT or MRI with extracellular agents and to MRI with extracellular agents with modest hepatocellular uptake (e.g., gadobenate).
- It does not apply to MRI with agents with strong hepatocellular uptake (e.g., gadoxetate). With such agents:
  - The term “transitional phase” or “late dynamic phase” is preferred for images acquired shortly after portal venous phase.
  - The term “hepatobiliary phase” or “hepatocyte phase” is preferred for even more delayed images showing biliary excretion and peak enhancement of liver parenchyma.

Atlas: [MR](#), [Schematic](#)



**Delayed phase:**

Post-contrast phase acquired with extracellular agents after the [portal venous phase](#) and with the following characteristics:

- Portal and hepatic veins are enhanced but less than in portal venous phase.
- Liver parenchyma is enhanced but usually less than in portal venous phase.

**Comments:**

- Delayed phase is required for MRI and suggested for CT (it is required by OPTN for both CT and MRI).
- Delayed phase usually should be acquired at around 3-5 minutes.
- The term delayed phase applies to CT or MRI with extracellular agents and to MRI with extracellular agents with modest hepatocellular uptake (e.g., gadobenate).
- It does not apply to MRI with agents with strong hepatocellular uptake (e.g., gadoxetate). With such agents:
  - The term “transitional phase” or “late dynamic phase” is preferred for images acquired shortly after portal venous phase.
  - The term “hepatobiliary phase” or “hepatocyte phase” is preferred for even more delayed images showing biliary excretion and peak enhancement of liver parenchyma.

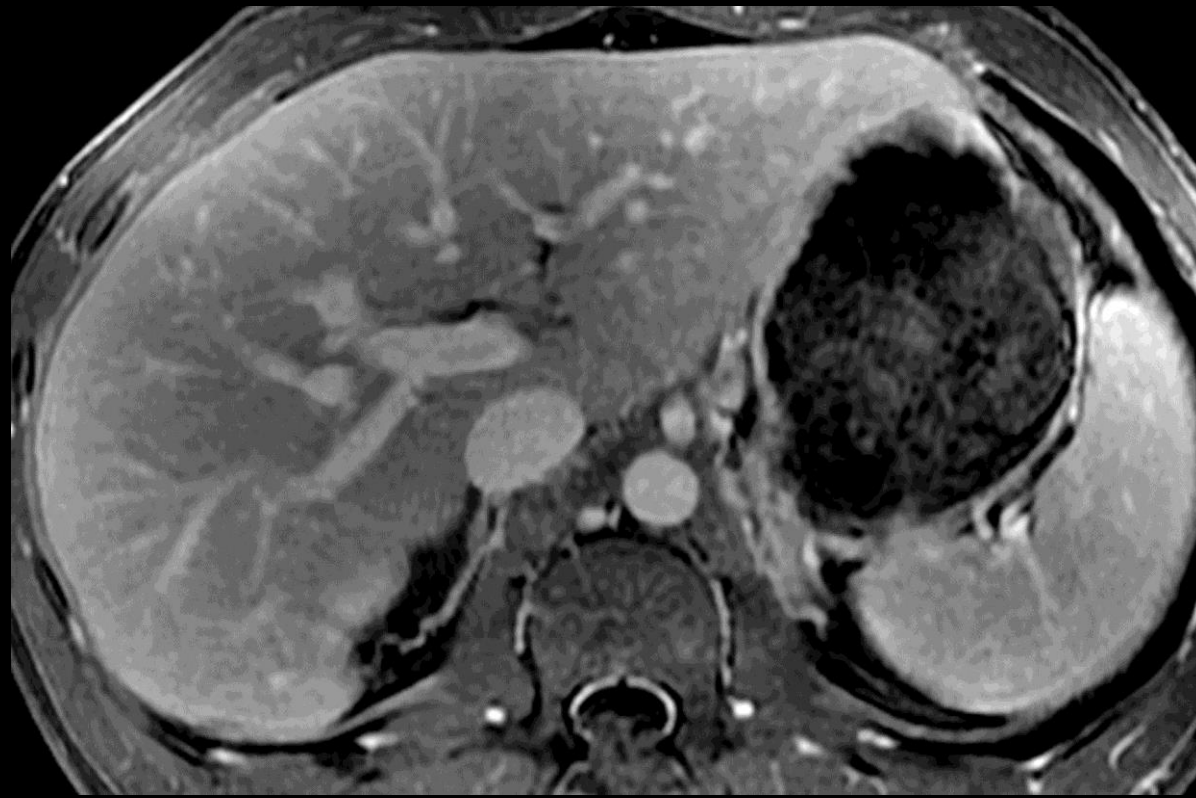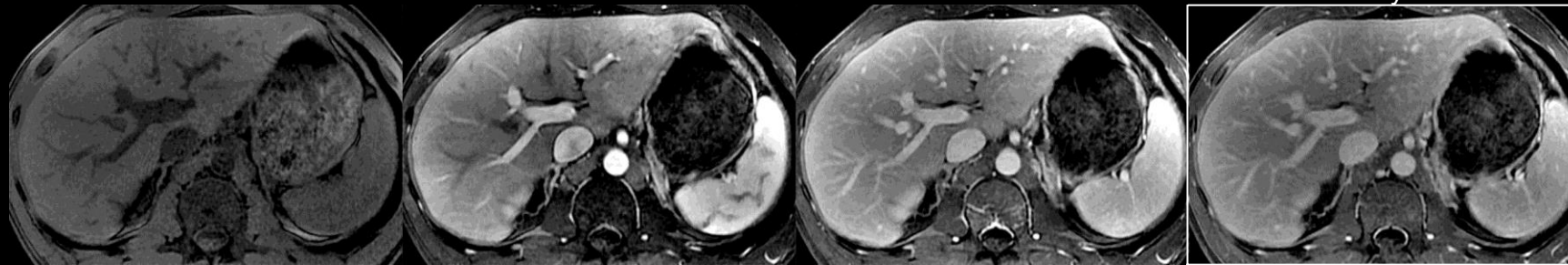
**Atlas:** [CT](#), [Schematic](#)

Pre

Arterial

Portal Venous

Delayed



**Delayed phase (MRI):** Delayed phase MR image shows enhancement of portal and hepatic veins and of liver parenchyma. The enhancement of the portal and hepatic veins and of the liver parenchyma is less than in the portal venous phase.





## Delayed phase hypo-enhancement:

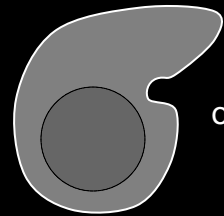

Enhancement in the [delayed phase](#) that [unequivocally](#) is less than that liver.

### Comments:

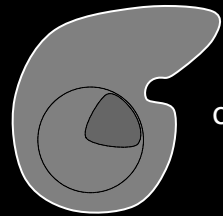
- Applies only to enhancing observations that, in whole or in part, unequivocally are lower in attenuation or intensity than liver in the delayed phase.
- Does not apply to non-enhancing observations.
- The attenuation or intensity of the observation should be compared to that of the adjacent liver parenchyma. If the liver parenchyma visually consists of both nodules and fibrosis, then attenuation or intensity of the observation should be compared to that of the composite liver tissue (i.e., a visual average of the nodules and fibrosis) (see schematics on left).
- The degree of arterial phase and portal venous phase enhancement is not relevant for characterization of this imaging feature.
- Delayed phase hypo-enhancement is part of the definition of [washout appearance](#).
- Washout appearance is a LI-RADS major feature. It is defined as a temporal reduction in enhancement relative to liver from an earlier to a later phase, resulting in [portal venous phase hypo-enhancement](#) or delayed phase hypo-enhancement.

**Atlas:** CT, MR

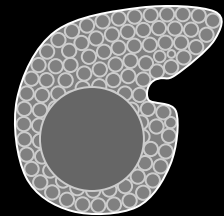
Pre      Arterial      Portal Venous      Delayed



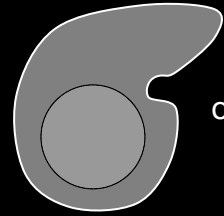

or



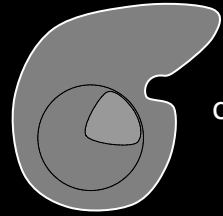
or



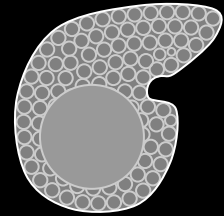
At least part of observation is hypo-enhanced



or



or

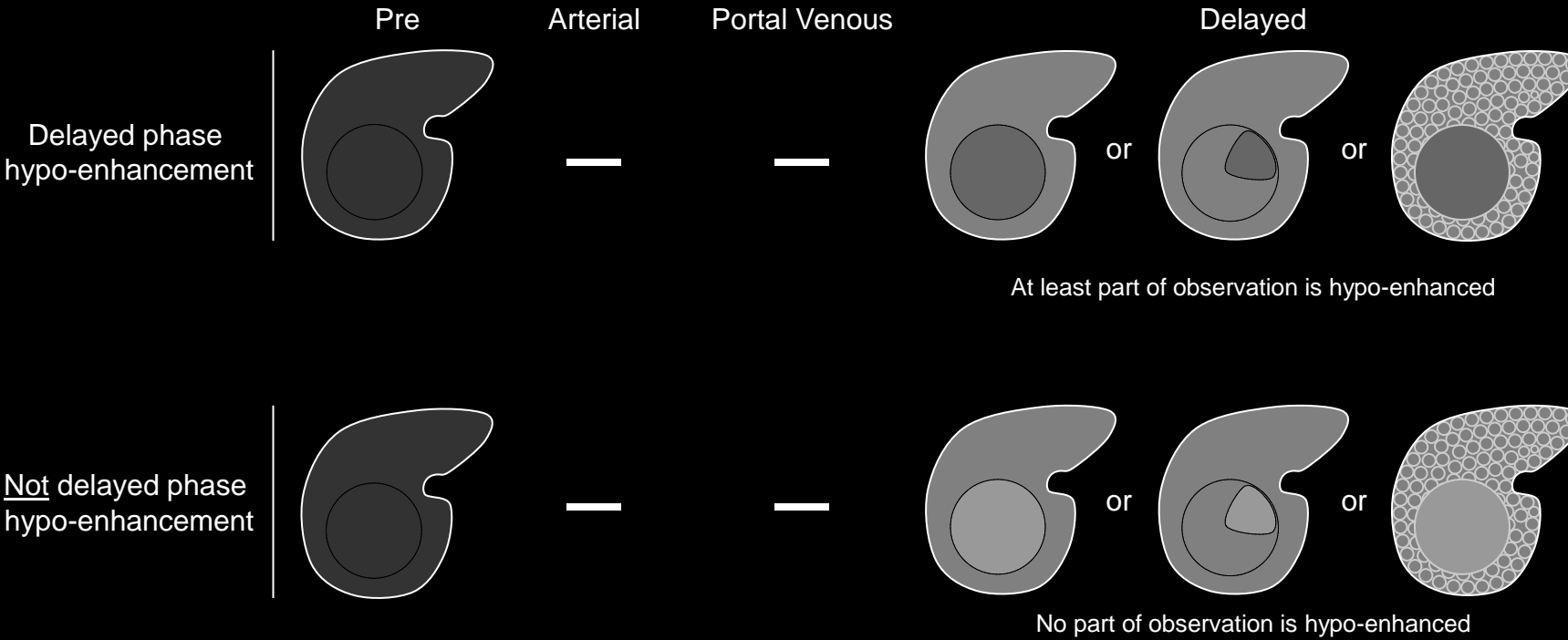


No part of observation is hypo-enhanced

Delayed phase hypo-enhancement

Not delayed phase hypo-enhancement

**Delayed phase hypo-enhancement:** Schematic diagrams illustrate observations with (top row) and without (bottom row) delayed phase hypo-enhancement. Observations with delayed phase hypo-enhancement are enhancing observations that, in whole or in part, unequivocally are lower in attenuation or intensity than liver in the delayed phase, regardless of degree of enhancement in arterial or portal venous phase. Observations may be hypo- (this slide), iso- ([click here](#)), or hyper- ([click here](#)) attenuating/intense pre-contrast. If the liver parenchyma visually consists of both nodules and fibrosis (first row, delayed phase, right-most liver), then enhancement of the observation should be compared to that of the composite liver tissue.



**Delayed phase hypo-enhancement:** Schematic diagrams illustrate observations with (top row) and without (bottom row) delayed phase hypo-enhancement. Observations with delayed phase hypo-enhancement are enhancing observations that, in whole or in part, unequivocally are lower in attenuation or intensity than liver in the delayed phase, regardless of degree of enhancement in arterial or portal venous phase. Observations may be hypo- ([click here](#)), iso- (this slide), or hyper- ([click here](#)) attenuating/intense pre-contrast. If the liver parenchyma visually consists of both nodules and fibrosis (first row, delayed phase, right-most liver), then enhancement of the observation should be compared to that of the composite liver tissue.

## Delayed phase hypo-enhancement:

Enhancement in the [delayed phase](#) that [unequivocally](#) is less than that liver.

### Comments:

- Applies only to enhancing observations that, in whole or in part, unequivocally are lower in attenuation or intensity than liver in the delayed phase.
- Does not apply to non-enhancing observations.
- The attenuation or intensity of the observation should be compared to that of the adjacent liver parenchyma. If the liver parenchyma visually consists of both nodules and fibrosis, then attenuation or intensity of the observation should be compared to that of the composite liver tissue (i.e., a visual average of the nodules and fibrosis) (see schematics on left).
- The degree of arterial phase and portal venous phase enhancement is not relevant for characterization of this imaging feature.
- Delayed phase hypo-enhancement is part of the definition of [washout appearance](#).
- Washout appearance is a LI-RADS major feature. It is defined as a temporal reduction in enhancement relative to liver from an earlier to a later phase, resulting in [portal venous phase hypo-enhancement](#) or delayed phase hypo-enhancement.

**Atlas:** CT, MR



## Delayed phase hypo-enhancement:

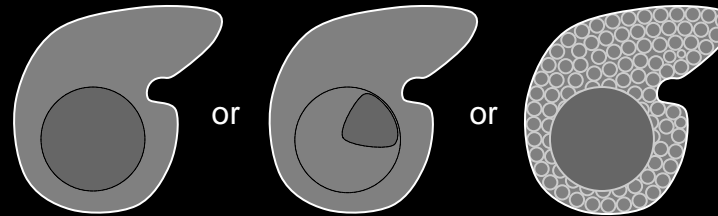

Enhancement in the [delayed phase](#) that [unequivocally](#) is less than that liver.

### Comments:

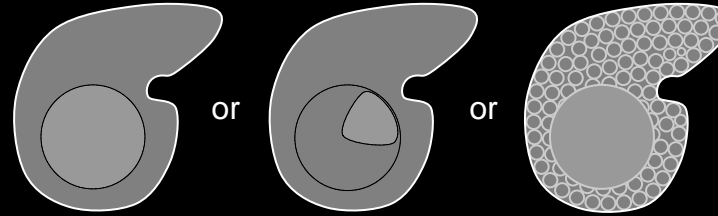
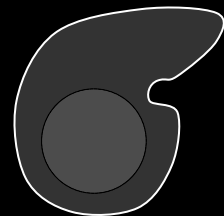
- Applies only to enhancing observations that, in whole or in part, unequivocally are lower in attenuation or intensity than liver in the delayed phase.
- Does not apply to non-enhancing observations.
- The attenuation or intensity of the observation should be compared to that of the adjacent liver parenchyma. If the liver parenchyma visually consists of both nodules and fibrosis, then attenuation or intensity of the observation should be compared to that of the composite liver tissue (i.e., a visual average of the nodules and fibrosis) (see schematics on left).
- The degree of arterial phase and portal venous phase enhancement is not relevant for characterization of this imaging feature.
- Delayed phase hypo-enhancement is part of the definition of [washout appearance](#).
- Washout appearance is a LI-RADS major feature. It is defined as a temporal reduction in enhancement relative to liver from an earlier to a later phase, resulting in [portal venous phase hypo-enhancement](#) or delayed phase hypo-enhancement.

**Atlas:** CT, MR

Pre      Arterial      Portal Venous      Delayed



At least part of observation is hypo-enhanced



No part of observation is hypo-enhanced

Delayed phase hypo-enhancement

Not delayed phase hypo-enhancement

**Delayed phase hypo-enhancement:** Schematic diagrams illustrate observations with (top row) and without (bottom row) delayed phase hypo-enhancement. Observations with delayed phase hypo-enhancement are enhancing observations that, in whole or in part, unequivocally are lower in attenuation or intensity than liver in the delayed phase, regardless of degree of enhancement in arterial or portal venous phase. Observations may be hypo- ([click here](#)), iso- ([click here](#)), or hyper- (this slide) attenuating/intense pre-contrast. If the liver parenchyma visually consists of both nodules and fibrosis (first row, delayed phase, right-most liver), then enhancement of the observation should be compared to that of the composite liver tissue.

**Designation:**

A categorical score (A, B, Treated) assigned to LR4 or 5 [observations](#) or to treated LR5 observations and biopsy-proven HCC lesions as follows:

- The designations A and B are assigned to LR4 or 5 observations based on their [diameter](#). LR4 or 5 observations < 20mm are designated A. LR4 or 5 observations  $\geq$  20mm are designated B.
- The designation Treated is assigned to LR5 observations or biopsy-proven HCC lesions that have undergone loco-regional [treatment](#).





## Diagnostic:

Demonstrating features that are so characteristic of the entity that there is close to 100% likelihood that the finding represents the entity.

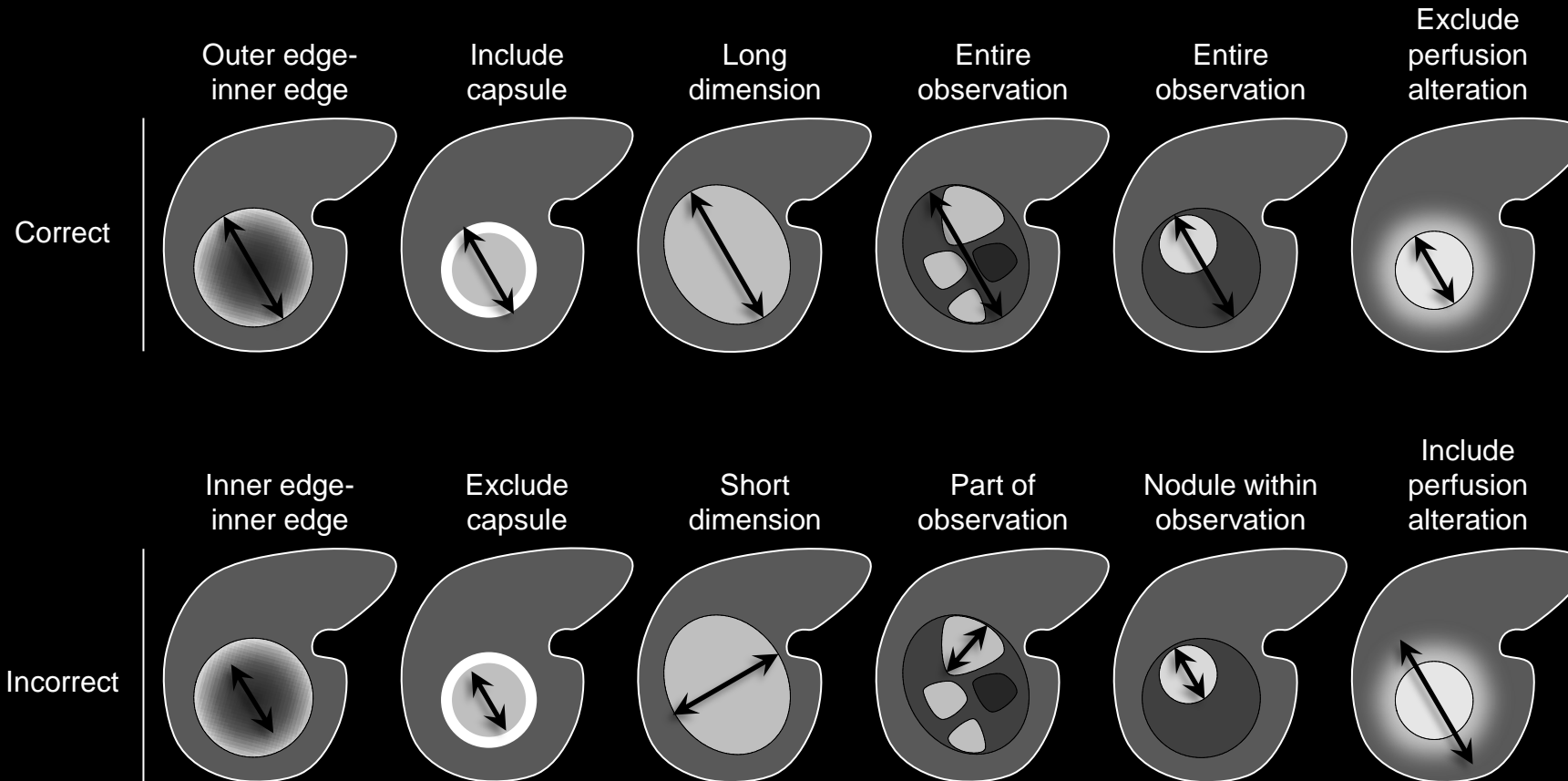


## Diameter:

The largest dimension (outer edge to outer edge) of an observation.

## Comments:

- Diameter should be measured in the sequence, phase, and imaging plane in which the margins are most sharply demarcated and in which there is no anatomic distortion. If margins are sharply demarcated on more than one sequence or phase, do not measure in the arterial phase.
- Rationale:** apparent diameter in the arterial phase is variable, depending on exact timing of image acquisition. Also, perilesional enhancement in the arterial phase might be misconstrued as part of hyper-enhancing mass.
- If a mass is surrounded by or is contiguous with a perfusion alteration, do not include the perfusion alteration in the measurement.
- For masses with nodule-in-nodule or multi-nodule-in-nodule architecture, include the entire mass in the measurement, not just the internal nodule(s).



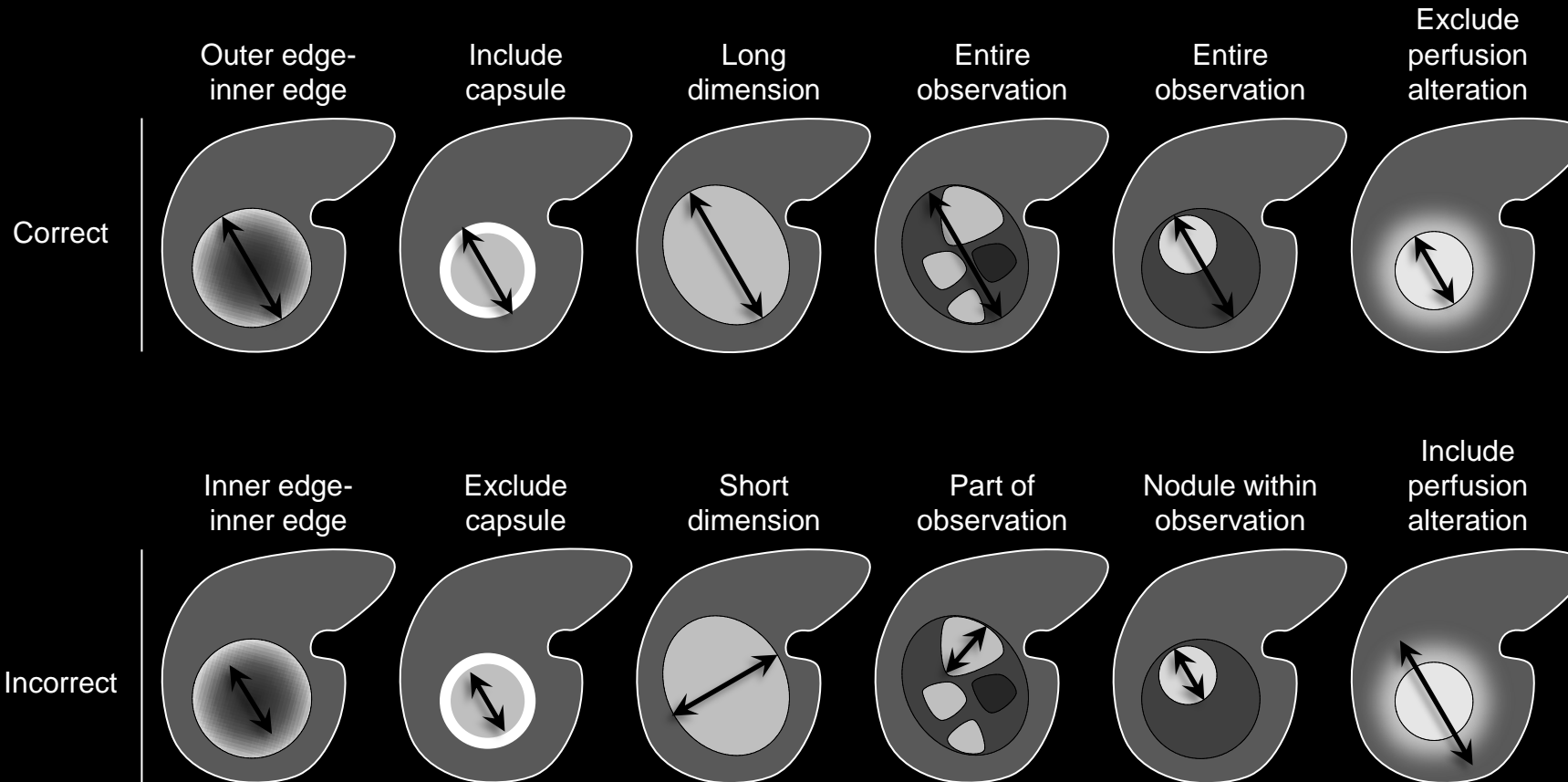
**Diameter:** Schematic diagrams depict correct (top row) and incorrect (bottom row) diameter measurements. As shown in schematics, diameter should be measured from outer edge to outer (first column), including capsule (second column), and along longest dimension (third column) of entire (fourth and fifth columns) observation. Perfusion alterations surrounding the observation (sixth column) should not be included in the measurement.



## Diameter:

### Comments (continued):

- One key diameter threshold is  $< 20\text{mm}$  vs.  $\geq 20\text{mm}$ . In conjunction with other [major features](#), this threshold is used to [categorize](#) as LR3, LR4, or LR5 masses that are neither [definite benign entities](#) nor [probable benign entities](#) and that lack features of [non-HCC malignancy](#) or [tumor in vein](#). This threshold is also used to [designate](#) LR4 and LR5 observations as A or B.
- **Rationale:** compared to  $\geq 20\text{mm}$  observations,  $< 20\text{mm}$  observations are less likely to be HCC and more difficult to characterize at CT and MRI, and hence they must satisfy stricter criteria to be assigned an equivalent LR category.



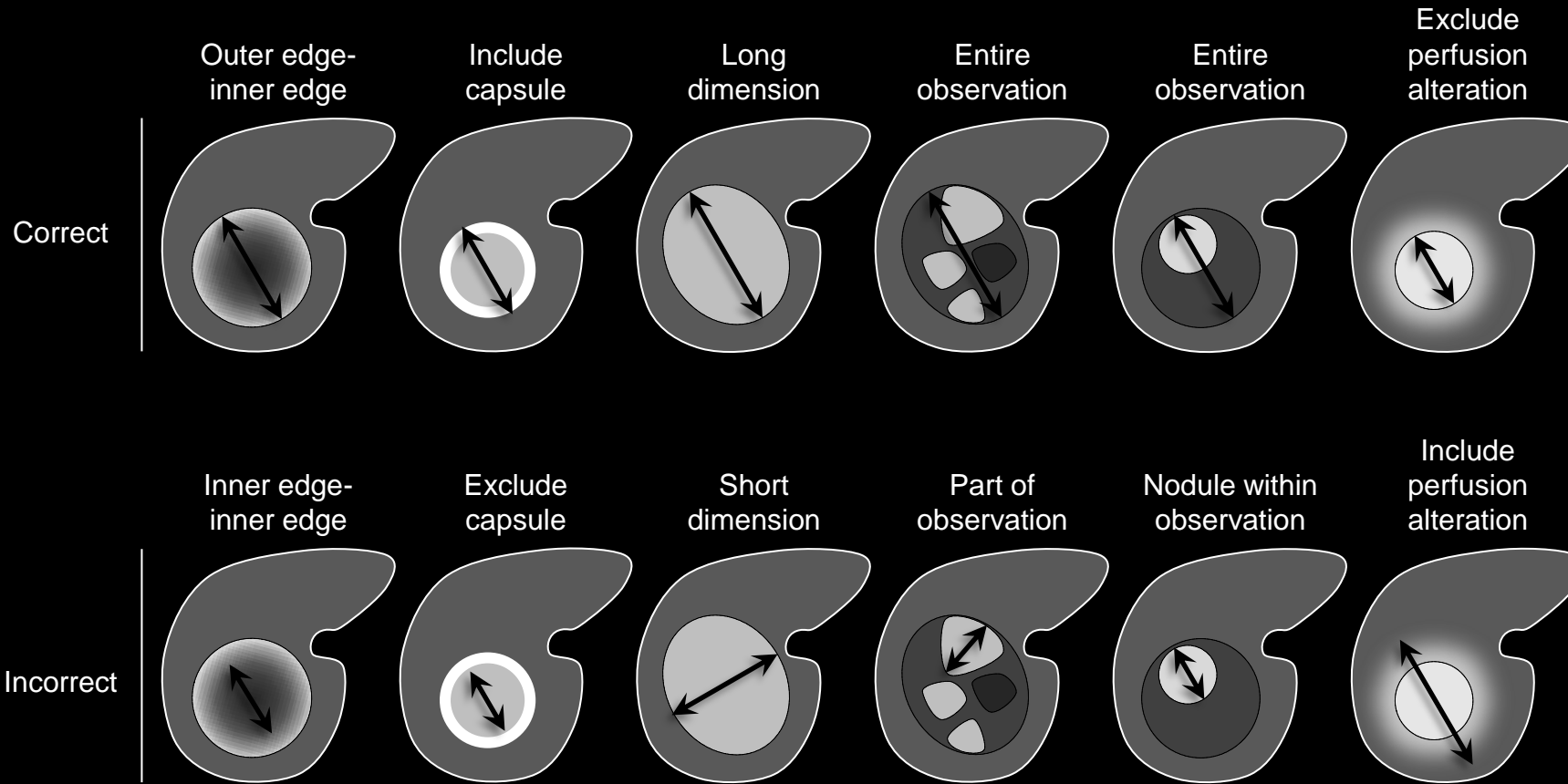
**Diameter:** Schematic diagrams depict correct (top row) and incorrect (bottom row) diameter measurements. As shown in schematics, diameter should be measured from outer edge to outer (first column), including capsule (second column), and along longest dimension (third column) of entire (fourth and fifth columns) observation. Perfusion alterations surrounding the observation (sixth column) should not be included in the measurement.



## Diameter:

### Comments (continued):

- For masses with [arterial phase hyper-enhancement](#), another key diameter threshold is [< 10mm](#) vs. [10-19mm](#). Masses < 10mm cannot be categorized LR5, regardless of other major features. [10-19mm](#) masses with [arterial phase hyper-enhancement](#) can be categorized LR5A if [LR5A criteria](#) are met.
- Rationale:** compared to [10-19mm](#) masses, [≤ 10mm](#) masses are less likely to be HCC, more difficult to characterize at CT and MRI and, if resection/explantation is performed, more difficult to co-localize on imaging and pathology. Hence, [≤ 10mm](#) masses cannot be diagnosed at CT or MRI with 100% certainty as HCC and therefore cannot be categorized [LR5](#). Categorizing HCC <10 mm as LR4 is not likely to adversely affect outcome. Close follow-up will allow LR5A categorization once diameter exceeds 10 mm.
- This also maintains congruency with OPTN classification, which does not allow <10mm masses to be classified OPTN 5.



**Diameter:** Schematic diagrams depict correct (top row) and incorrect (bottom row) diameter measurements. As shown in schematics, diameter should be measured from outer edge to outer (first column), including capsule (second column), and along longest dimension (third column) of entire (fourth and fifth columns) observation. Perfusion alterations surrounding the observation (sixth column) should not be included in the measurement.



**Diameter < 10mm:**

The largest [diameter](#) (outer edge to outer edge) of an observation is < 10mm.

**Comments:**

- Diameter < 10mm is a [major feature](#) for categorization of masses with arterial phase hyper-enhancement.
- Masses with diameter < 10mm and arterial phase hyper-enhancement may be categorized [LR3](#) or [LR4A](#) depending on other features. As shown in [Table](#), such masses cannot be categorized [LR5](#).
  - **Rationale:** < 10mm masses are unlikely to be HCC, difficult to characterize at CT and MRI and, if resection/explantation is performed, difficult to co-localize on imaging and pathology. Hence, < 10mm masses cannot be diagnosed at CT or MRI with 100% certainty as HCC. Categorizing HCC < 10 mm as LR3 or LR4 is not likely to adversely affect outcome. Close follow-up will allow LR5A categorization once diameter exceeds 10 mm.
- This also maintains congruency with OPTN classification, which does not allow <10mm masses to be classified OPTN 5.

**Diameter < 10mm:****Comments (continued):**

- Diameter should be measured in the sequence or phase in which the margins are most sharply demarcated and in which there is no anatomic distortion. If margins are sharply demarcated on more than one sequence or phase, do not measure in the arterial phase.
- **Rationale:** apparent diameter in the arterial phase is variable, depending on exact timing of image acquisition. Also, perilesional enhancement in the arterial phase might be misconstrued as part of hyper-enhancing mass.

**Diameter 10-19mm:**

The largest [diameter](#) (outer edge to outer edge) of an observation is  $\geq 10$  mm and  $\leq 19$ mm.

**Comments:**

- Diameter 10-19mm is a [major feature](#) for categorization of masses with arterial phase hyper-enhancement.
- Masses with diameter 10-19mm and arterial phase hyper-enhancement may be categorized LR3, LR4A, or LR5A depending on other features.
- Diameter should be measured in the sequence or phase in which the margins are most sharply demarcated and in which there is no anatomic distortion. If margins are sharply demarcated on more than one sequence or phase, do not measure in the arterial phase.
- **Rationale:** apparent diameter in the arterial phase is variable, depending on exact timing of image acquisition. Also, perilesional enhancement in the arterial phase might be misconstrued as part of hyper-enhancing mass.

**Diameter < 20mm:**

The largest [diameter](#) (outer edge to outer edge) of an observation is < 20mm.

**Comments:**

- Diameter < 20mm is a [major feature](#) for categorization of masses with arterial phase hypo- or iso-enhancement.
- Masses with diameter < 20 mm and arterial phase hypo- and iso-enhancement may be categorized LR3 or LR4A depending on other features. As shown in [Table](#), such masses cannot be categorized LR5.
- Diameter should be measured in the sequence or phase in which the margins are most sharply demarcated and in which there is no anatomic distortion. If margins are sharply demarcated on more than one sequence or phase, do not measure in the arterial phase.
- **Rationale:** apparent diameter in the arterial phase is variable, depending on exact timing of image acquisition. Also, perilesional enhancement in the arterial phase might be misconstrued as part of hyper-enhancing mass.



**Diameter  $\geq$  20mm:**

The largest [diameter](#) (outer edge to outer edge) of an observation is  $\geq$  20mm.

**Comments:**

- Diameter  $\geq$  20mm is a [major feature](#) for categorization of masses.
- Masses with diameter  $\geq$  20 mm may be categorized LR3, LR4B, or LR5B depending on arterial phase enhancement and other features. As shown in [Table](#), such masses can be categorized LR5B only if they have arterial phase hyper-enhancement.
- Diameter should be measured in the sequence or phase in which the margins are most sharply demarcated and in which there is no anatomic distortion. If margins are sharply demarcated on more than one sequence or phase, do not measure in the arterial phase.
- **Rationale:** apparent diameter in the arterial phase is variable, depending on exact timing of image acquisition. Also, perilesional enhancement in the arterial phase might be misconstrued as part of hyper-enhancing mass.

**Diameter increase:**

[Unequivocal](#) increase in the [diameter](#) of an observation, measured on examinations performed on different dates, which is not attributable to artifact, differences in technique between the two examinations, or measurement error.

**Comments:**

- A diameter increase of  $\geq 50\%$  over  $\leq 6$  months or  $\geq 100\%$  over  $> 6$  months is considered [threshold growth](#), which is a [major feature](#) of HCC.
- A diameter increase less than [threshold growth](#) is an [ancillary feature](#) that favors HCC. LI-RADS does not stipulate a minimum increase in diameter required for use as an ancillary feature.
- Radiologists at their discretion may apply diameter increase less than threshold growth to upgrade category (up to LR4).
- Radiologists should exercise judgment in the application of this feature, which applies only to an unequivocal increase in the diameter of an observation.
- Diameter increase should be assessed on images in the same plane and, if possible, acquired in the same phase or sequence.

**Atlas:** CT, MR



## Diameter reduction

[Unequivocal](#) decrease in the [diameter](#) of an [observation](#), measured on examinations performed on different dates and in the absence of treatment, which is not attributable to artifact, differences in technique between the two examinations, or measurement error.

### Comments:

- Applies to [masses](#) that unequivocally become smaller in absence of treatment (i.e., spontaneously).
- Diameter reduction in the absence of [treatment](#) is an [ancillary feature](#) that favors benignity. LI-RADS does not stipulate a minimum reduction in diameter required for use as an ancillary feature.
- Radiologists at their discretion may apply diameter reduction to downgrade category.
- Radiologists should exercise judgment in the application of this feature, which applies only to an unequivocal decrease in the diameter of an observation.
- Diameter reduction should be assessed on images in the same plane and, if possible, acquired in the same phase or sequence.
- After [treatment](#), diameter reduction should not be used as an [ancillary feature](#) favoring benignity.

**Atlas:** CT, MR



## Diameter stability

No significant change in [diameter](#) of an [observation](#), measured on examinations performed on different dates and in the absence of treatment.

### Comments:

- Applies to observations with
  - No measurable change in diameter or
  - A change in diameter so small that the change is attributable to artifact, differences in imaging technique, or measurement error.
- Diameter stability  $\geq 2$  years in the absence of [treatment](#) is an [ancillary feature](#) that favors benignity.
- Radiologists at their discretion may apply diameter stability  $\geq 2$  years to downgrade category.
- Diameter stability should be assessed on images in the same plane and, if possible, acquired in the same phase or sequence.
- After treatment, diameter stability should not be used as an ancillary feature favoring benignity.

**Atlas:** CT, MR





## Diffuse:

Distributed over a large area, such as over an entire liver, lobe, or segment, or over an entire [observation](#). Opposite of [focal](#).

**Atlas:** CT, MR

**Disappearance:**

Complete and [unequivocal](#) resolution of an [observation](#) present on a prior study.

**Spontaneous disappearance:**

Disappearance in absence of [treatment](#).

**Comments:**

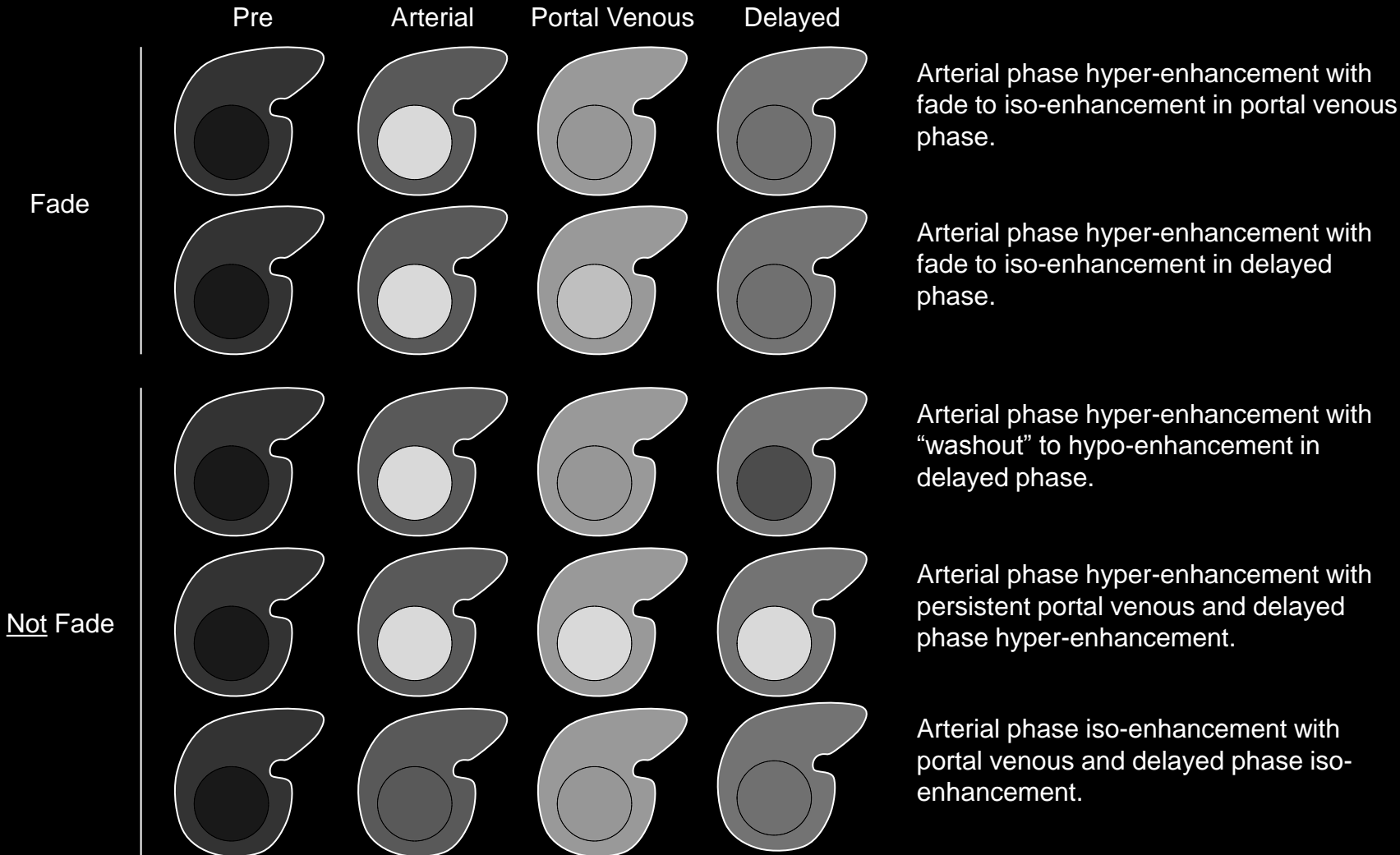
- Observations that disappear spontaneously should be categorized LR1 regardless of prior category.
- The reporting of such observations depends on the prior LI-RADS category:
  - If previously categorized LR4 or LR5: should be reported.
  - If previously categorized LR1, LR2, or LR3: may be reported at radiologist's discretion.

**Atlas:** CT, MR



## **Equivocal:**

Of uncertain, classification, characterization, or interpretation.



**Fade:** Schematic diagrams illustrate arterial phase hyper-enhancing observations with (top two rows) and without (bottom two rows) fade temporal pattern. Observations that fade become iso-enhanced to liver in the portal venous (first row) or delayed phase (second row). Shown for comparison are three non-fade patterns: arterial phase hyper-enhancement with "washout" (third row), arterial phase hyper-enhancement with delayed hyper-enhancement (fourth row), and arterial phase iso-enhancement with portal venous and delayed phase iso-enhancement (fifth row).

## Fade

Temporal reduction in enhancement from [hyper-enhancement](#) in the [arterial phase](#) to [iso-enhancement](#) or faint residual hyper-enhancement in later phases.

### Comments:

- Applies to observations that, relative to liver, are hyper-enhanced in the arterial phase and
  - Iso-enhanced in [portal venous phase](#) and [delayed phase](#) OR
  - Have faint residual hyper-enhancement in the portal venous phase and iso-enhancement in the delayed phase OR
  - Have faint residual hyper-enhancement in both the portal venous and the delayed phase.
- Does not apply to observations that are iso- or hypo-enhanced relative to liver in the arterial phase, even if iso-enhanced in the portal venous phase or delayed phase.
- In the cirrhotic liver, this pattern favors neither benignity nor HCC, and additional features should be evaluated to determine the appropriate LI-RADS category.
  - Rationale: this pattern may be observed with perfusion alterations (e.g., arterio-portal shunts), some small hemangiomas (more frequently at CT than MRI), FNH-like lesions, some dysplastic nodules, and some small HCCs.

**Atlas:** [CT](#), [MR](#)



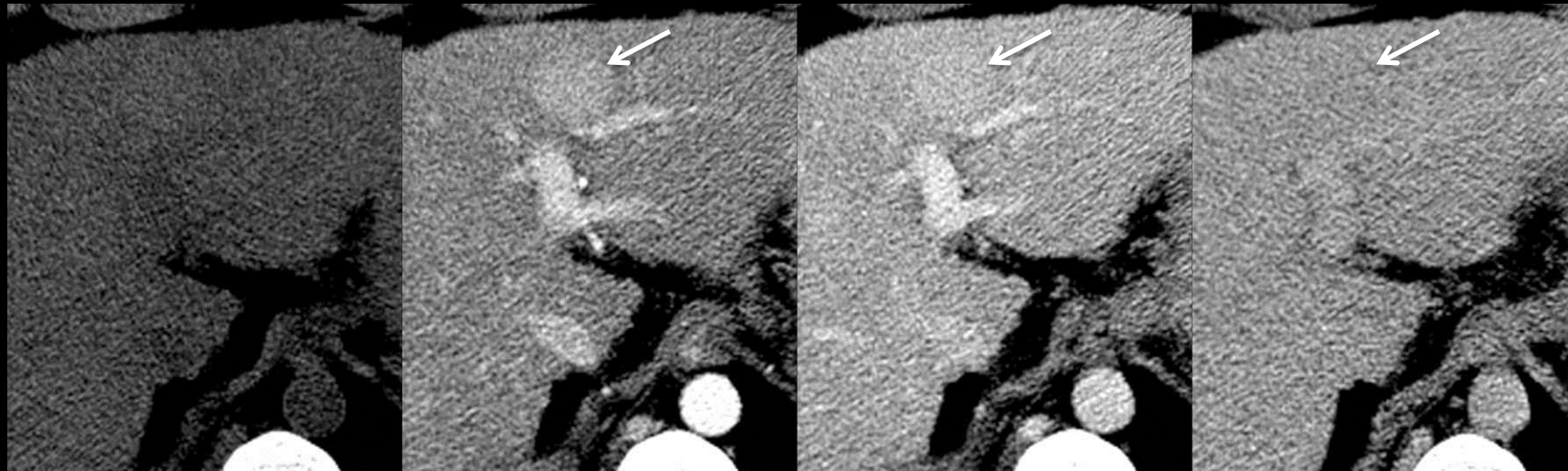


Pre

Arterial

Portal Venous

Delayed



**Fade (CT):** Figure collage shows arterial phase hyper-enhancing mass at CT with faint residual hyper-enhancement in portal venous phase and iso-enhancement in delayed phase (fade pattern).

## Fade

Temporal reduction in enhancement from [hyper-enhancement](#) in the [arterial phase](#) to [iso-enhancement](#) or faint residual hyper-enhancement in later phases.

### Comments:

- Applies to observations that, relative to liver, are hyper-enhanced in the arterial phase and
  - Iso-enhanced in [portal venous phase](#) and [delayed phase](#) OR
  - Have faint residual hyper-enhancement in the portal venous phase and iso-enhancement in the delayed phase OR
  - Have faint residual hyper-enhancement in both the portal venous and the delayed phase.
- Does not apply to observations that are iso- or hypo-enhanced relative to liver in the arterial phase, even if iso-enhanced in the portal venous phase or delayed phase.
- In the cirrhotic liver, this pattern favors neither benignity nor HCC, and additional features should be evaluated to determine the appropriate LI-RADS category.
  - Rationale: this pattern may be observed with perfusion alterations (e.g., arterio-portal shunts), some small hemangiomas (more frequently at CT than MRI), FNH-like lesions, some dysplastic nodules, and some small HCCs.

**Atlas:** MR, [Schematic](#)



## LI-RADS Features

Major	Ancillary for HCC	Ancillary for Benignity
<ul style="list-style-type: none"> <li>Arterial phase features                             <ul style="list-style-type: none"> <li>Arterial phase hypo- or iso-enhancement</li> <li>Arterial phase hyper-enhancement</li> </ul> </li> <li>Diameter                             <ul style="list-style-type: none"> <li>For arterial phase hypo- or iso-enhancing masses:                                     <ul style="list-style-type: none"> <li>Diameter &lt; 20mm</li> <li>Diameter ≥ 20 mm</li> </ul> </li> <li>For arterial phase hyper-enhancing masses:                                     <ul style="list-style-type: none"> <li>Diameter &lt; 10mm</li> <li>Diameter 10-19mm</li> <li>Diameter ≥ 20 mm</li> </ul> </li> </ul> </li> <li>Washout appearance</li> <li>Capsule appearance</li> <li>Threshold growth</li> </ul>	<ul style="list-style-type: none"> <li>Mild-moderate T2 hyper-intensity</li> <li>Restricted diffusion</li> <li>Corona enhancement</li> <li>Mosaic architecture</li> <li>Nodule-in-nodule architecture</li> <li>Intra-lesional fat</li> <li>Lesional iron sparing</li> <li>Lesional fat sparing</li> <li>Blood products</li> <li>Diameter increase less than threshold growth</li> </ul>	<ul style="list-style-type: none"> <li>Homogeneous marked T2 hyper-intensity</li> <li>Homogeneous marked T2 or T2* hypo-intensity</li> <li>Undistorted vessels traversing observation</li> <li>Parallels blood pool enhancement</li> <li>Diameter reduction</li> <li>Diameter stability ≥ 2 years</li> </ul>

### Feature:

Prominent or conspicuous part or characteristic. In LI-RADS, refers to imaging characteristics used in [categorization](#) of [observations](#).

### Comments:

- Major features:** Imaging features used to categorize as [LR3](#), [LR4](#), or [LR5](#) masses masses that are neither [definite benign entities](#) nor [probable benign entities](#) and that lack features of [non-HCC malignancy](#) or [tumor in vein](#). See [Table](#) to review the use of major features to categorize such masses.
- Ancillary features:** Imaging features that modify likelihood of HCC. In isolation, these features do not permit reliable categorization of observations and hence are considered ancillary. Ancillary features are subdivided into those that may favor HCC and those that may favor benignity. Radiologists at their discretion may apply ancillary features that may favor HCC to upgrade category (up to LR4) and ancillary features that favor benignity to downgrade category. To maintain congruency with OPTN, ancillary features cannot be applied to upgrade category to LR5. Click [here](#) to review the application of ancillary features for upgrading and downgrading categories.
- Major and ancillary features are summarized in table on left.

**Features:** Table lists LI-RADS major features, ancillary features that may favor HCC, and ancillary features that may favor benignity.



## Focal:

Limited to a small area or volume. Is the opposite of [diffuse](#).

**Focal scar:**

Macroscopically visible [scar](#) limited to a small area or volume of the hepatic parenchyma.

**LI-RADS Categorization:**

- Observations thought to [definitely](#) represent focal scars should be categorized LR1.
- Observations thought to [probably](#) represent focal scars should be categorized LR2.
- Observations that are indeterminate for focal scars versus HCC should be categorized LR3 or LR4.

[Imaging Manifestations](#)[Pitfalls, Challenges, Differential Diagnosis](#)

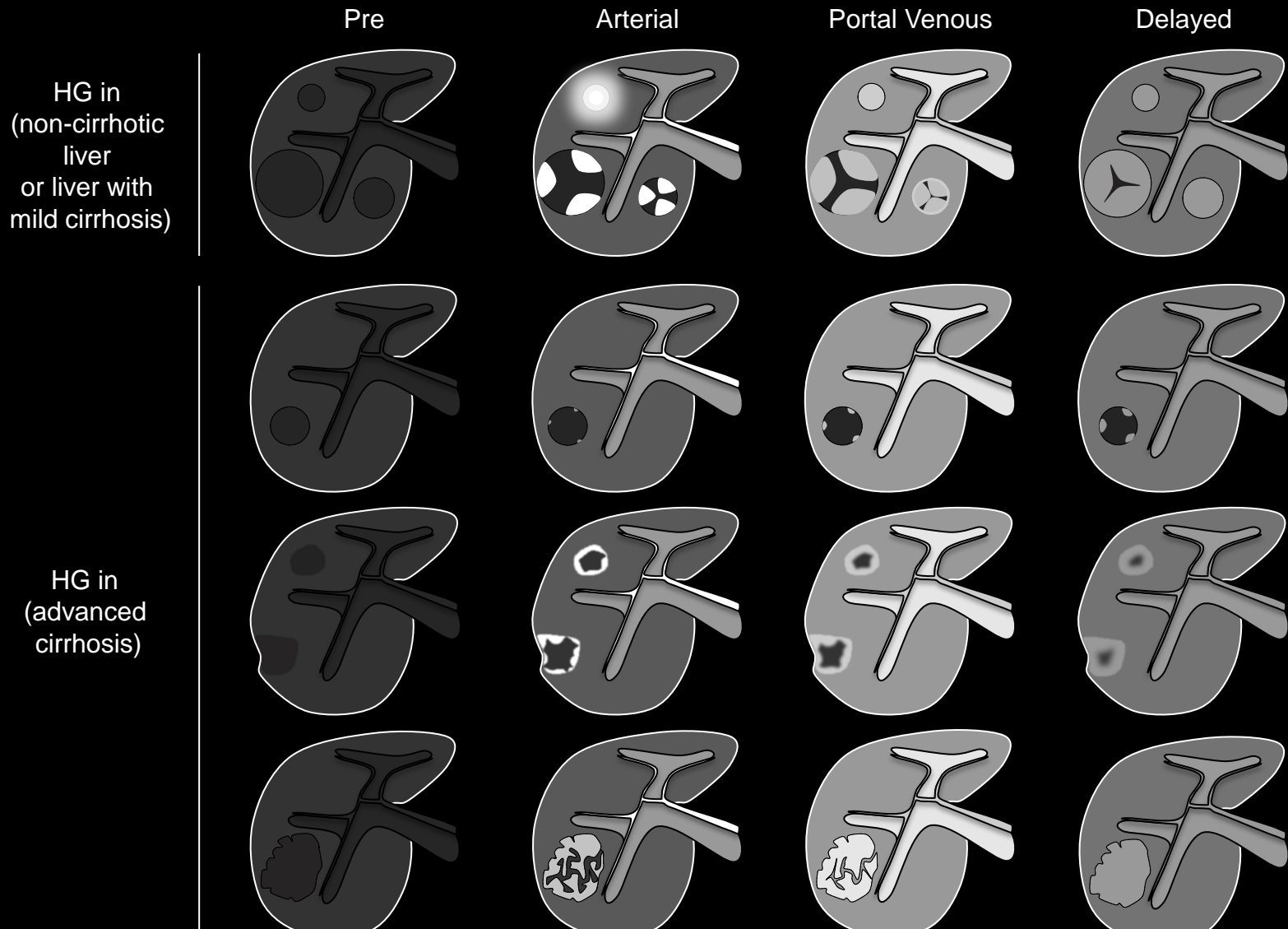
**Focal scar:****Imaging Manifestations:**

- Focal scars **typically** have the following features:
  - Small
  - Linear, band-like or wedge-like in shape
  - Peripherally located
  - Associated with focal, mild liver surface retraction
  - Unenhanced CT
    - Hypo-attenuating
  - Unenhanced MRI
    - T1 hypo-intense
    - T2 hyper-intense
    - DW hyper-intense (due at least in part to T2 shine-through).
  - [Hypo- or iso-enhancing in the arterial phase](#)
  - [Increasing enhancement](#) in portal venous and delayed phases (if extra-cellular contrast agent is administered).
- Multiplanar images may help to depict the characteristic linear, band-like, or wedge-like shape.



**Focal scar:****Pitfalls, Challenges, Differential Diagnosis:**

- While focal scars typically are arterial phase hypo- or iso-enhancing, they may be arterial phase hyper-enhancing. Characteristic morphology and location usually permit correct interpretation and appropriate LI-RADS categorization as, depending on level of confidence, LR1 or LR2.



**Hemangioma:** Schematic diagrams illustrate classical enhancement patterns of hemangiomas in non-cirrhotic liver or liver with mild cirrhosis (top row) and non-classical enhancement patterns of hemangiomas that may be observed in liver with advanced cirrhosis (bottom 3 rows).

## Hemangioma:

Common benign tumor consisting of vascular channels lined by endothelial cells.

### LI-RADS Categorization:

- Observations thought to **definitely** represent hemangiomas should be categorized LR1.
- Observations thought to **probably** represent hemangiomas should be categorized LR2.
- Observations that are indeterminate for hemangiomas versus HCC should be categorized LR3 or LR4.

### [Imaging Manifestations](#)

### [Pitfalls, Challenges, Differential Diagnosis](#)

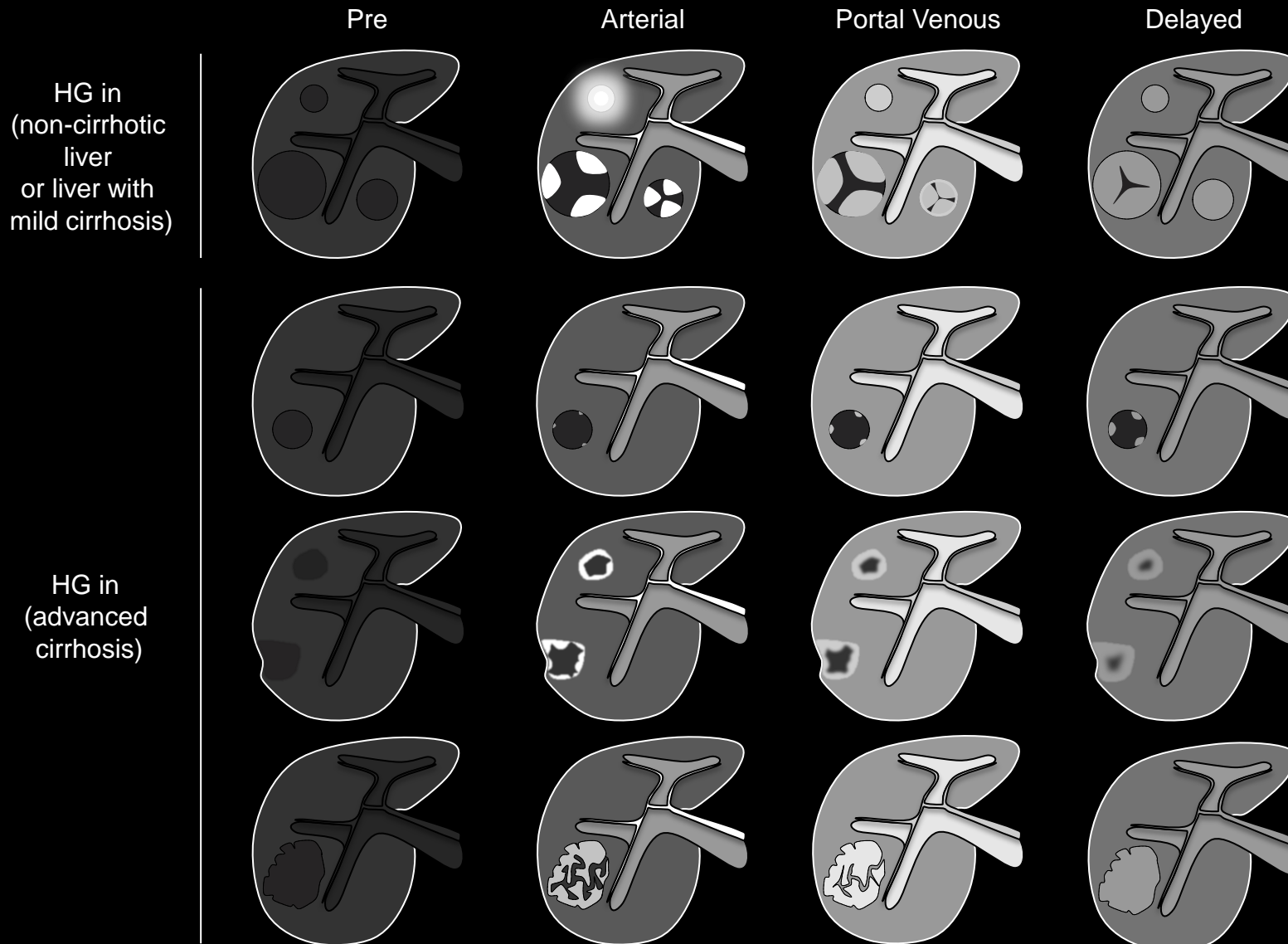
### [Other Comments](#)



## Hemangioma:

### Imaging Manifestations:

- Hemangiomas in patients with mild or early cirrhosis may have typical imaging features:
  - Peripherally discontinuous nodule-like expanding enhancement or rapid enhancement that in its intensity [parallels blood pool enhancement](#).
  - Sharply circumscribed
  - Round, oval, or lobulated
  - Unenhanced CT
    - Hypo-attenuating
  - Unenhanced MRI
    - T1 hypo-intense
    - T2 markedly hyper-intense
    - DW hyper-intense (due at least in part to T2 shine-through).




**Hemangioma:** Schematic diagrams illustrate classical enhancement patterns of hemangiomas in non-cirrhotic liver or liver with mild cirrhosis (top row) and non-classical enhancement patterns of hemangiomas that may be observed in liver with advanced cirrhosis (bottom 3 rows).



## Hemangioma:

### Pitfalls, Challenges, Differential Diagnosis:

- With progressive cirrhosis, hemangiomas tend to become smaller and more fibrotic (sclerotic), and as a result they may not have the classic diagnostic appearance often seen in the non-cirrhotic liver. Instead, they may have the following features:
  - Involution and diameter reduction over time
  - Retraction of overlying liver surface
  - Rim-like enhancement
  - Small puddles with slow or incomplete filling
  - Enhancement less than that of blood pool
  - Ill-defined rather than sharply circumscribed and distinctly lobulated
  - T2w MRI:
    - Mild-moderate rather than marked T2 hyper-intensity
    - Heterogeneous T2 hyper-intensity corresponding to areas of variable intra-lesional fibrosis
- Radiologists should be aware that in patients with advanced cirrhosis hemangiomas may be difficult to diagnose confidently at CT and MRI. Comparison to prior studies when cirrhosis was less advanced may be helpful, as the hemangioma may have had more characteristic features previously. Another important diagnostic clue is [diameter stability](#) or [diameter reduction](#) over time.



**Hemangioma:** Schematic diagrams illustrate classical enhancement patterns of hemangiomas in non-cirrhotic liver or liver with mild cirrhosis (top row) and non-classical enhancement patterns of hemangiomas that may be observed in liver with advanced cirrhosis (bottom 3 rows).

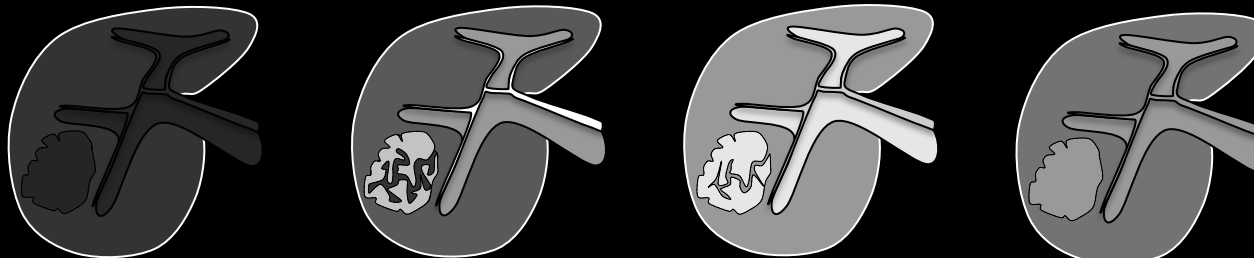
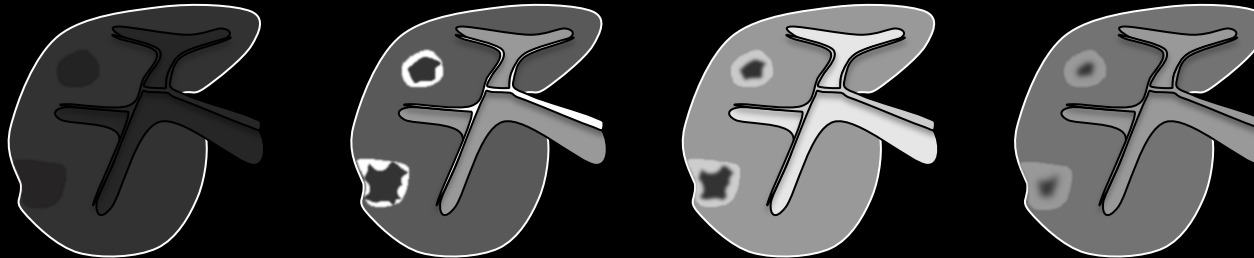
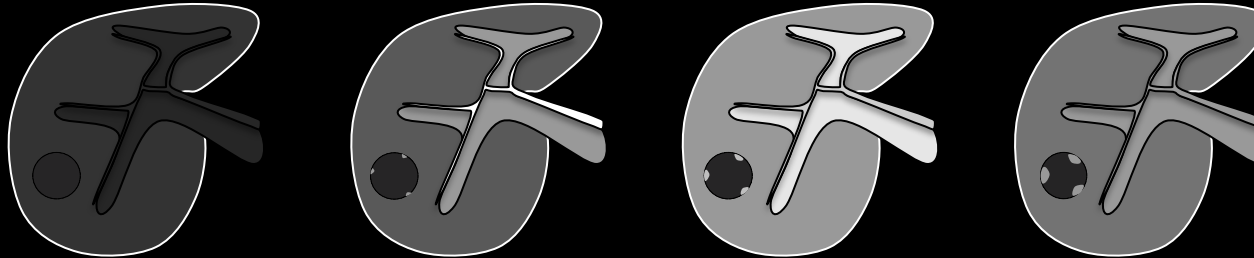
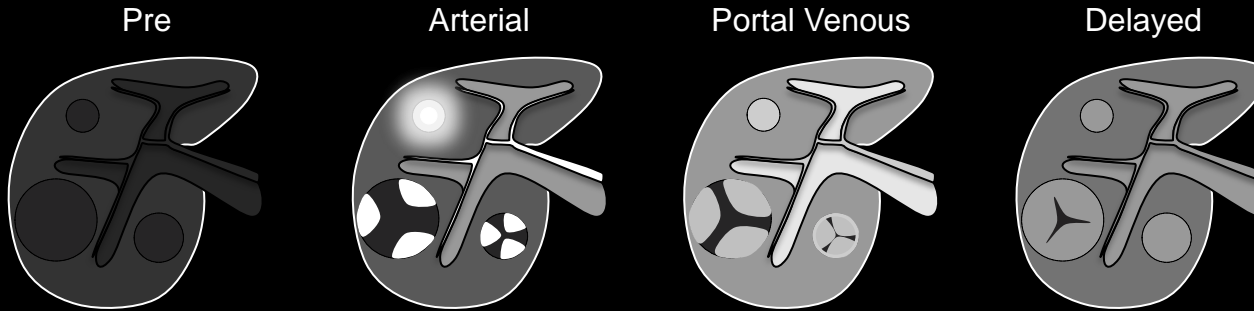


## Hemangioma:

### Other Comments:

- Hemangiomas are seen less frequently in the cirrhotic than in the non-cirrhotic liver.

HG in  
(non-cirrhotic  
liver  
or liver with  
mild cirrhosis)



HG in  
(advanced  
cirrhosis)

**Hemangioma:** Schematic diagrams illustrate classical enhancement patterns of hemangiomas in non-cirrhotic liver or liver with mild cirrhosis (top row) and non-classical enhancement patterns of hemangiomas that may be observed in liver with advanced cirrhosis (bottom 3 rows).



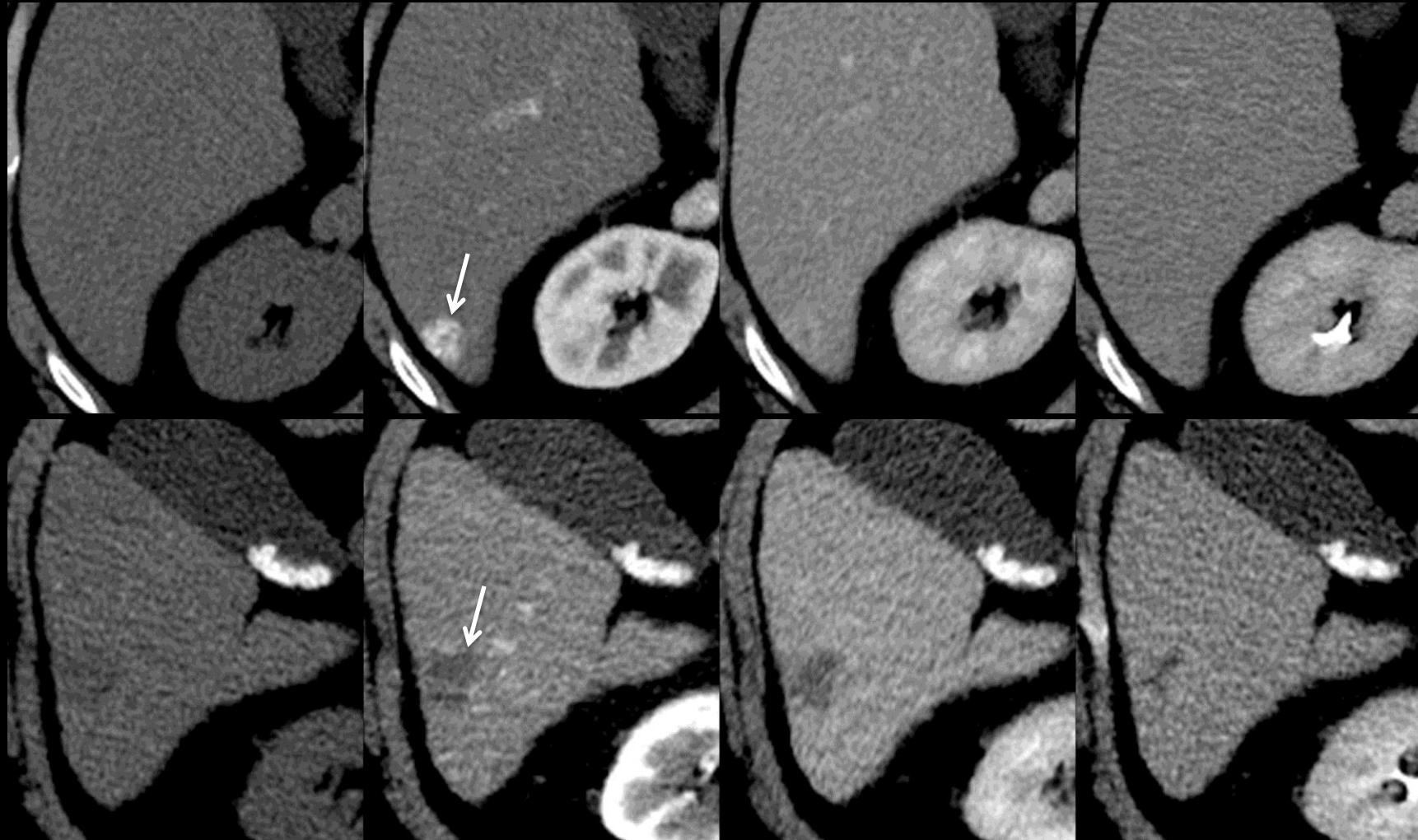


Pre

Arterial

Portal Venous

Delayed



**Hemangioma in cirrhosis (CT):** Figures show 16mm ring-enhancing hemangioma (top row) and 22mm sclerosing hemangioma (bottom row) in two patients with cirrhosis. As shown in these figures, hemangiomas in patients with cirrhosis may have non-classical imaging appearances.

## Hemangioma:

Common benign tumor consisting of vascular channels lined by endothelial cells.

### LI-RADS Categorization:

- Observations thought to [definitely](#) represent hemangiomas should be categorized LR1.
- Observations thought to [probably](#) represent hemangiomas should be categorized LR2.
- Observations that are indeterminate for hemangiomas versus HCC should be categorized LR3 or LR4.

### [Imaging Manifestations](#)

### [Pitfalls, Challenges, Differential Diagnosis](#)

### [Other Comments](#)

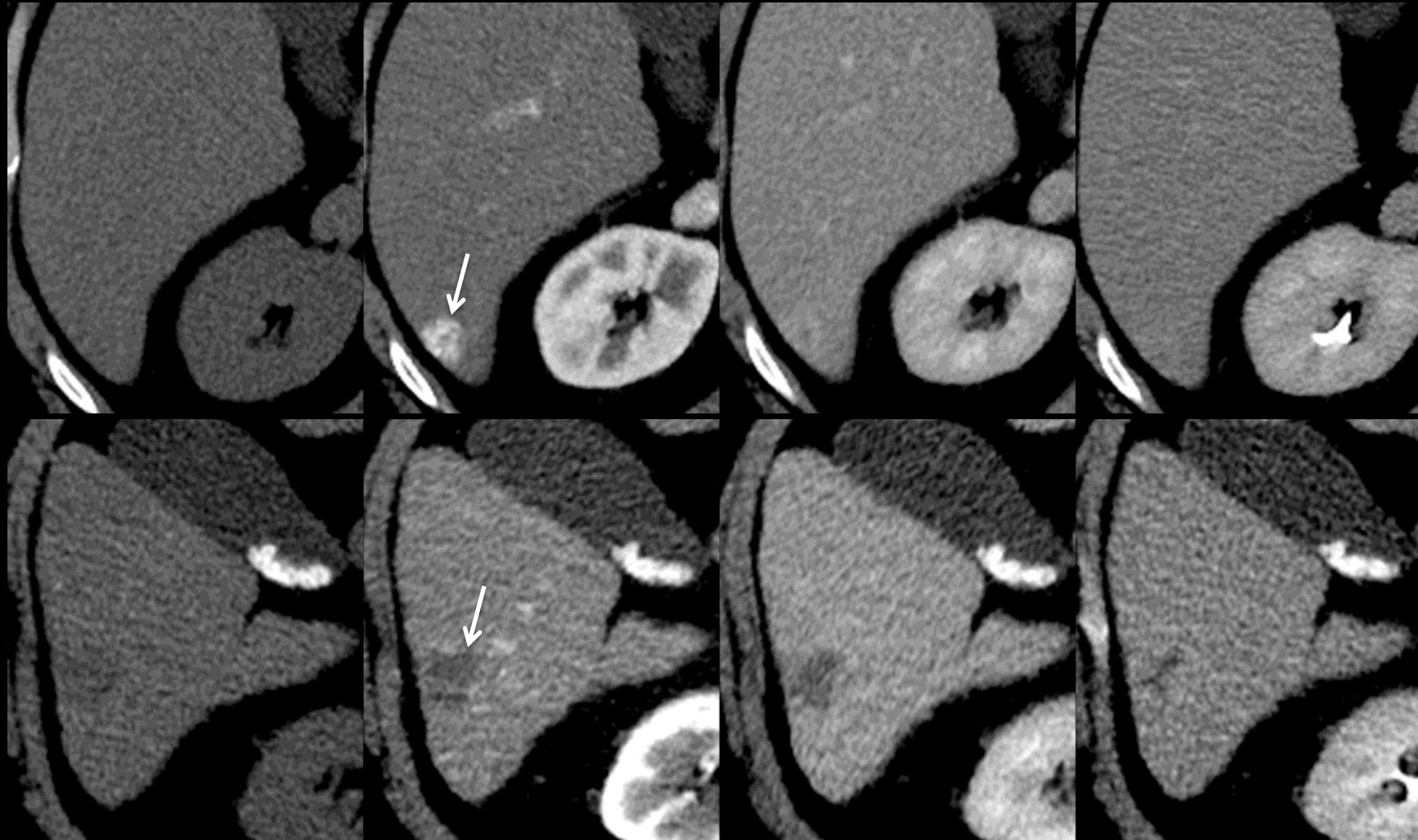


Pre

Arterial

Portal Venous

Delayed



**Hemangioma in cirrhosis (CT):** Figures show 16mm ring-enhancing hemangioma (top row) and 22mm sclerosing hemangioma (bottom row) in two patients with cirrhosis. As shown in these figures, hemangiomas in patients with cirrhosis may have non-classical imaging appearances.

## Hemangioma:

### Imaging Manifestations:

- Hemangiomas in patients with mild or early cirrhosis may have typical imaging features:
  - Peripheral discontinuous nodule-like expanding enhancement or rapid enhancement that in its intensity [parallels blood pool enhancement](#).
  - Sharply circumscribed
  - Round, oval, or lobulated
  - Unenhanced CT
    - Hypo-attenuating
  - Unenhanced MRI
    - T1 hypo-intense
    - T2 markedly hyper-intense
    - DW hyper-intense (due at least in part to T2 shine-through).



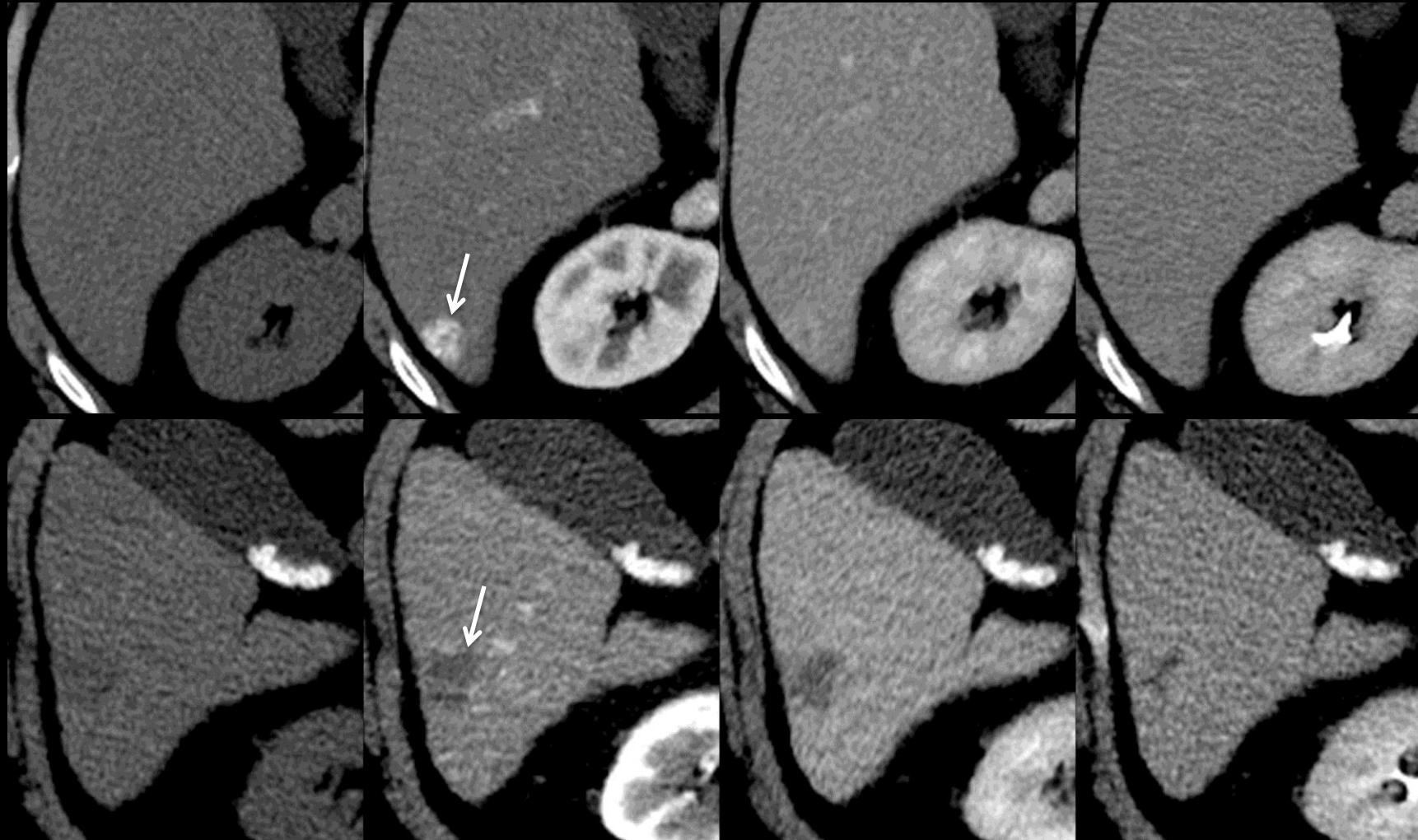


Pre

Arterial

Portal Venous

Delayed



**Hemangioma in cirrhosis (CT):** Figures show 16mm ring-enhancing hemangioma (top row) and 22mm sclerosing hemangioma (bottom row) in two patients with cirrhosis. As shown in these figures, hemangiomas in patients with cirrhosis may have non-classical imaging appearances.

## Hemangioma:

### Pitfalls, Challenges, Differential Diagnosis:

- With progressive cirrhosis, hemangiomas tend to become smaller and more fibrotic (sclerotic), and as a result they may not have the classic diagnostic appearance often seen in the non-cirrhotic liver. Instead, they may have the following features:
  - Involution and diameter reduction over time
  - Retraction of overlying liver surface
  - Rim-like enhancement
  - Small puddles with slow or incomplete filling
  - Enhancement less than that of blood pool
  - Ill-defined rather than sharply circumscribed and distinctly lobulated
  - T2w MRI:
    - Mild-moderate rather than marked T2 hyper-intensity
    - Heterogeneous T2 hyper-intensity corresponding to areas of variable intra-lesional fibrosis
- Radiologists should be aware that in patients with advanced cirrhosis hemangiomas may be difficult to diagnose confidently at CT and MRI. Comparison to prior studies when cirrhosis was less advanced may be helpful, as the hemangioma may have had more characteristic features previously. Another important diagnostic clue is [diameter stability](#) or [diameter reduction](#) over time.

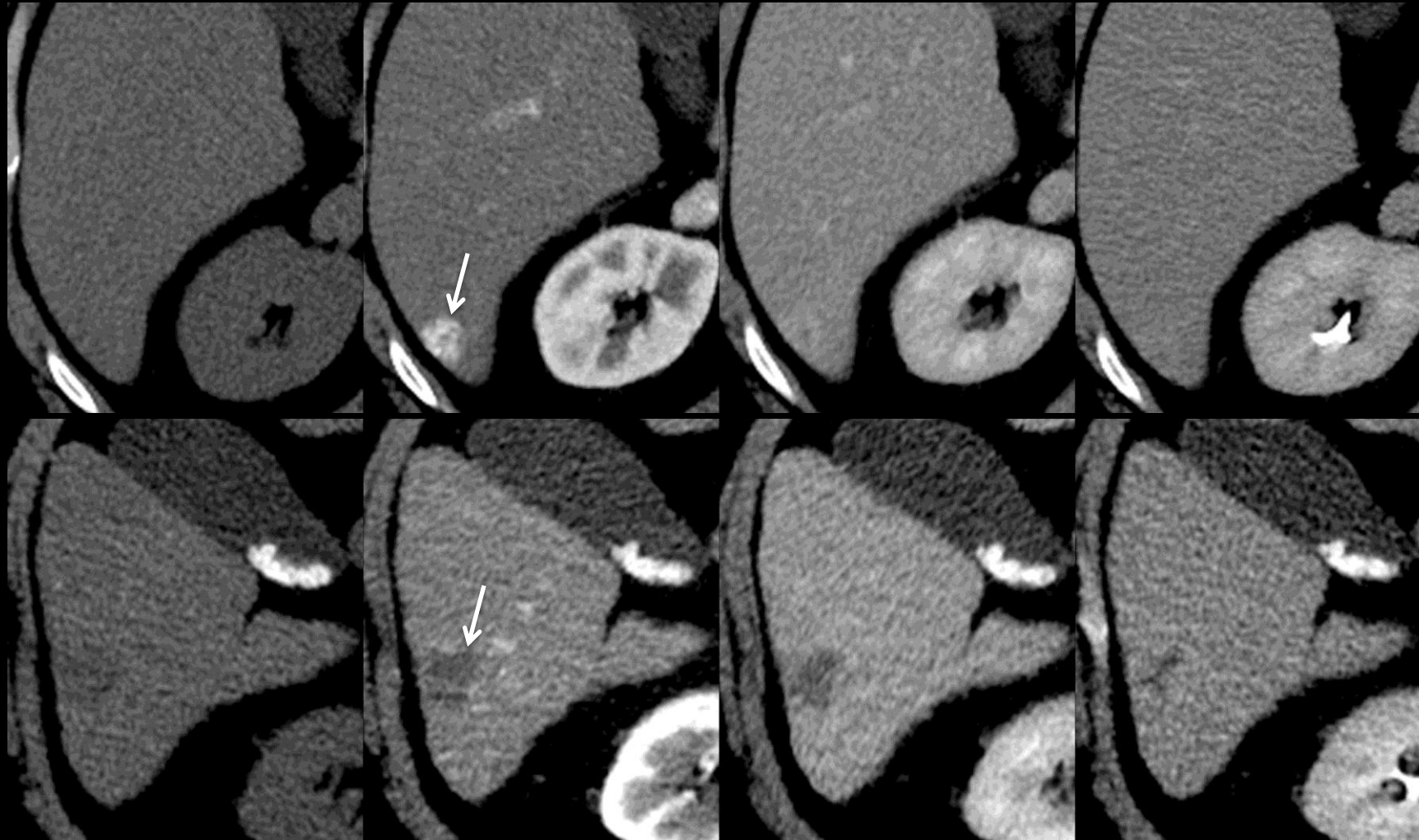


Pre

Arterial

Portal Venous

Delayed



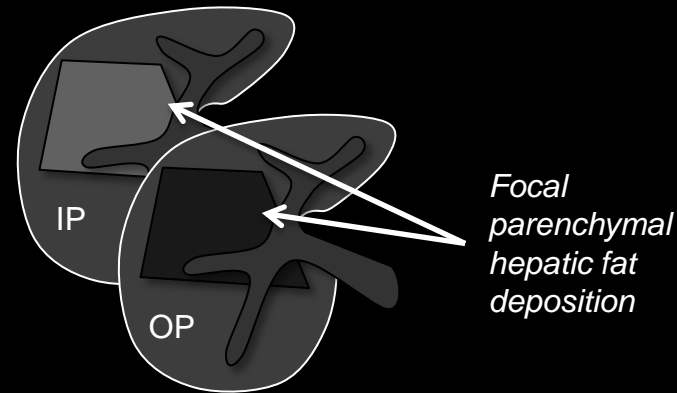
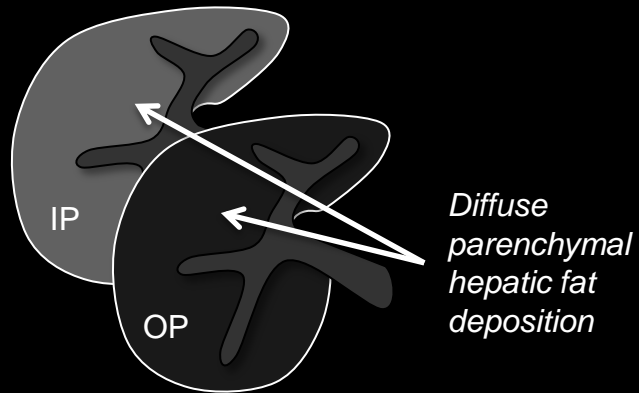
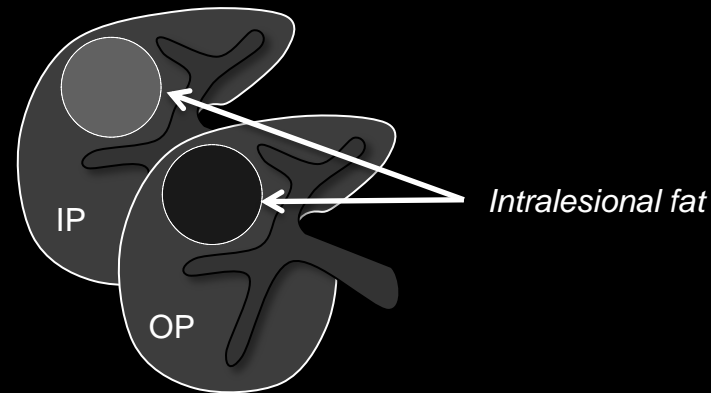
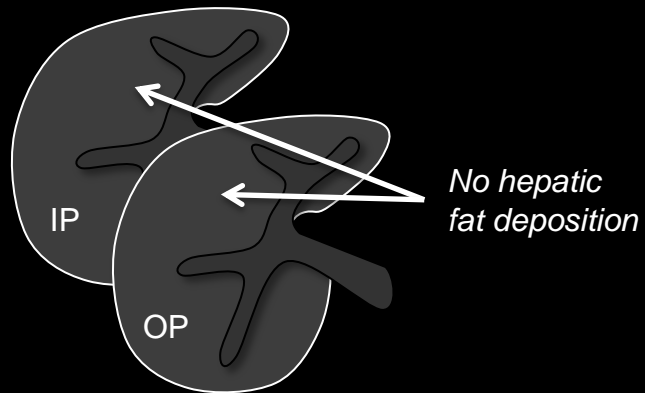
**Hemangioma in cirrhosis (CT):** Figures show 16mm ring-enhancing hemangioma (top row) and 22mm sclerosing hemangioma (bottom row) in two patients with cirrhosis. As shown in these figures, hemangiomas in patients with cirrhosis may have non-classical imaging appearances.

**Hemangioma:****Other Comments:**

- Hemangiomas are seen less frequently in the cirrhotic than in the non-cirrhotic liver.



Hepatic fat deposition

Not hepatic fat deposition**Hepatic fat deposition:**

Presence of excess lipid within hepatic parenchyma. May be [diffuse](#) or [focal](#).

**LI-RADS Categorization:**

- Observations thought to [definitely](#) represent hepatic fat deposition should be categorized LR1.
- Observations thought to [probably](#) represent hepatic fat deposition should be categorized LR2.
- Observations that are indeterminate for hepatic fat deposition versus HCC should be categorized LR3 or LR4.

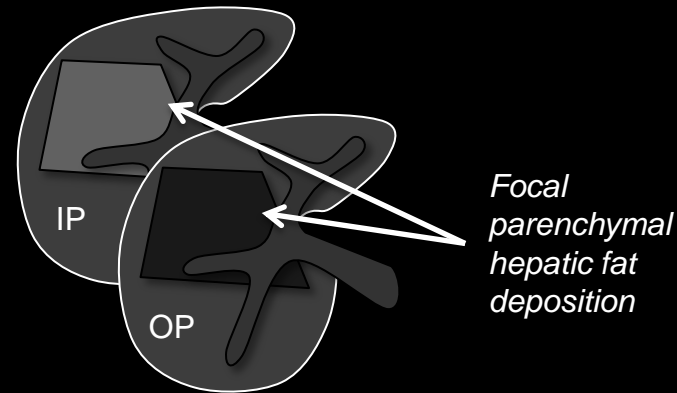
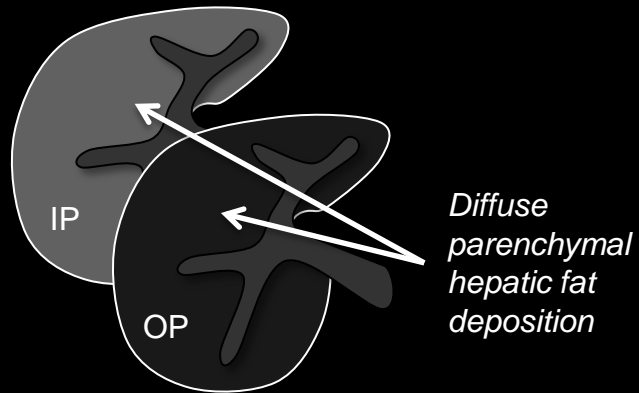
[Imaging Manifestations](#)[Pitfalls, Challenges, Differential Diagnosis](#)

**Hepatic fat deposition:** Top row: Schematic diagrams illustrate diffuse (left) and focal (right) hepatic fat deposition, characterized by signal loss on out-of-phase (OP) compared to on in-phase (IP) MR images. Bottom row: for comparison are illustrated a liver with no hepatic fat deposition (left) and an expansile mass with intra-lesional fat (right).

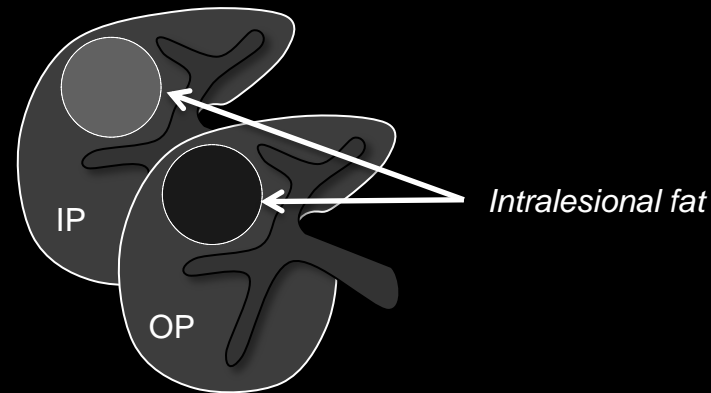
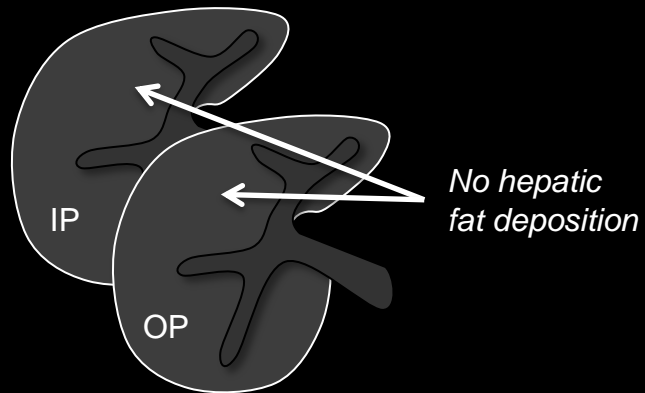




Hepatic fat deposition



Not hepatic fat deposition



Hepatic fat deposition:

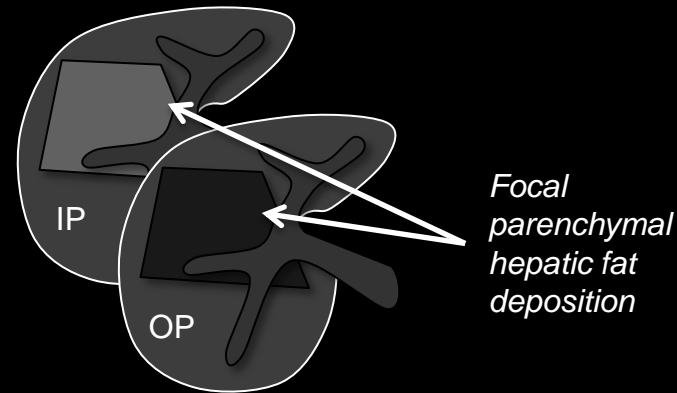
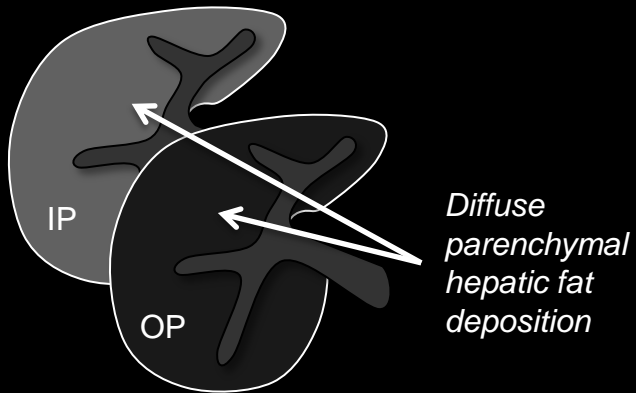
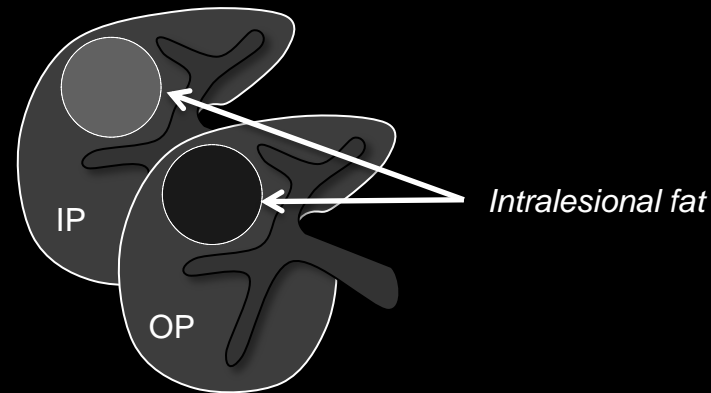
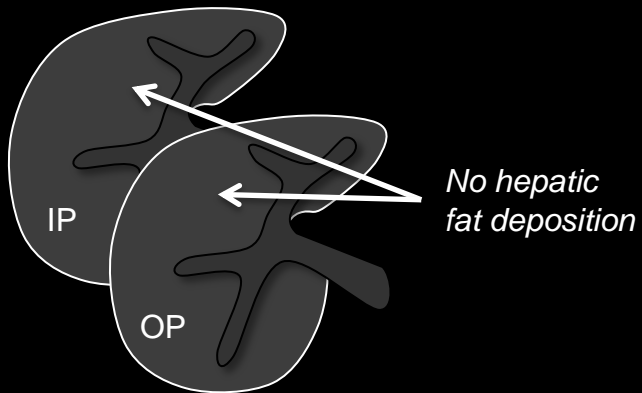
## Imaging Manifestations:

- MRI is more sensitive and specific for detection of hepatic fat deposition than CT.
- At MRI, hepatic fat deposition may be diagnosed if the liver, in whole or in part, shows signal loss on out-of-phase (OP) compared to in-phase (IP) gradient-echo images or on fat-suppressed compared to non-fat-suppressed images.
- At CT, hepatic fat deposition may be diagnosed if the attenuation of the liver, in whole or in part, measures
  - $\leq 40$  Hounsfield units (HU) on unenhanced or enhanced images OR
  - $\geq 10$  HU lower than that of spleen on unenhanced images.
- On contrast-enhanced images, focal hepatic fat deposition may appear as if an area of darker signal/attenuation was stamped on the liver.
- Hepatic fat deposition may be [diffuse](#), [focal](#), or multi-focal.
- [Diffuse](#) hepatic fat deposition affects a large area of the liver (entire liver, lobe, or segment) and may have a [homogeneous](#) distribution or a [heterogeneous](#) distribution ([patchy](#), [perivascular](#), [subcapsular](#), multi-segmental).

**Hepatic fat deposition:** Top row: Schematic diagrams illustrate diffuse (left) and focal (right) hepatic fat deposition, characterized by signal loss on out-of-phase (OP) compared to on in-phase (IP) MR images. Bottom row: for comparison are illustrated a liver with no hepatic fat deposition (left) and an expansile mass with intra-lesional fat (right).



Hepatic fat deposition

Not hepatic fat deposition

Hepatic fat deposition:

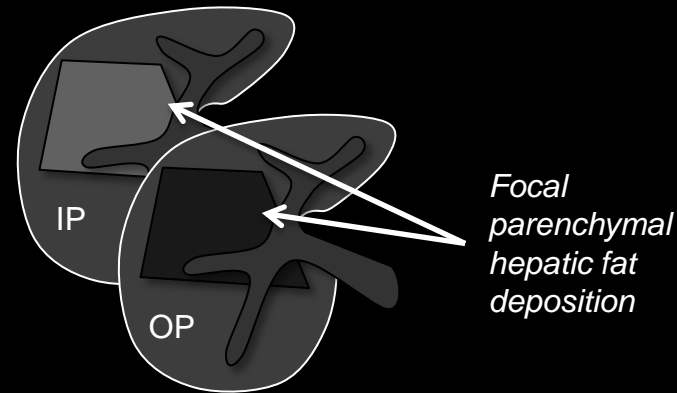
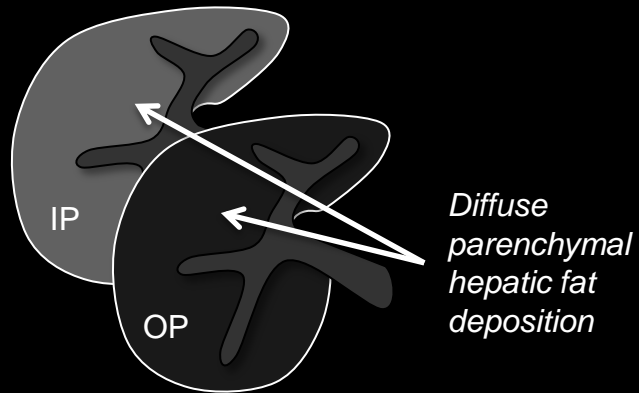
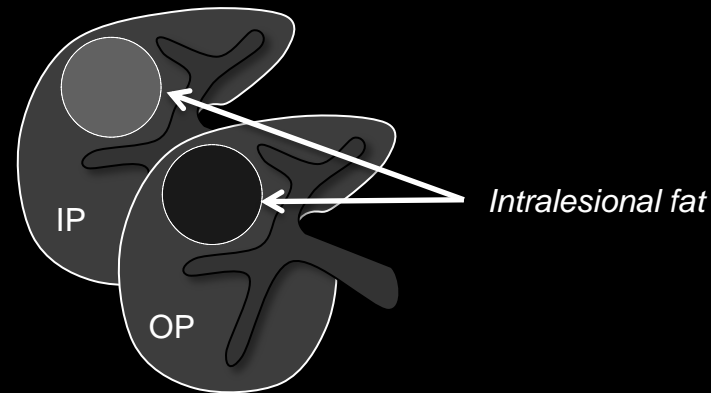
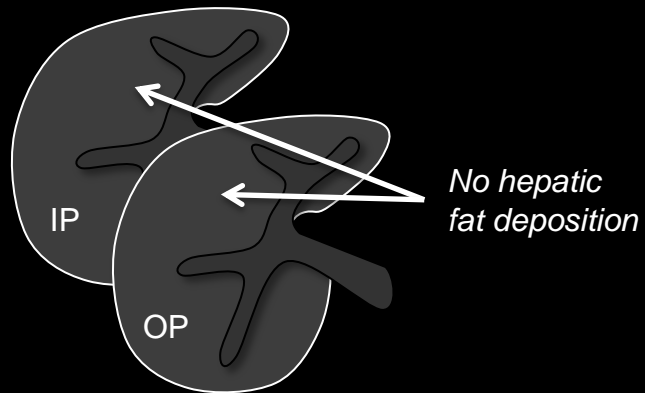
**Imaging Manifestations (continued):**

- **Focal** hepatic fat deposition affects a small area of the liver (subsegmental) and usually has a geographic shape. Less commonly it has a rounded shape. It usually occurs in specific areas (e.g., adjacent to the porta hepatis, gallbladder fossa, falciform ligament and ligamentum venosum).
- If there are multiple areas of focal hepatic fat deposition, the term multi-focal fat deposition applies.

**Hepatic fat deposition:** Top row: Schematic diagrams illustrate diffuse (left) and focal (right) hepatic fat deposition, characterized by signal loss on out-of-phase (OP) compared to on in-phase (IP) MR images. Bottom row: for comparison are illustrated a liver with no hepatic fat deposition (left) and an expansile mass with intra-lesional fat (right).



Hepatic fat deposition

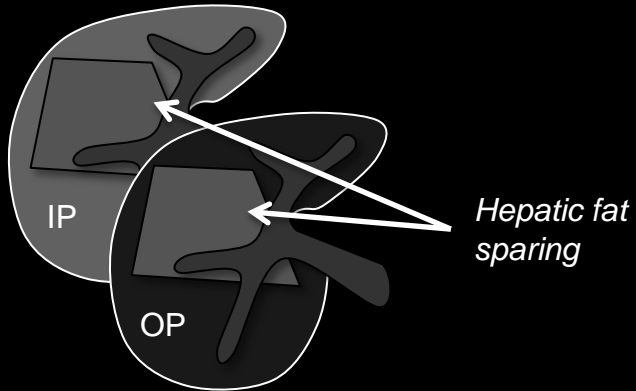
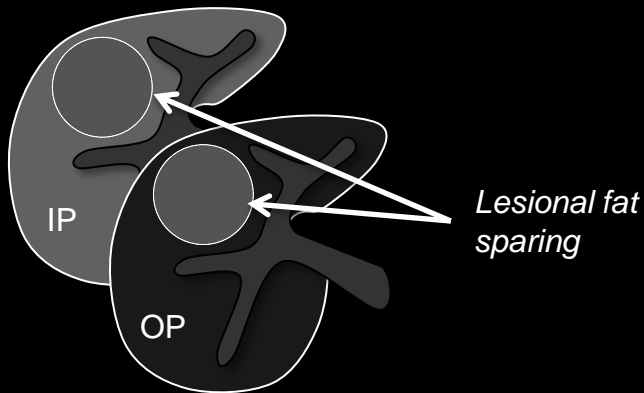
Not hepatic fat deposition**Hepatic fat deposition:****Pitfalls, Challenges, Differential Diagnosis:**

- Hepatic fat deposition may overlap in imaging appearance with solitary or multiple expansile [masses](#) or with infiltrative [masses](#).
- Imaging features that favor hepatic fat deposition over intra-lesional fat include:
  - Observation is not a [mass](#)
  - Presence of [undistorted vessels](#) traversing observation
  - Geographic rather than round shape
  - Presence of attenuation or signal abnormality that does not change relative to background liver over all phases of contrast enhancement
    - i.e., [iso-enhancement](#) to liver in all phases
- Multiplanar images (source or reformatted) may help correctly characterize observations as hepatic fat deposition by showing undistorted vessels traversing the affected areas, geographic shape, and absence of mass effect.

**Hepatic fat deposition:** Top row: Schematic diagrams illustrate diffuse (left) and focal (right) hepatic fat deposition, characterized by signal loss on out-of-phase (OP) compared to on in-phase (IP) MR images. Bottom row: for comparison are illustrated a liver with no hepatic fat deposition (left) and an expansile mass with intra-lesional fat (right).



Hepatic fat sparing

Not hepatic fat sparing

**Hepatic fat sparing:** Top : Schematic diagram illustrates focal hepatic fat sparing on in-phase (IP) and out-of-phase (OP) MR images. The liver is fatty and loses signal on the OP compared to the IP image. There is a geographically shaped region of hepatic fat sparing; compared to background liver, the spared area loses less signal on the OP image (i.e., it has lower fractional fat content than the rest of the liver). Bottom row: expansile mass with intra-lesional fat sparing in a fatty liver.

**Hepatic fat sparing:**

Lack of lipid or relative lack of lipid within portion of otherwise fatty hepatic parenchyma. Usually [focal](#).

**LI-RADS Categorization:**

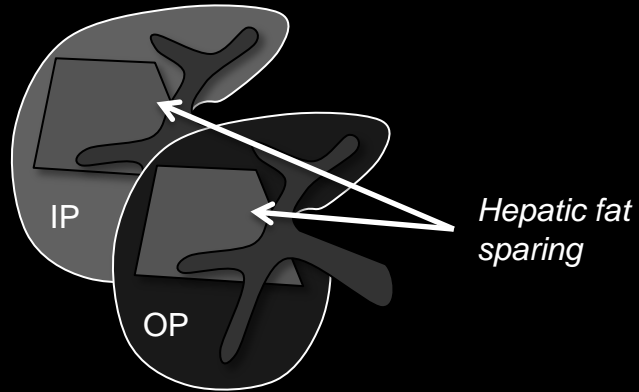
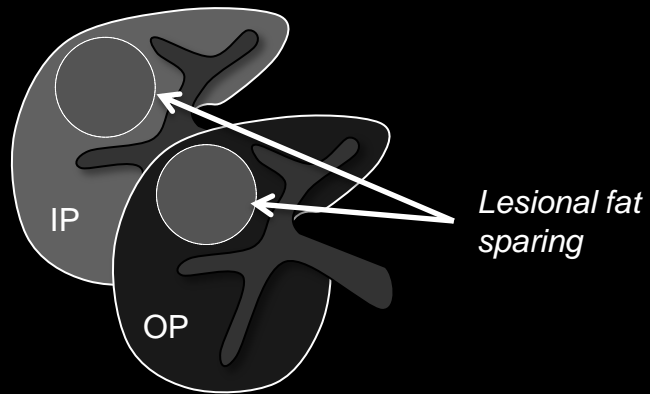
- Observations thought to [definitely](#) represent hepatic fat sparing should be categorized LR1.
- Observations thought to [probably](#) represent hepatic fat sparing should be categorized LR2.
- Observations that are indeterminate for hepatic fat sparing versus HCC should be categorized LR3 or LR4.

[Imaging Manifestations](#)[Pitfalls, Challenges, Differential Diagnosis](#)





Hepatic fat sparing

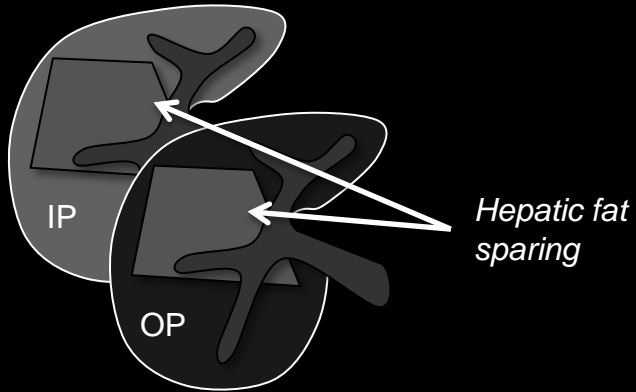
Not hepatic fat sparing**Hepatic fat sparing:****Imaging Manifestations:**

- MRI is more sensitive and specific for detection of hepatic fat sparing than CT.
- At MRI, hepatic fat sparing may be diagnosed if
  - The liver shows signal loss on out-of-phase (OP) compared to in-phase (IP) gradient echo images or on fat-suppressed compared to non-fat-suppressed images (i.e., liver is fatty) AND
  - One or more portions of the liver show less signal loss than the rest of the liver on OP compared to IP images or on fat-suppressed compared to non-fat-suppressed images (i.e., portions of liver are less fatty).
- At CT, hepatic fat sparing may be diagnosed if
  - The attenuation of the liver measures  $\leq 40$ HU (on unenhanced or enhanced images) or  $\geq 10$  HU less than that of spleen (on unenhanced images)(i.e., liver is fatty) AND
  - One or more portions of the liver are hyper-attenuating relative to the rest of the liver (i.e., portions of liver are less fatty).

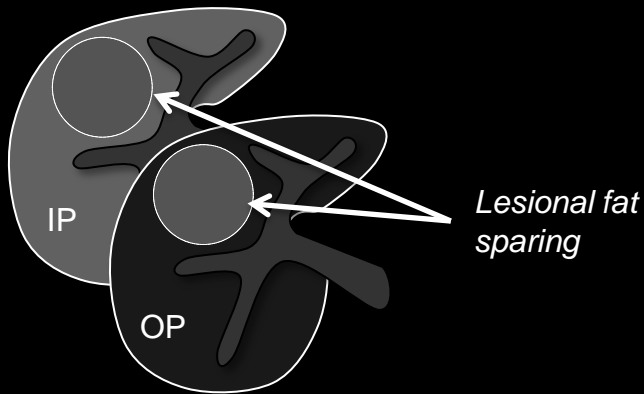
**Hepatic fat sparing:** Top : Schematic diagram illustrates focal hepatic fat sparing on in-phase (IP) and out-of-phase (OP) MR images. The liver is fatty and loses signal on the OP compared to the IP image. There is a geographically shaped region of hepatic fat sparing; compared to background liver, the spared area loses less signal on the OP image (i.e., it has lower fractional fat content than the rest of the liver). Bottom row: expansile mass with intra-lesional fat sparing in a fatty liver.



Hepatic  
fat sparing



Not hepatic  
fat sparing



**Hepatic fat sparing:** Top : Schematic diagram illustrates focal hepatic fat sparing on in-phase (IP) and out-of-phase (OP) MR images. The liver is fatty and loses signal on the OP compared to the IP image. There is a geographically shaped region of hepatic fat sparing; compared to background liver, the spared area loses less signal on the OP image (i.e., it has lower fractional fat content than the rest of the liver). Bottom row: expansile mass with intra-lesional fat sparing in a fatty liver.

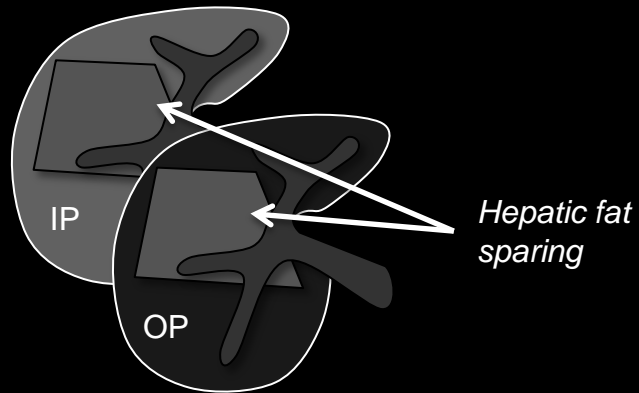
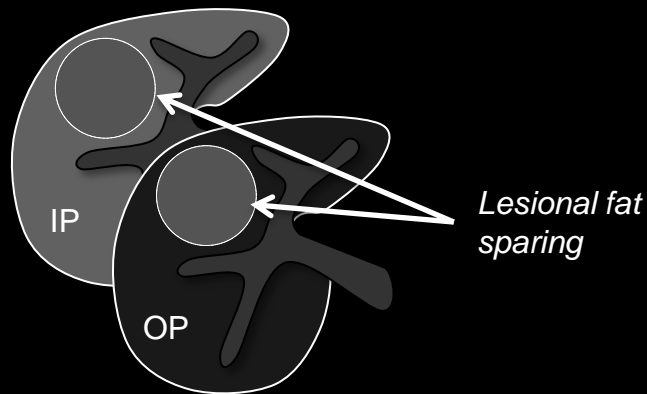
Hepatic fat sparing:

**Imaging Manifestations (continued):**

- [Focal](#) hepatic fat sparing usually occurs in similar areas as focal [hepatic fat deposition](#) (e.g., adjacent to the porta hepatis, gallbladder fossa, falciform ligament and ligamentum venosum). In diffusely fatty liver, it may occur around the margin of a mass or in an area affected by a [perfusion alteration](#).



Hepatic fat sparing

Not hepatic fat sparing

**Hepatic fat sparing:** Top : Schematic diagram illustrates focal hepatic fat sparing on in-phase (IP) and out-of-phase (OP) MR images. The liver is fatty and loses signal on the OP compared to the IP image. There is a geographically shaped region of hepatic fat sparing; compared to background liver, the spared area loses less signal on the OP image (i.e., it has lower fractional fat content than the rest of the liver). Bottom row: expansile mass with intra-lesional fat sparing in a fatty liver.

**Hepatic fat sparing:****Pitfalls, Challenges, Differential Diagnosis:**

- Focal hepatic fat sparing may overlap in imaging appearance with expansile [masses](#) (solitary or multiple).
- Imaging features that favor focal hepatic fat sparing over expansile mass include:
  - Observation is not a [mass](#)
  - Presence of [undistorted vessels](#) traversing the observation
  - Geographic rather than round shape
  - Presence of attenuation or signal abnormality that does not change relative to background liver over all phases of contrast enhancement
    - i.e., [iso-enhancement](#) to liver in all phases
- Multiplanar images (source or reformatted) may help correctly characterize observations as hepatic fat sparing by showing undistorted vessels traversing the spared areas, geographic shape, and absence of mass effect.



## Heterogeneous:

Not uniform in distribution, enhancement, attenuation, signal intensity, or other imaging feature. Is the opposite of [homogeneous](#).

**Heterogeneous enhancement:**

Enhancement that is not uniform in appearance. Is the opposite of [homogeneous enhancement](#).

**Comments:**

- Use of more specific descriptors is recommended if applicable, such as [mosaic](#), peripheral, multi-nodular, [nodule-in-nodule](#), etc.





## Homogeneous:

Uniform in distribution, enhancement, attenuation, signal intensity, or other imaging feature. Is the opposite of [heterogeneous](#).



## Homogeneous enhancement:

Enhancement that is uniform in appearance. Is the opposite of [heterogeneous enhancement](#).



Marked T2 hyper-intensity

Homogeneous  
marked T2  
hyper-intensityMild-moderate T2 hyper-intensity  
(Well defined observation)Heterogeneous marked  
T2 hyper-intensityNot  
homogeneous  
marked  
T2 hyper-intensity**Homogeneous marked T2 hyper-intensity:**

Having [homogeneous](#) and markedly higher signal intensity than liver at T2w imaging.

**Comments:**

- Applies to observations that, on T2w images, [unequivocally](#):
  - Are homogeneously and markedly hyper-intense relative to liver on T2w images. The hyper-intensity relative to liver is more pronounced with longer echo times; the signal intensity may approximate that of bile ducts and other simple-fluid filled structures.
- Homogeneous marked T2 hyper-intensity is an [ancillary feature](#) favoring benignity.
- Radiologists at their discretion may apply homogeneous marked T2 hyper-intensity to downgrade category.

**Homogeneous marked T2 hyper-intensity:** As illustrated in schematic diagram, homogeneous marked T2 hyper-intensity refers to signal intensity on T2w images that is markedly higher than that of liver and may approximate that of bile ducts and other simple fluid-filled structures. Mild-moderate T2 hyper-intensity refers to signal intensity on T2w images only slightly higher than that of liver and substantially lower than that of bile ducts and other simple-fluid filled structures. Heterogeneous marked T2 hyper-intensity refers to presence of markedly T2 hyper-intense areas in addition to areas that are not markedly T2 hyper-intense within an observation.



A. Marked T2 hypo-intensity

Homogeneous  
marked T2  
hypo-intensity

B. Conglomerate marked T2 hypo-intense nodules

C. Mild-moderate  
T2 hypo-intensity,  
Well definedD. Mild-moderate T2  
hypo-intensity,  
Ill definedE. Hyper-intense  
internal nodule(s)F. T2 hypo-intensity  
similar to that of liverNot homogeneous  
marked T2  
hypo-intensity

**Homogeneous marked T2 hypo-intensity:** As illustrated in schematic diagram, homogeneous marked T2 hypo-intensity refers to signal intensity on T2w images that is markedly lower than that of liver (top row). This is an ancillary feature favoring benignity. It applies to uniform masses (top-A) and to masses that are a conglomeration of smaller nodules (top-B). It does not apply to observations with mild-moderate T2 hypo-intensity (bottom-C and bottom-D), with hyper-intense internal nodules (bottom-E), or with hypo-intensity similar to that of background cirrhotic nodules (bottom-F). [Click here to see schematic of homogeneous marked T2\\* hypo-intensity.](#)

**Homogeneous marked T2 or T2\* hypo-intensity:**

Having [homogeneous](#) and markedly lower signal intensity than liver at T2w or T2\*w imaging.

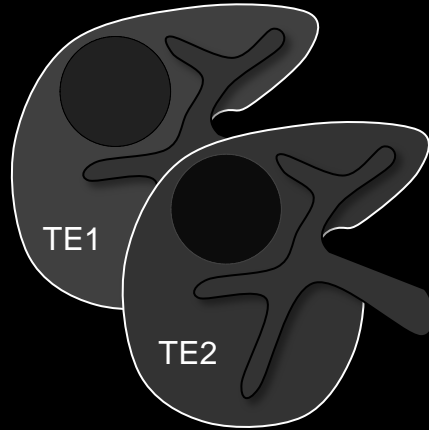
**Comments:**

- Applies to observations that [unequivocally](#):
  - Are homogeneously and markedly hypo-intense relative to liver on T2w or T2\*w images or that have moderate or marked signal loss on the second echo of a dual-echo imaging acquisition. The hypo-intensity relative to liver is more pronounced with longer echo times and, if dual-echo imaging is performed, with greater echo spacing.
- Also applies to masses that are a conglomeration of smaller nodules, each of which is uniform in size and appearance including homogeneous and marked hypo-intensity relative to liver on T2w or T2\*w images. This differs from multi-nodule-in-nodule appearance in which the individual nodules differ in size or appearance.
- Homogeneous marked T2 or T2\* hypo-intensity is an [ancillary feature](#) favoring benignity.
- Radiologists at their discretion may apply homogeneous marked T2 or T2\* hypo-intensity to downgrade category.

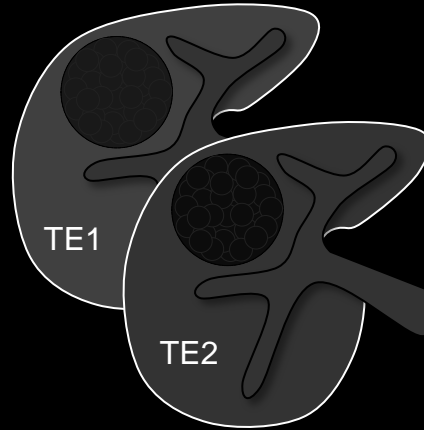
Atlas: MR



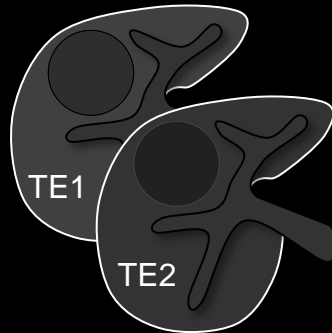
A. Marked T2 hypo-intensity



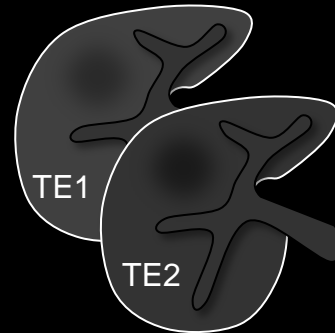
B. Conglomerate marked T2 hypo-intense nodules



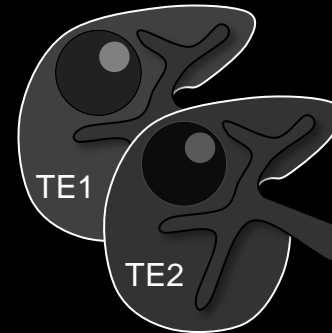
C. Mild-moderate T2\* hypo-intensity, Well defined



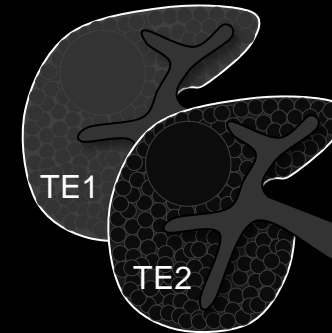
D. Mild-moderate T2\* hypo-intensity, Ill defined



E. Hyper-intense internal nodule(s)



F. T2\* hypo-intensity similar to that of liver



Homogeneous marked T2\* hypo-intensity

Not homogeneous marked T2\* hypo-intensity

**Homogeneous marked T2\* hypo-intensity:** As illustrated in schematic diagram, homogeneous marked T2\* hypo-intensity refers to signal intensity on T2\*w images that is markedly lower than that of liver (top row). The hypo-intensity is more pronounced at longer echo times (TEs). This is an ancillary feature favoring benignity. It applies to uniform masses (top-A) and to masses that are a conglomeration of smaller nodules (top-B). It does not apply to observations with mild-moderate T2\* hypo-intensity (bottom-C and bottom-D), with hyper-intense internal nodules (bottom-E), or with hypo-intensity similar to that of liver (bottom-F). [Click here to see schematic of homogeneous marked T2 hypo-intensity.](#)

**Homogeneous marked T2 or T2\* hypo-intensity:**

Having [homogeneous](#) and markedly lower signal intensity than liver at T2w or T2\*w imaging.

**Comments:**

- Applies to observations that [unequivocally](#):
  - Are homogeneously and markedly hypo-intense relative to liver on T2w or T2\*w images or that have moderate or marked signal loss on the second echo of a dual-echo imaging acquisition. The hypo-intensity relative to liver is more pronounced with longer echo times and, if dual-echo imaging is performed, with greater echo spacing.
- Also applies to masses that are a conglomeration of smaller nodules, each of which is uniform in size and appearance including homogeneous and marked hypo-intensity relative to liver on T2w or T2\*w images. This differs from multi-nodule-in-nodule appearance in which the individual nodules differ in size or appearance.
- Homogeneous marked T2 or T2\* hypo-intensity is an [ancillary feature](#) favoring benignity.
- Radiologists at their discretion may apply homogeneous marked T2 or T2\* hypo-intensity to downgrade category.

Atlas: MR



**Hyper-enhancement:**

Enhancement that [unequivocally](#) is greater than that of liver.

**If there is equivocal hyper-enhancement:**

- Do not characterize as hyper-enhancement.

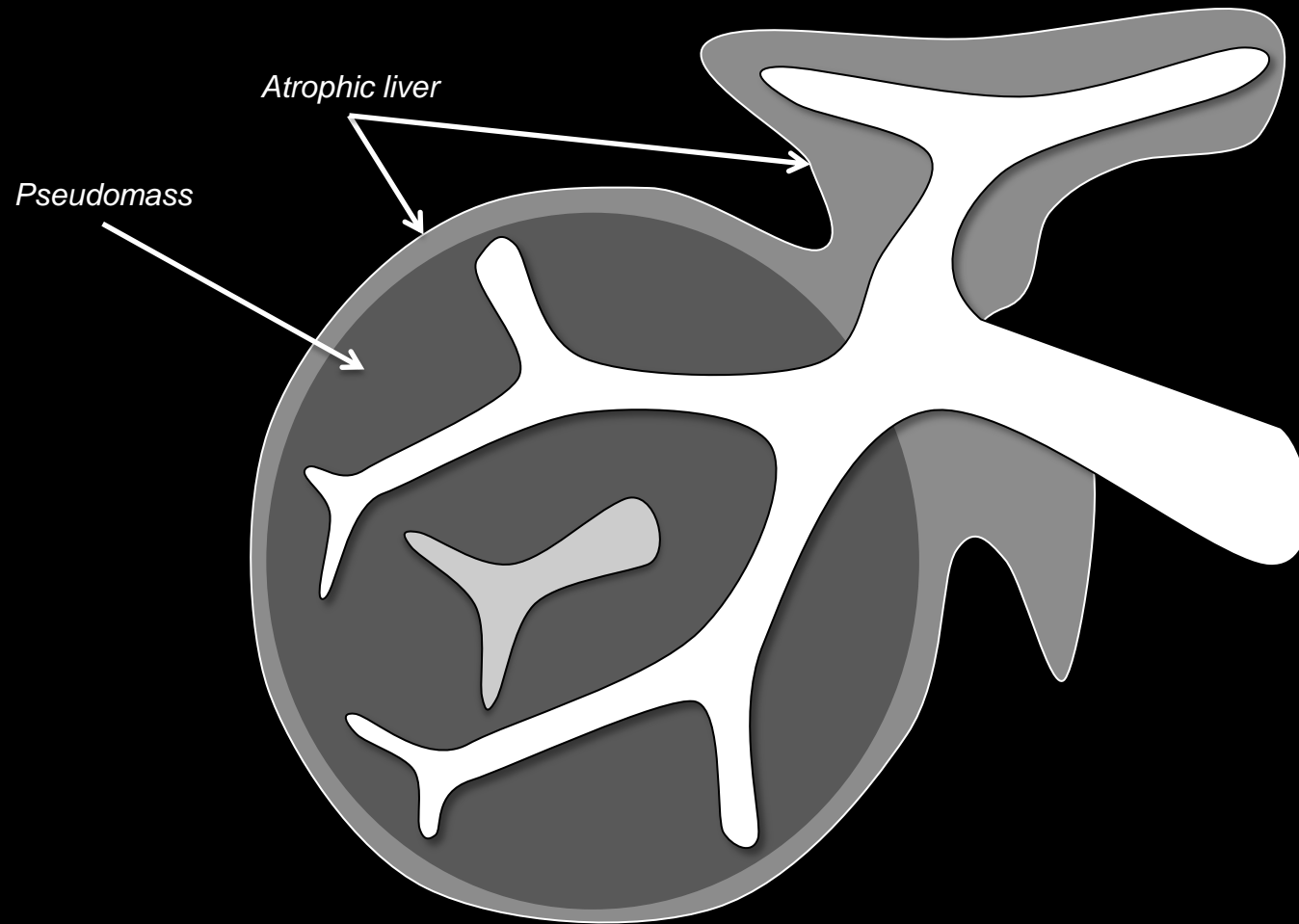
**Comments:**

- Applies to observations that, after contrast injection:
  - Unequivocally enhance, in whole or in part, more than liver AND
  - Are higher in attenuation or intensity than liver.
- May apply to [arterial phase](#), [portal venous phase](#), or [delayed phase](#).
- Specifying the phase is necessary.

**Atlas:** CT, MR



### Hypertrophic Pseudomass



**Hypertrophic pseudomass:** Schematic diagram illustrates a hypertrophic pseudomass. As shown in schematic, hypertrophic pseudomasses represent areas of hepatic parenchymal hypertrophy surrounded by atrophic, fibrotic parenchyma. At imaging, they may have a bulging appearance. Key distinguishing features from true masses include preserved hepatic architecture and presence of [undistorted vessels](#) traversing observation.

### Hypertrophic pseudomass:

Hypertrophic area of liver that is surrounded by atrophic, fibrotic liver parenchyma and may at imaging have a bulging appearance.

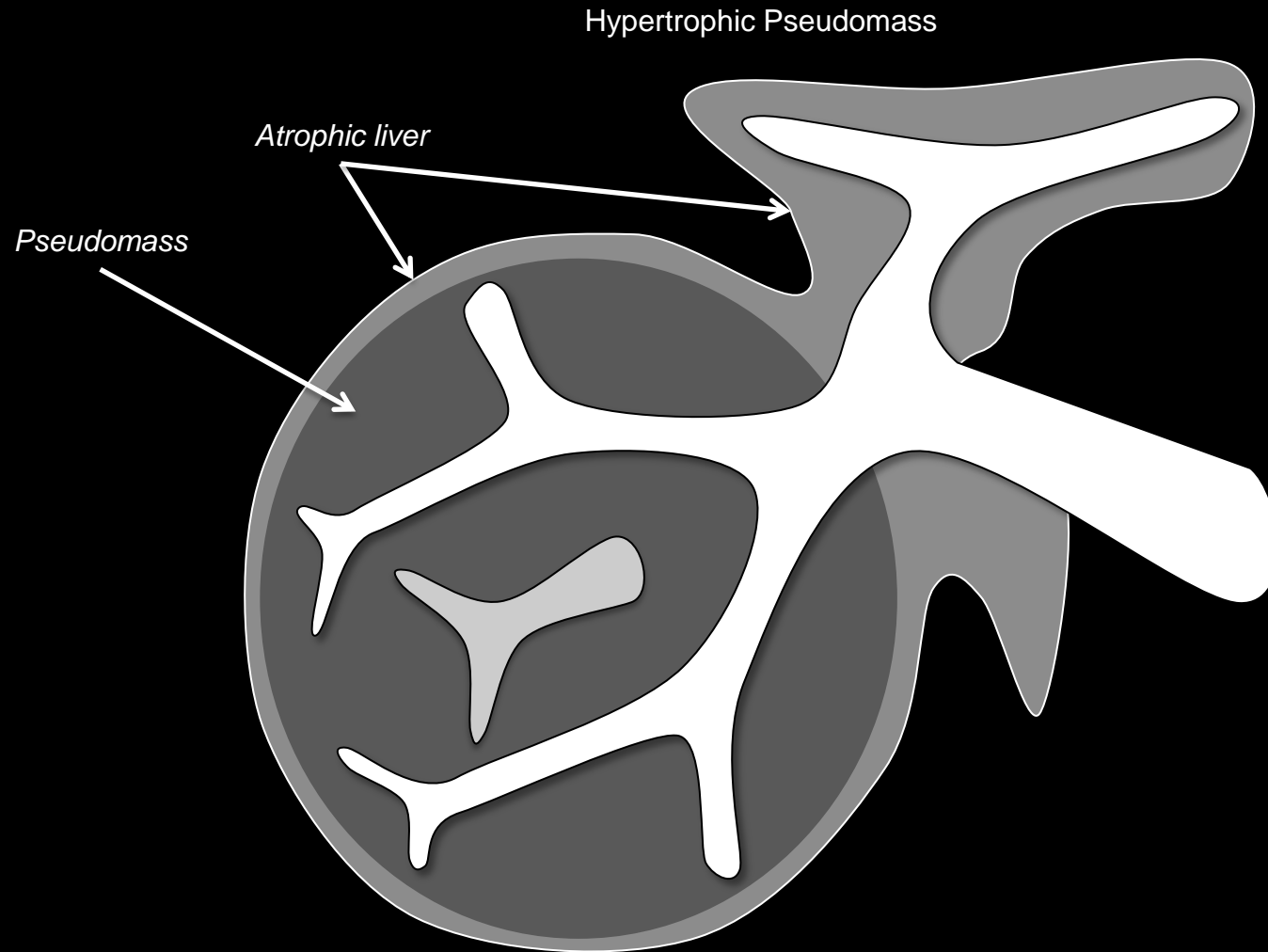
### LI-RADS Categorization:

- Observations thought to [definitely](#) represent hypertrophic pseudomasses should be categorized LR1.
- Observations thought to [probably](#) represent hypertrophic pseudomasses should be categorized LR2.
- Observations that are indeterminate for hypertrophic pseudomasses versus HCC should be categorized LR3 or LR4.

### [Imaging Manifestations](#)

### [Pitfalls, Challenges, Differential Diagnosis](#)

### [Other Comments](#)



## Hypertrophic pseudomass:

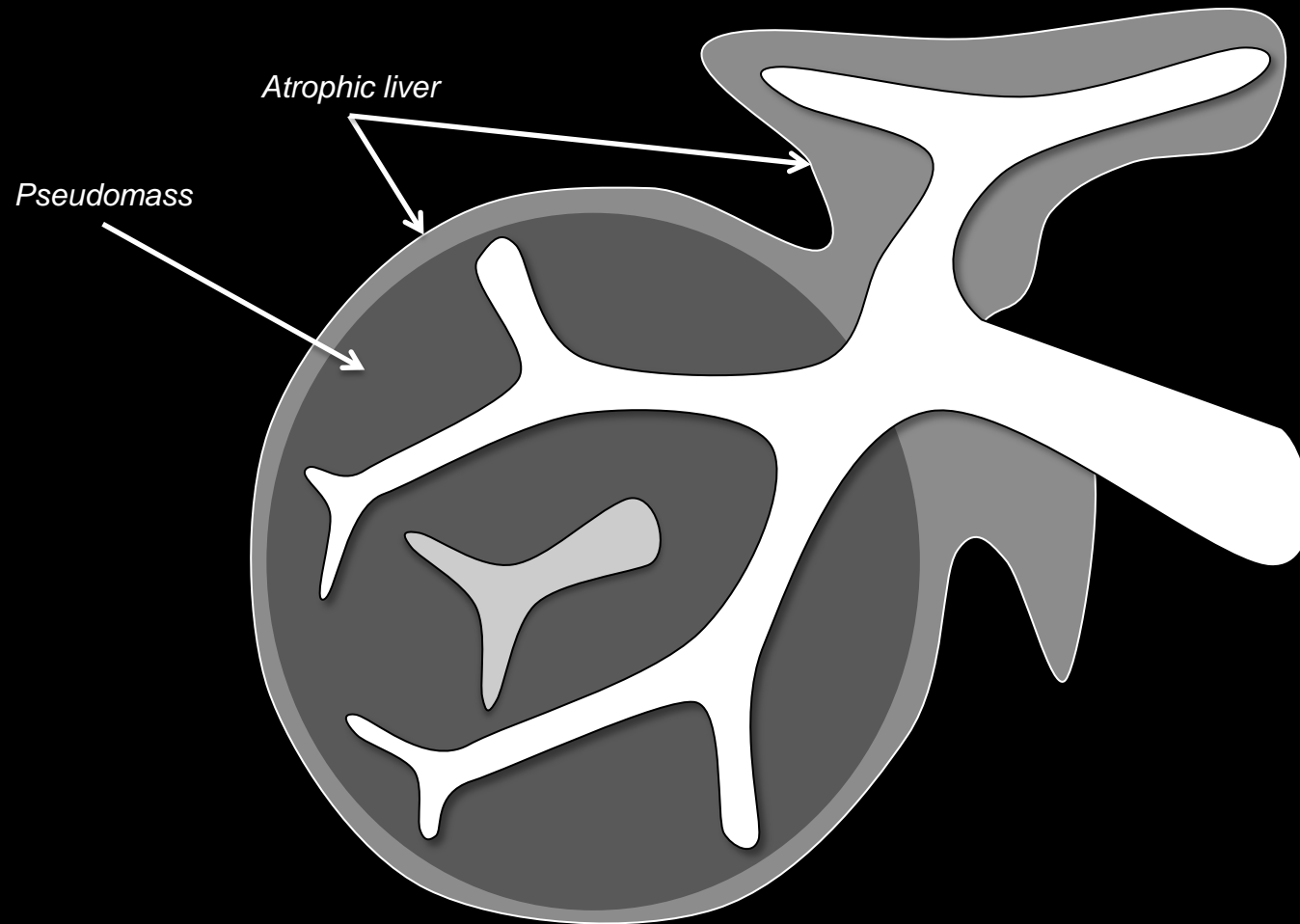
### Imaging Manifestations:

- In comparison to surrounding more fibrotic liver, hypertrophic pseudomasses usually are
  - Mildly T1 hyper-intense
  - Mildly T2 hypo-intense
  - Iso- or hypo-enhanced in the [delayed phase](#)
- Hypertrophic pseudomasses may have greater fat deposition than surrounding more fibrotic liver.

**Hypertrophic pseudomass:** Schematic diagram illustrates a hypertrophic pseudomass. As shown in schematic, hypertrophic pseudomasses represent areas of hepatic parenchymal hypertrophy surrounded by atrophic, fibrotic parenchyma. At imaging, they may have a bulging appearance. Key distinguishing features from true masses include preserved hepatic architecture and presence of [undistorted vessels](#) traversing observation.



### Hypertrophic Pseudomass



### Hypertrophic pseudomass:

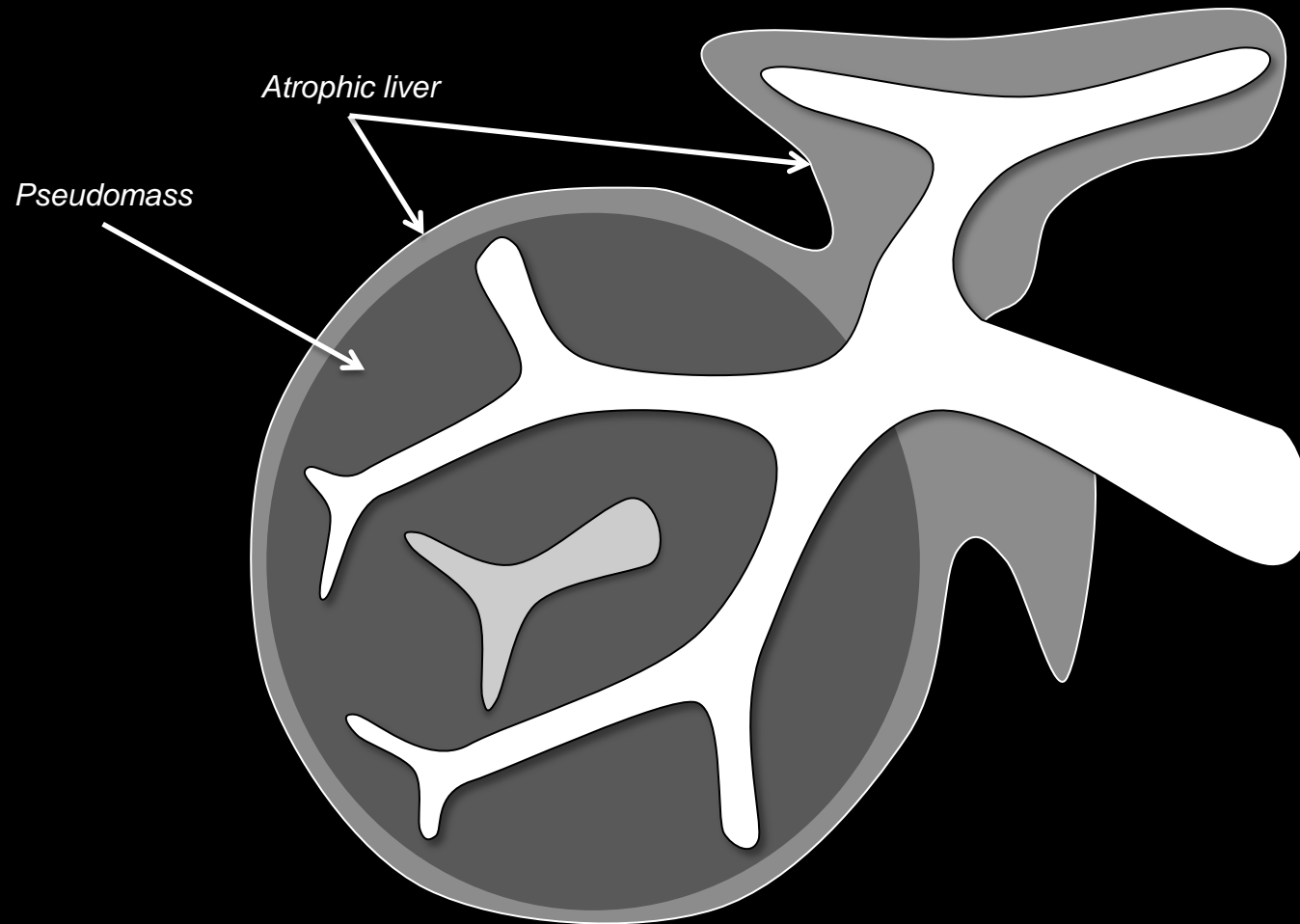
#### Pitfalls, Challenges, Differential Diagnosis:

- Hypertrophic pseudomasses need to be differentiated from expansile masses.
- Imaging features that favor hypertrophic pseudomass over expansile mass:
  - Preserved hepatic architecture
  - Presence of [undistorted vessels](#) traversing observation
- Multiplanar images (source or reformatted) may help correctly characterize observations as hypertrophic pseudomasses by showing preserved hepatic architecture and undistorted vessels.

**Hypertrophic pseudomass:** Schematic diagram illustrates a hypertrophic pseudomass. As shown in schematic, hypertrophic pseudomasses represent areas of hepatic parenchymal hypertrophy surrounded by atrophic, fibrotic parenchyma. At imaging, they may have a bulging appearance. Key distinguishing features from true masses include preserved hepatic architecture and presence of [undistorted vessels](#) traversing observation.



### Hypertrophic Pseudomass



### Hypertrophic pseudomass:

#### Other Comments:

- Hypertrophic pseudomasses are seen more frequently in certain etiologies of cirrhosis (PSC, Budd Chiari, alcoholic liver disease) and cirrhosis complicated by chronic portal vein occlusion.

**Hypertrophic pseudomass:** Schematic diagram illustrates a hypertrophic pseudomass. As shown in schematic, hypertrophic pseudomasses represent areas of hepatic parenchymal hypertrophy surrounded by atrophic, fibrotic parenchyma. At imaging, they may have a bulging appearance. Key distinguishing features from true masses include preserved hepatic architecture and presence of [undistorted vessels](#) traversing observation.



**Hypo-enhancement:**

Enhancement that [unequivocally](#) is less than that of liver.

**If there is equivocal hypo-enhancement:**

- Characterize as iso-enhancement.

**Comments:**

- Applies to enhancing observations that, after contrast injection:
  - Unequivocally enhance less than liver AND
  - Are lower in attenuation or intensity than liver.
- May apply to [arterial phase](#), [portal venous phase](#), or [delayed phase](#).
- Specifying the phase is necessary.
- Depending on the phase, may apply to the entire observation or to part of an observation:
  - [Arterial phase hypo-enhancement](#): the observation in whole hypo-enhances.
  - [Portal venous phase hypo-enhancement](#) or [delayed phase hypo-enhancement](#): the observation in whole or in part hypo-enhances.

**Hypo-enhancement:****Comments (continued):**

- The enhancement of the observation should be compared to that of the adjacent liver parenchyma. If the liver parenchyma visually consists of both nodules and fibrosis, then enhancement of the observation should be compared to that of the composite liver tissue (i.e., a visual average of the nodules and fibrosis) (see schematics for [“washout”](#), [portal venous phase hypo-enhancement](#), and [delayed phase hypo-enhancement](#)).

**Increasing enhancement:**

Degree of enhancement relative to liver increases from an earlier to a later phase in the same study.

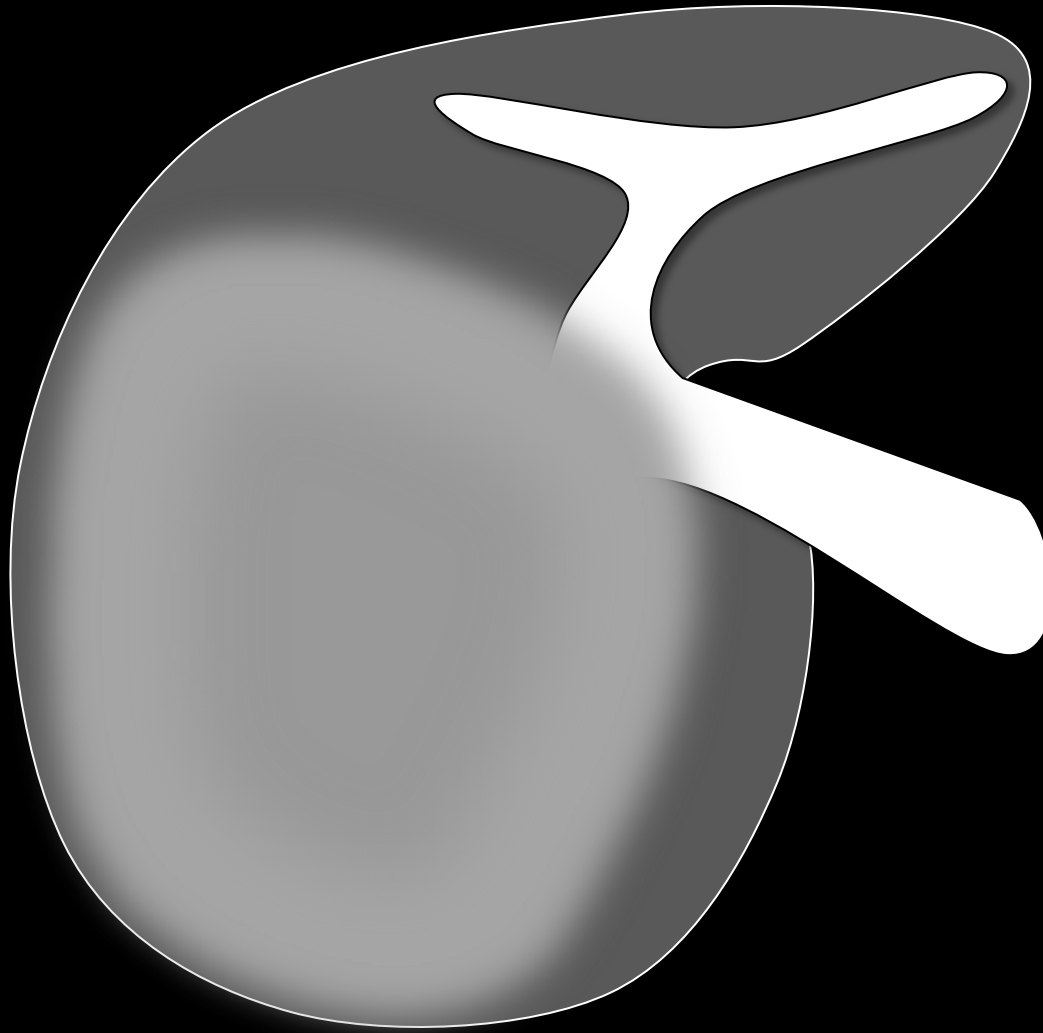
**Comments:**

- May apply to entire observation or to part of an observation, depending on the context.

**Atlas:** CT, MR



## Infiltrative HCC

**Infiltrative HCC:**

Variant of HCC with permeative growth pattern.

**Comments:**

- At imaging, infiltrative HCC may manifest as a diffuse ill-defined mass, often involving more than one segment.
- Infiltrative HCCs may be difficult to detect in the cirrhotic liver at CT and MRI. Pre-contrast imaging may be helpful. Careful analysis of all available images frequently is necessary.
- Features [suggestive](#) of infiltrative HCC include (partial list):
  - [Heterogeneous](#) attenuation/signal intensity
  - Mild to moderate T1 hypo-intensity not attributable to edema
  - [Mild to moderate T2 hyper-intensity](#) not attributable to edema or, on non-fat-suppressed T2w images, [hepatic fat deposition](#)
  - Mild to moderate [restricted diffusion](#)
  - Heterogeneous enhancement in one or more phases
  - [Tumor in vein](#)
  - Obscured or non-visualized veins not attributable to chronic benign occlusion
  - Architectural distortion

**Atlas:** CT, MR

**Infiltrative HCC:** Schematic diagram illustrates infiltrative HCC as a diffuse ill-defined mass involving several liver segments and obscuring underlying vessels.



## Intra-lesional fat:

Presence of lipid in higher concentration within a mass than in background reference tissue (e.g. liver).

### Comments:

- Applies only to [masses](#) that, in whole or in part, [unequivocally](#) have higher fractional fat content than background liver.
- In patients at risk for HCC, intra-lesional fat is an [ancillary feature](#) favoring HCC.
- Radiologists at their discretion may apply intra-lesional fat to upgrade category (up to LR4).
- MRI is more sensitive and specific for detection of intra-lesional fat than CT.
- At MRI, a mass may be characterized as having intra-lesional fat if:
  - It shows signal loss on out-of-phase (OP) compared to in-phase (IP) gradient echo images or it shows signal loss on fat-suppressed compared to non-fat-suppressed images AND
  - Its degree of signal loss is greater than that of liver (i.e., it has higher fractional fat content than liver).

Diffusely fatty mass in non-steatotic liver

Partly fatty mass in non-steatotic liver

Diffusely fatty mass in steatotic liver

*Observation has higher fractional fat content than background steatotic liver*

Mass with similar fractional fat content as background steatotic liver

*Observation does not have higher fractional fat content than background steatotic liver*

Geographic hepatic steatosis (not mass)

Intra-lesional fat

Not intra-lesional fat

**Intra-lesional fat:** As illustrated in schematic diagrams of out-of-phase (OP) and in-phase (IP) gradient echo MR images, intra-lesional fat refers to presence of lipid in higher concentration within a mass, in whole (top left, top right) or in part (top center), than in background liver. Background liver may be non-steatotic (top left, top center) or steatotic (top right). Intra-lesional fat does not apply to focal or heterogeneous hepatic steatosis (bottom left) or to masses with similar or lower fractional fat content than background steatotic liver (bottom right). IP = in phase. OP = out of phase.





**Comments (continued):**

- At CT, a mass may be characterized as having intra-lesional fat if:
  - Its attenuation measures  $< 40$  Hounsfield units (HU) AND
  - Its attenuation is less than that of liver (i.e., it has higher fractional fat content than liver).
- Intralesional fat needs to be differentiated from parenchymal [hepatic fat deposition](#).
- Imaging features that, if present, favor intra-lesional fat over parenchymal [hepatic fat deposition](#) include:
  - Observation is a [mass](#) AND
  - Enhancement differs from that of background liver in one or more post-contrast phases and the difference is not attributable to a [perfusion alteration](#).
- Multiplanar images (source or reformatted) may help correctly characterize observations as having intra-lesional fat by showing that the observation is a [mass](#).

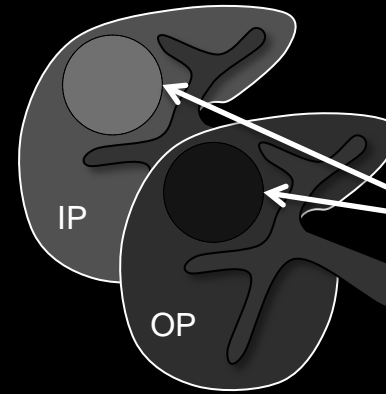
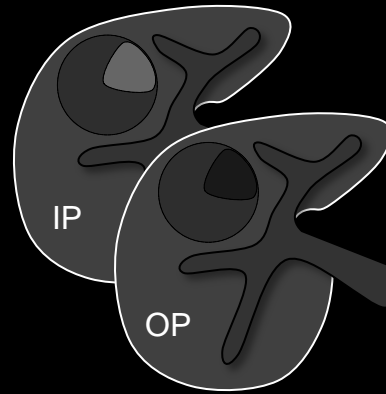
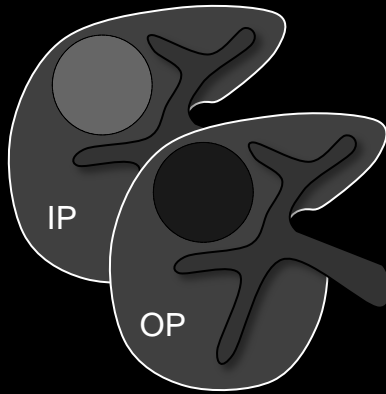
Diffusely fatty mass in non-steatotic liver

Partly fatty mass in non-steatotic liver

Diffusely fatty mass in steatotic liver

*Observation has higher fractional fat content than background steatotic liver*

Intra-lesional fat

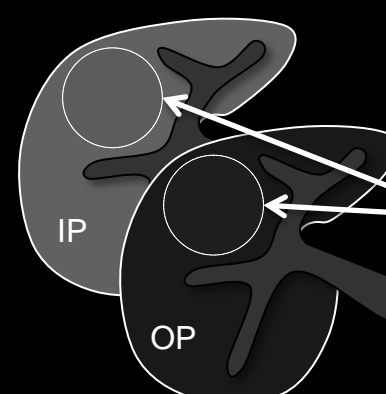
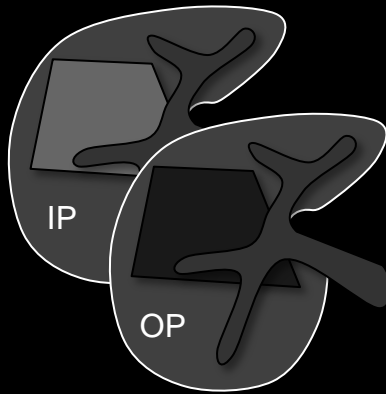


Geographic hepatic steatosis (not mass)

Mass with similar fractional fat content as background steatotic liver

*Observation does not have higher fractional fat content than background steatotic liver*

Not intra-lesional fat



**Intra-lesional fat:** As illustrated in schematic diagrams of out-of-phase (OP) and in-phase (IP) gradient echo MR images, intra-lesional fat refers to presence of lipid in higher concentration within a mass, in whole (top left, top right) or in part (top center), than in background liver. Background liver may be non-steatotic (top left, top center) or steatotic (top right). Intra-lesional fat does not apply to focal or heterogeneous hepatic steatosis (bottom left) or to masses with similar or lower fractional fat content than background steatotic liver (bottom right). IP = in phase. OP = out of phase.



## Iron-rich cirrhosis-associated nodule = “siderotic nodule”

[Cirrhosis-associated nodule](#) with higher iron concentration than surrounding parenchyma. Histologically, iron-rich cirrhosis-associated nodules usually represent cirrhotic (regenerative) or dysplastic nodules. As imaging cannot reliably differentiate non-dysplastic from dysplastic iron-rich nodules, iron-rich nodules should be categorized LR2 or greater as follows:

### LI-RADS Categorization:

[LR2 Iron-Rich Cirrhosis-Associated Nodules](#)

[LR≥3 Iron-Rich Cirrhosis-Associated Nodules](#)

[Pitfalls, Challenges, Differential Diagnosis](#)

[Other Comments](#)



## Iron-rich cirrhosis-associated nodule = “siderotic nodule”

### LR2 Iron-Rich Cirrhosis-Associated Nodules:

- Iron-rich cirrhosis-associated nodules with the imaging features below may be considered probably benign (all of the following):
  - [Diameter < 20mm](#) AND
  - [Homogeneous](#) AND
  - [Iso-enhancement](#) to background cirrhotic nodules in all phases AND
  - Homogeneous moderate or marked T2 or T2\* hypo-intensity, or moderate or marked signal loss on the second echo of a dual-echo imaging acquisition (i.e., have high iron concentration).
- Such iron-rich nodules
  - Should be categorized LR2.
  - Are common in cirrhosis. They range in number from solitary to innumerable; in diffusely iron-overloaded cirrhotic liver, every nodule may be iron rich.
  - Generally do not require LI-RADS reporting. Radiologists at their discretion may report them.



## Iron-rich cirrhosis-associated nodule = “siderotic nodule”

### LR≥3 Iron-Rich Cirrhosis-Associated Nodules:

- Iron-rich nodules that do not meet LR2 criteria cannot be considered probably benign. These include nodules with imaging evidence of high iron concentration and any of the following:
  - [Diameter ≥ 20 mm](#) OR
  - [Heterogeneous](#) in one or more sequences or phases OR
  - Enhancement that differs from liver in one or more phases OR
  - Any [ancillary feature](#) that favors HCC
- Such iron-rich nodules should be categorized [LR3](#), [LR4](#), or [LR5](#) depending on size and other imaging features.
- LR3 iron-rich nodules should be reported if there are no LR4, LR5, or OM observations elsewhere in the liver. If there are LR4, LR5, or OM observations elsewhere in the liver, they may be reported at the radiologist’s discretion.
- LR4 and LR5 iron-rich nodules must be reported.



## Iron-rich cirrhosis-associated nodule = “siderotic nodule”

### Pitfalls, Challenges, Differential Diagnosis:

- Iron-rich nodules can be identified with high specificity at MRI, due to T2/T2\* shortening effects of iron. These nodules are moderately to markedly hypo-intense on T2w or T2\*w images, and they show moderate or marked signal loss on the second echo of dual-echo imaging acquisitions. The degree of hypo-intensity relative to liver is accentuated with longer echo times and, if dual-echo imaging is performed, with greater inter-echo spacing.
- Iron-rich nodules may be hypo-, iso-, or hyper-intense on T1w images with short echo times, depending on their iron content and imaging technique.
- Iron-rich nodules are more difficult to diagnose at CT; while iron causes hyper-attenuation, the hyper-attenuation may be subtle and, even if detected, is not specific for iron deposition.
- Rarely, a focus of HCC may develop within an iron-rich nodule. The development within an iron-rich nodule of an iron-poor (non-siderotic) component (i.e., [nodule-in-nodule](#) architecture) may indicate an incident HCC and should be categorized [LR3](#), [LR4](#), or [LR5](#) depending on other imaging features.





## Iron-rich cirrhosis-associated nodule = “siderotic nodule”

### Other Comments:

- Iron-rich nodules frequently are termed siderotic nodules by radiologists and in the radiology literature.
- The term iron-rich nodule is preferred.
  - **Rationale:** term “siderotic nodule” may have a different meaning in pathology.

**Iso-attenuation:**

Attenuation at CT that is identical or nearly identical to that of liver parenchyma.

**If any portion of the observation differs unequivocally in attenuation from liver:**

- Do not characterize as iso-attenuation.

**If there is equivocal hyper-attenuation or equivocal hypo-attenuation:**

- Characterize as iso-attenuation.

**Comments:**

- May apply to any phase of CT imaging.
- Specifying the phase is necessary.

**Atlas:** CT

**Iso-enhancement:**

Enhancement that is identical or nearly identical to that of liver.

**If any portion of the observation differs unequivocally in enhancement from liver:**

- Do not characterize as iso-enhancement.

**If there is equivocal hyper-enhancement or equivocal hypo-enhancement:**

- Characterize as iso-enhancement.

**Comments:**

- Applies to observations that, after contrast injection:
  - Unequivocally enhance AND
  - Are identical or nearly identical in attenuation or intensity to liver. } in whole
- May apply to [arterial phase](#), [portal venous phase](#), or [delayed phase](#).
- Specifying the phase is necessary.

**Atlas:** CT, MR

**Iso-intensity:**

Signal intensity at MRI that is identical or nearly identical to that of liver parenchyma.

**If any portion of the observation differs unequivocally in intensity from liver:**

- Do not characterize as iso-intensity.

**If there is equivocal hyper-intensity or equivocal hypo-intensity:**

- Characterize as iso-intensity.

**Comments:**

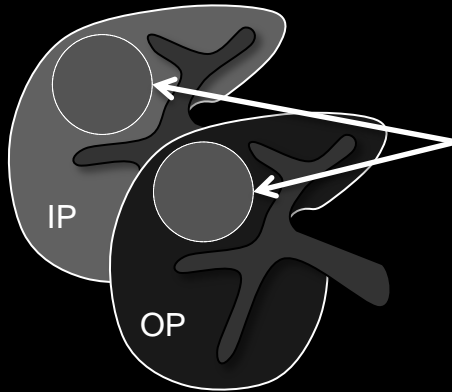
- May apply to any sequence or phase of MR imaging.
- Specifying the sequence or phase is necessary.

**Atlas:** MR

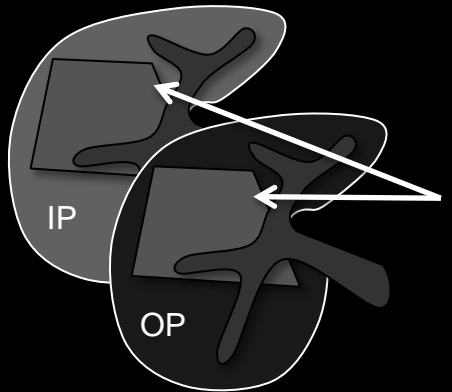


Lesional fat sparing

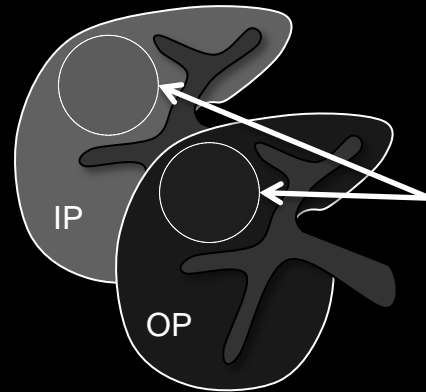
Dual echo GRE



Observation is a mass with lower fractional fat content than liver

Not lesional fat sparing

Observation is not a mass. This is an example of parenchymal hepatic fat sparing.



Observation is a mass which does not have lower fractional fat content than liver

**Lesional fat sparing:**

Relative paucity of fat in solid mass compared to that of background reference tissue (e.g., fatty liver).

**Comments:**

- Applies, in fatty livers, to solid [masses](#) that [unequivocally](#) have lower fractional fat content than background liver.
- Does not apply to benign entities such as [cysts](#), [hemangiomas](#), [confluent fibrosis](#), focal scars.
- In patients at risk for HCC, lesional fat sparing in a solid mass is an [ancillary feature](#) favoring HCC.
- Radiologists at their discretion may apply lesional fat sparing to upgrade category of solid masses (up to LR4).

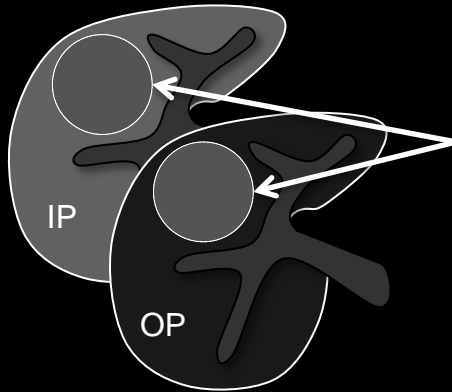
**Lesional fat sparing:** Schematic diagrams illustrate observations with (top row) and without (bottom row) lesional fat sparing on. In each diagram, the background liver is fatty and shows signal loss on out-of-phase (OP) compared to in-phase (IP) MR images. Top row: expansile mass with lesional fat sparing shows less signal loss than liver on the OP compared to the IP image (i.e., it has lower fractional fat content than the liver). Bottom row: geographic area of parenchymal hepatic fat sparing (left) and expansile mass with similar fractional fat content as liver.





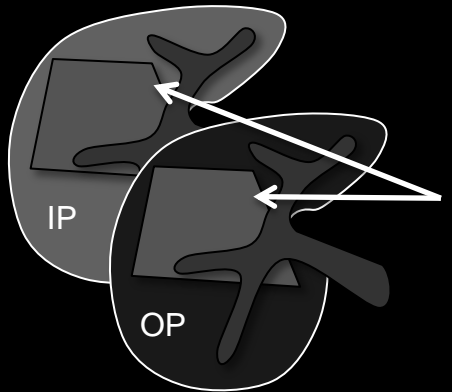
Lesional fat sparing

Dual echo GRE

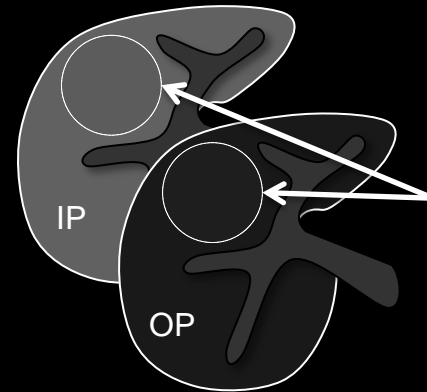


Observation is a mass with lower fractional fat content than liver

Not lesional fat sparing



Observation is not a mass. This is an example of parenchymal hepatic fat sparing.



Observation is a mass which does not have lower fractional fat content than liver

Lesional fat sparing:

Comments (continued):

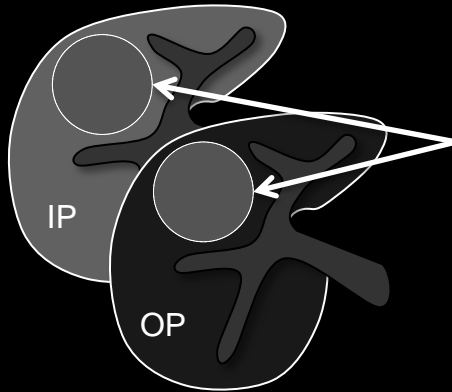
- MRI is more sensitive and specific for detection of lesional fat sparing than CT.
- At MRI, a mass may be characterized as having lesional fat sparing if:
  - The liver shows signal loss on out-of-phase (OP) compared to in-phase (IP) gradient echo images or on fat-suppressed compared to non-fat-suppressed images (i.e., the liver is fatty) AND
  - Compared to background liver, the mass shows less signal loss on OP compared to IP gradient echo images or on fat-suppressed compared to non-fat-suppressed images (i.e., the mass has lower fractional fat content than liver).
- At CT, a mass may be characterized as having lesional fat sparing if:
  - The attenuation of the liver measures  $\leq 40$  HU (on unenhanced or enhanced images) or  $\geq 10$  HU less than that of spleen (on unenhanced images) (i.e., liver is fatty) AND
  - The mass has greater attenuation than the liver (i.e., the mass has lower fractional fat content than liver).

**Lesional fat sparing:** Schematic diagrams illustrate observations with (top row) and without (bottom row) lesional fat sparing on. In each diagram, the background liver is fatty and shows signal loss on out-of-phase (OP) compared to in-phase (IP) MR images. Top row: expansile mass with lesional fat sparing shows less signal loss than liver on the OP compared to the IP image (i.e., it has lower fractional fat content than the liver). Bottom row: geographic area of parenchymal hepatic fat sparing (left) and expansile mass with similar fractional fat content as liver.



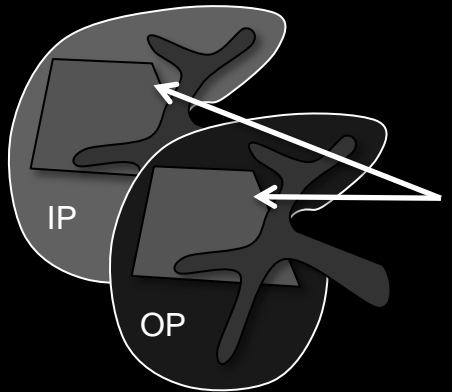
Lesional fat sparing

Dual echo GRE

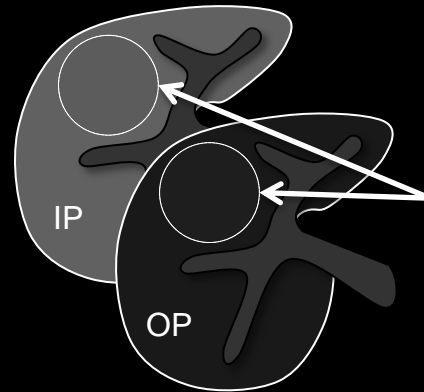


Observation is a mass with lower fractional fat content than liver

Not lesional fat sparing



Observation is not a mass. This is an example of parenchymal hepatic fat sparing.



Observation is a mass which does not have lower fractional fat content than liver

Lesional fat sparing:

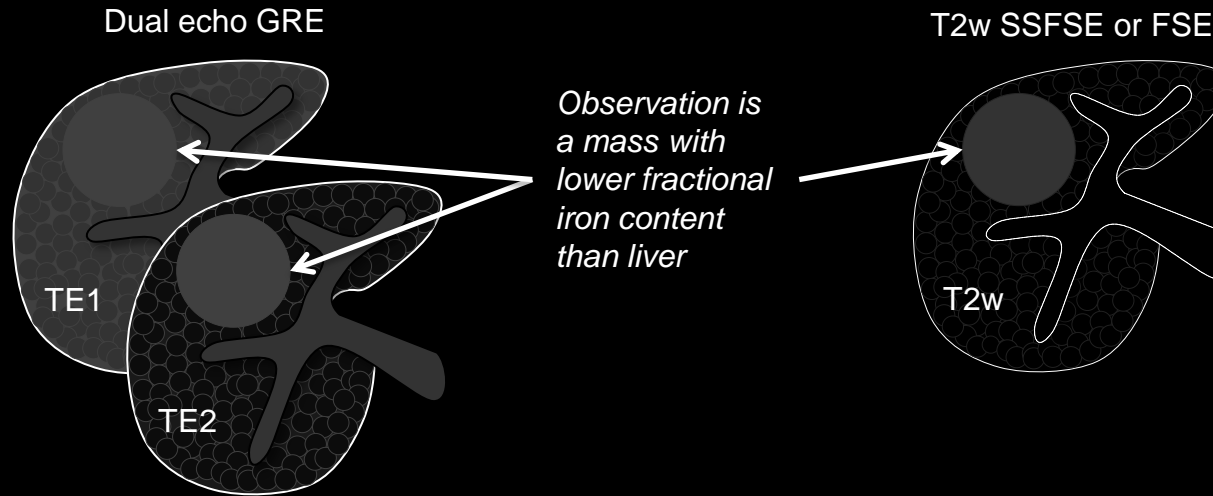
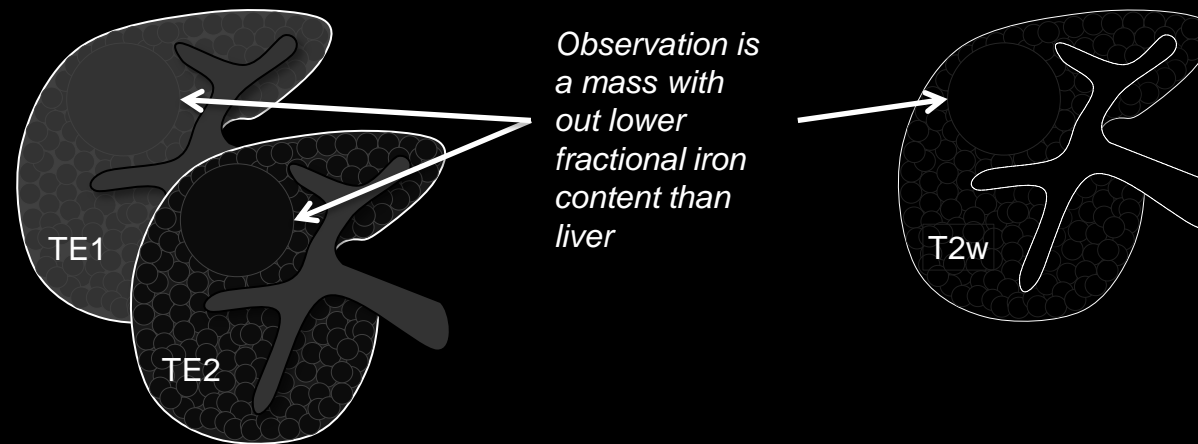
Comments (continued):

- Lesional fat sparing needs to be differentiated from parenchymal [hepatic fat sparing](#).
- Imaging features that, if present, favor lesional fat sparing over parenchymal hepatic fat sparing include:
  - Observation is a [mass](#) AND
  - Enhancement differs from that of background liver in one or more post-contrast phases and the difference is not attributable to a [perfusion alteration](#)
- Multiplanar images (source or reformatted) may help correctly characterize observations as having lesional sparing fat by showing that the observation is a [mass](#).

**Lesional fat sparing:** Schematic diagrams illustrate observations with (top row) and without (bottom row) lesional fat sparing on. In each diagram, the background liver is fatty and shows signal loss on out-of-phase (OP) compared to in-phase (IP) MR images. Top row: expansile mass with lesional fat sparing shows less signal loss than liver on the OP compared to the IP image (i.e., it has lower fractional fat content than the liver). Bottom row: geographic area of parenchymal hepatic fat sparing (left) and expansile mass with similar fractional fat content as liver.



Lesional iron sparing

Not lesional iron sparing**Lesional iron sparing**

Relative paucity of iron in solid mass compared to that of background reference tissue (e.g. iron-overloaded liver).

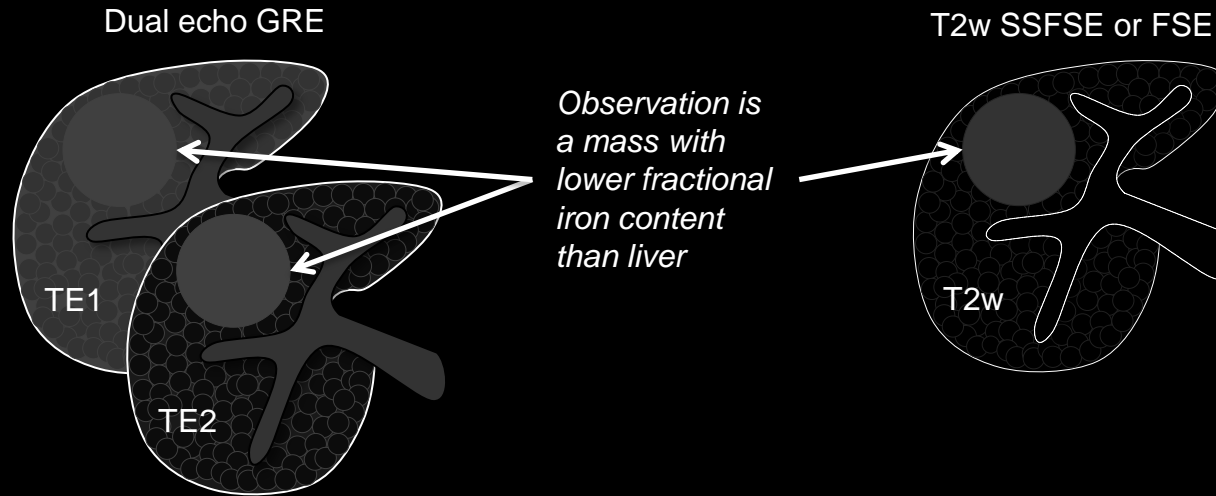
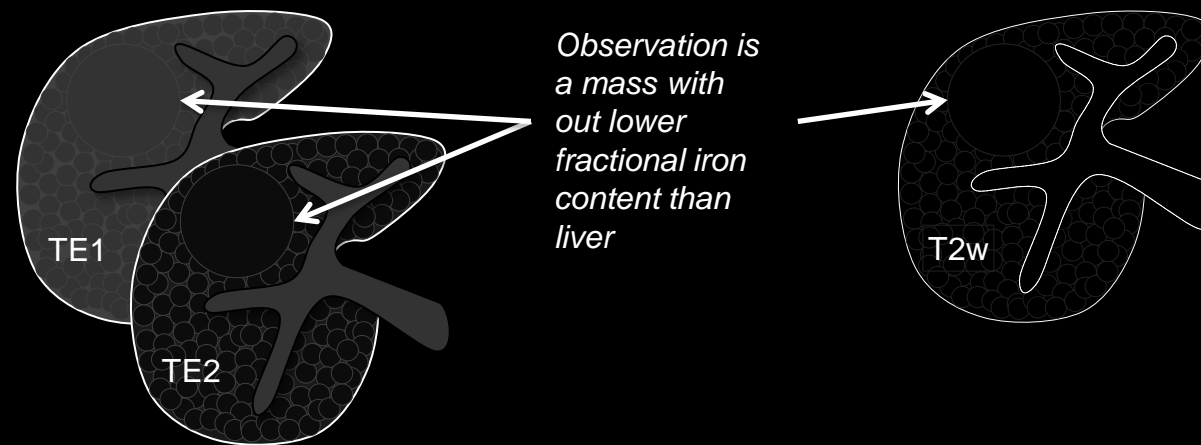
**Comments:**

- Applies, in iron-overloaded livers, to solid [masses](#) that [unequivocally](#) have lower fractional iron content than background liver.
- Does not apply to benign entities such as [cysts](#), [hemangiomas](#), [confluent fibrosis](#), [focal scars](#).
- Lesional iron sparing in a solid mass is an [ancillary feature](#) favoring HCC.
- Radiologists at their discretion may apply lesional iron sparing to upgrade the category of solid masses (up to LR4).

**Lesional iron sparing:** Schematic diagrams illustrate observations with (top row) and without (bottom row) lesional iron sparing. In these schematics, liver is composed of iron-overloaded cirrhosis-associated nodules (tiny dark nodules) surrounded by cirrhotic fibrous septa (light gray borders around the nodules).



Lesional iron sparing

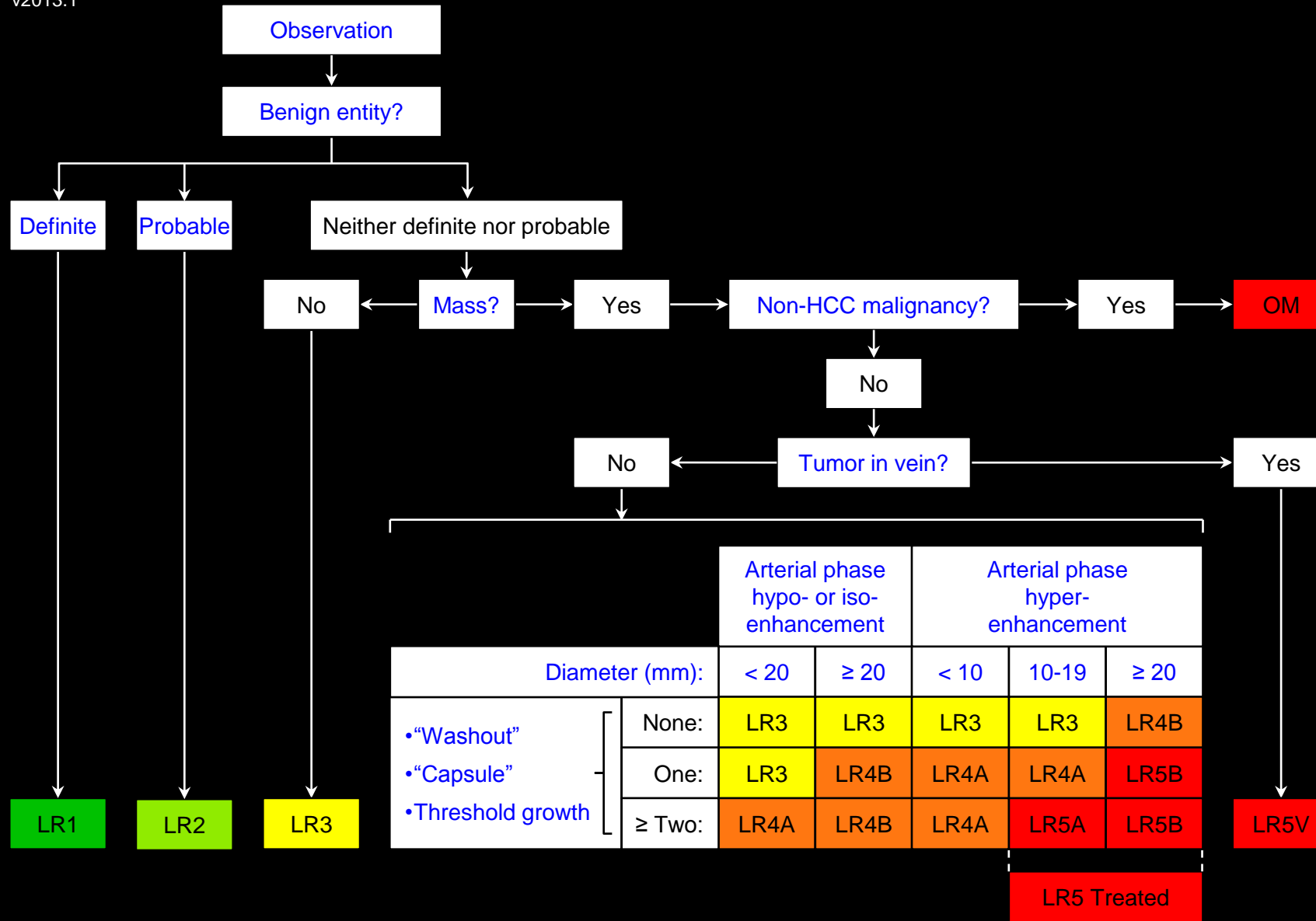
Not lesional iron sparing

## Lesional iron sparing

## Comments (continued):

- MRI is more sensitive and specific for detection of lesional iron sparing than CT.
- At MRI, a mass may be characterized as having lesional iron sparing if:
  - The liver shows signal loss on the second echo of a dual-echo sequence or is more hypo-intense than normal on T2w or T2\*w images (i.e., liver is iron overloaded) AND
  - Relative to the liver, the mass shows less signal loss on the the second echo of a dual-echo sequence and the mass is less hypo-intense on T2w or T2\*w images (i.e., the mass has lower fractional iron content than the liver). The difference in signal intensity between the mass and the liver is more pronounced with longer echo times and, if dual-echo imaging is performed, with greater echo spacing.
- At CT, a mass may be characterized as having lesional iron sparing if:
  - The liver has greater attenuation than normal (e.g., hepatic attenuation > 75HU) on unenhanced images (i.e., the liver is iron overloaded) AND
  - Relative to the liver, the mass is less hyper-attenuating (i.e., the mass has lower fractional iron content than the liver).

**Lesional iron sparing:** Schematic diagrams illustrate observations with (top row) and without (bottom row) lesional iron sparing. In these schematics, liver is composed of iron-overloaded cirrhosis-associated nodules (tiny dark nodules) surrounded by cirrhotic fibrous septa (light gray borders around the nodules).



Apply [Ancillary Features](#) and then [Tie-Breaking Rules](#) to Adjust Category

## LR1: Definitely Benign

### Concept:

100% certainty observation is benign.

### Definition:

Observation with:

- Imaging features [diagnostic](#) of a [benign entity](#) OR
- [Definite disappearance](#) at follow up in the absence of treatment.

### Examples:

Observations that may be categorized as LR1: [definite benign entities](#).

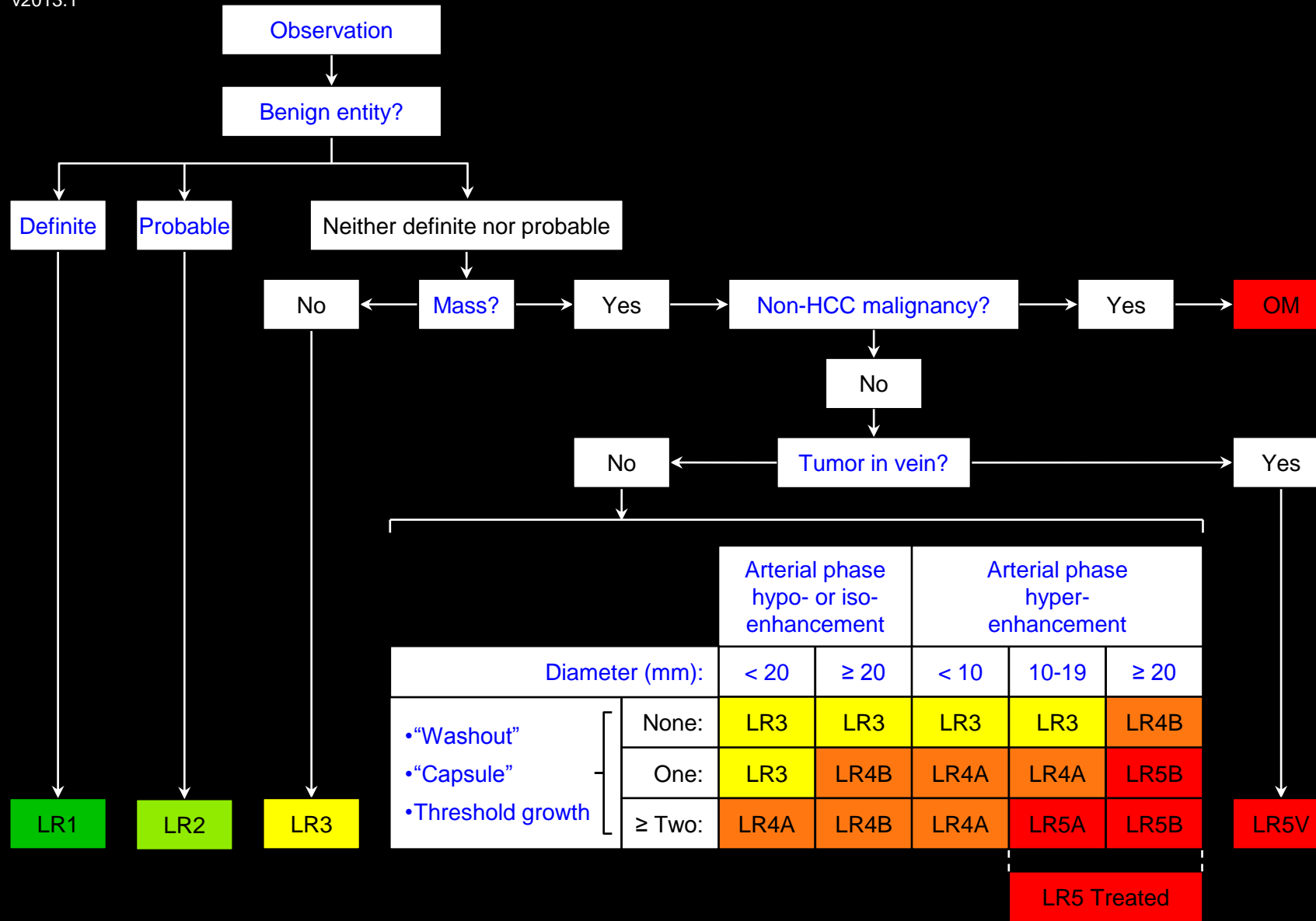
### Reporting:

- LR1 observations may be reported at radiologist's discretion. If they are reported, they may be reported in aggregate.
- Exception: LR1 observations that on the previous examination were reported as LR3, LR4, or LR5 usually should be reported. If they are reported, it may be more appropriate to report them individually rather than in aggregate.
  - Rationale:** The interval downgrade in category may alter management or prognosis.

### [Management](#)

**Atlas:** CT, MR



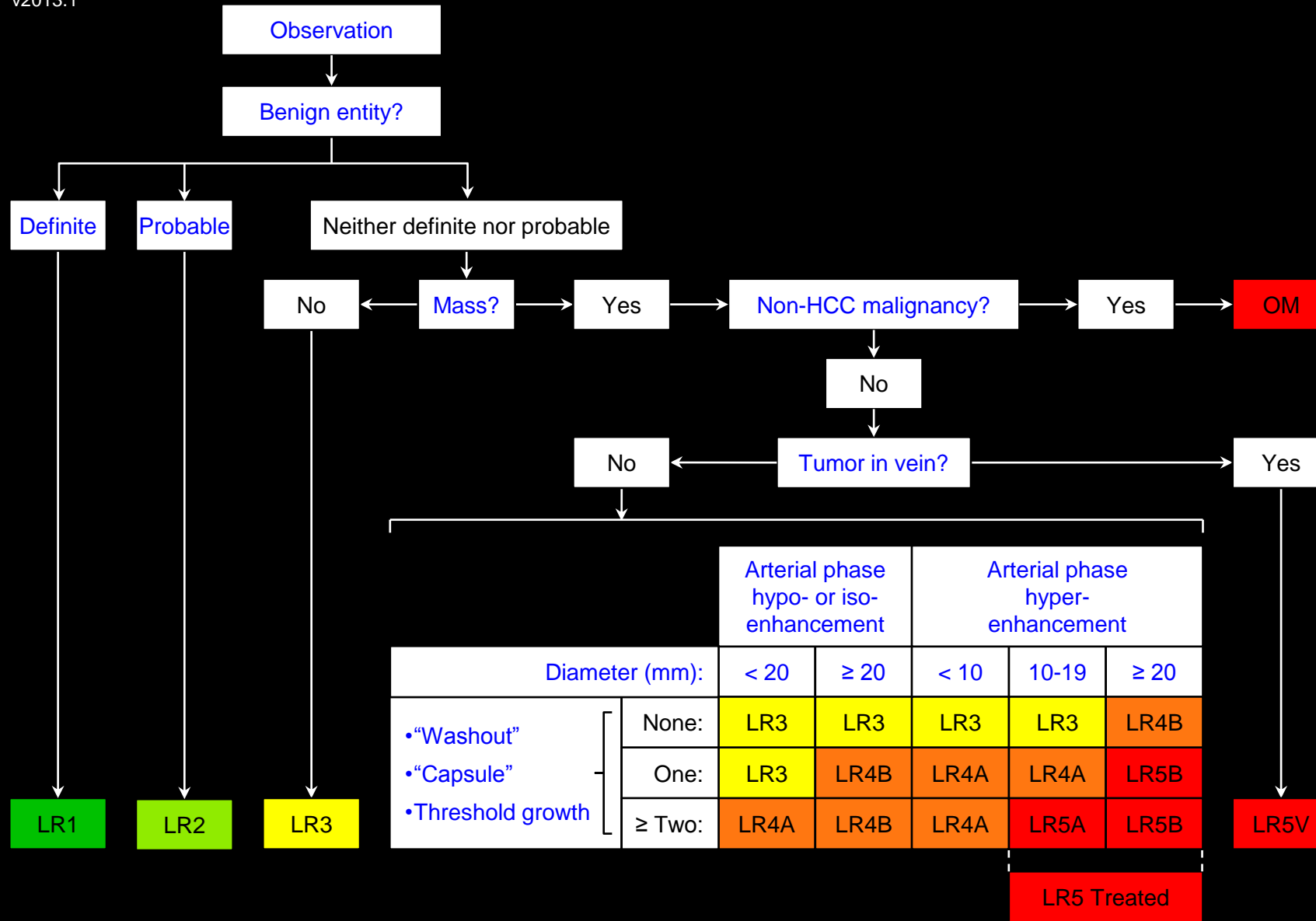


Apply Ancillary Features and then Tie-Breaking Rules to Adjust Category

LR1: Definitely Benign

**Management:**

Continued routine surveillance usually is appropriate.



Apply [Ancillary Features](#) and then [Tie-Breaking Rules](#) to Adjust Category

## LR2: Probably Benign

### Concept:

High probability observation is benign.

### Definition:

Observation with imaging features [suggestive](#) but not [diagnostic](#) of a [benign entity](#).

### Examples:

Observations that may be categorized as LR2: [probable benign entities](#).

### Reporting:

- LR2 observations may be reported at radiologist's discretion. If they are reported, they may be reported in aggregate.
- Exception: LR2 observations that on the previous examination were reported as LR3, LR4, or LR5 usually should be reported. If they are reported, it may be more appropriate to report them individually rather than in aggregate.
  - **Rationale:** The interval downgrade in category may alter management or prognosis.

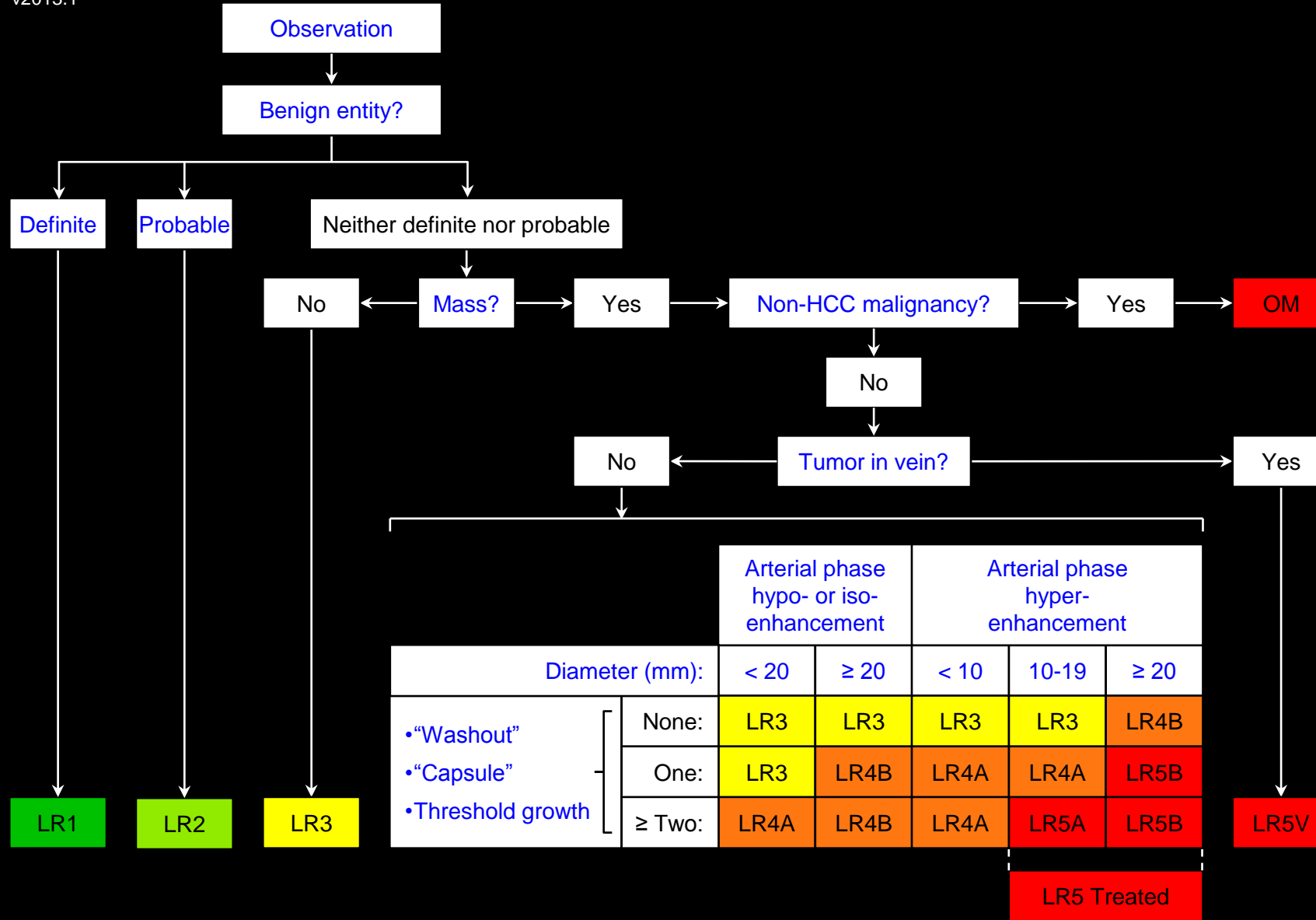
### Management:

Continued routine surveillance usually is appropriate.

**Atlas:** CT, MR



## LR3: Intermediate Probability for HCC



Apply Ancillary Features and then Tie-Breaking Rules to Adjust Category

### Concept:

Both HCC and benign entity have moderate probability.

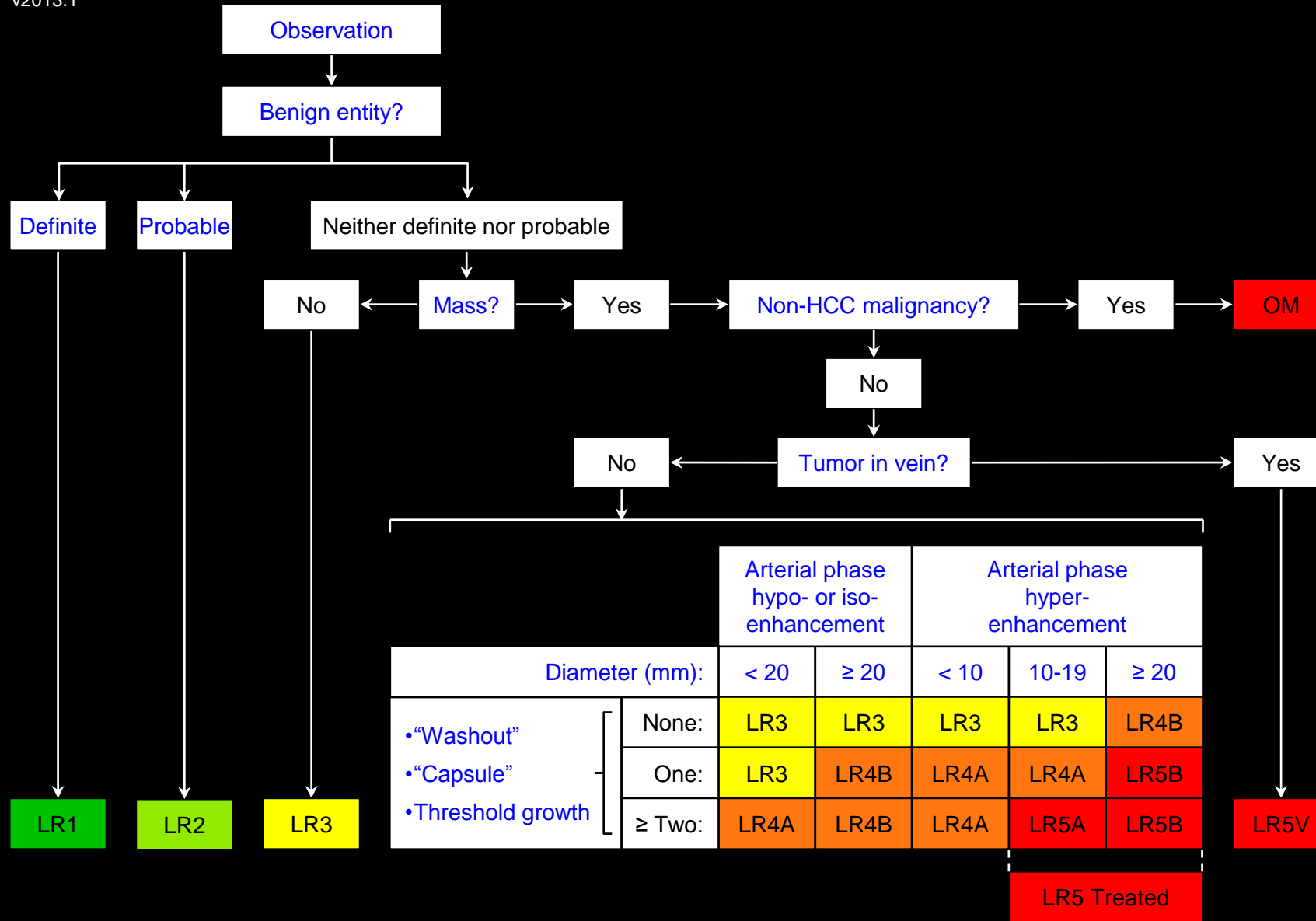
### Definition:

Observation that does not meet criteria for other LI-RADS categories.

### Criteria (any of the following):

Not [definite benign entity](#), not [probable benign entity](#), not [non-HCC malignancy](#), and one of the following:

- Not [definite mass](#)
- Includes [nodule-like hepatic arterial phase hyper-enhancement \(NAPH\)](#)
- [Mass](#) with [hepatic arterial phase hypo- or iso-enhancement](#)
  - [< 20mm](#) mass with ≤ 1 of following: ["washout"](#), ["capsule"](#), [threshold growth](#)
  - [≥ 20mm](#) mass with none of following: ["washout"](#), ["capsule"](#), [threshold growth](#)
- [Mass](#) with [hepatic arterial phase hyper-enhancement](#)
  - [< 20mm](#) mass with none of following: ["washout"](#), ["capsule"](#), [threshold growth](#)



Apply Ancillary Features and then Tie-Breaking Rules to Adjust Category

## LR3: Intermediate Probability for HCC

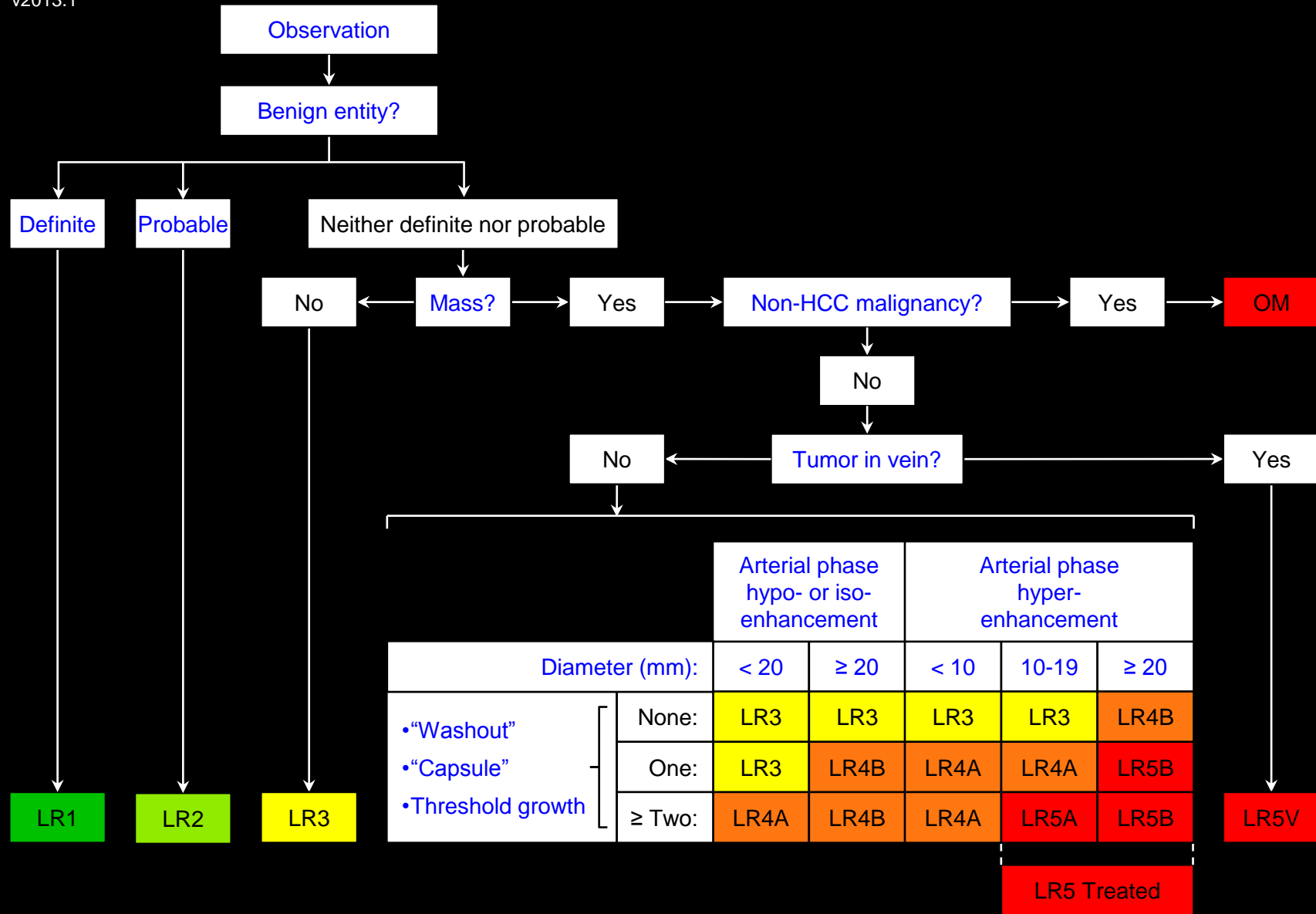
### Reporting:

The reporting of observations categorized LR3 depends on the presence of LR4, LR5, or OM observations elsewhere in the liver:

- If there are no LR4, LR5, or OM observations: LR3 observations should be reported.
- If LR4, LR5, or OM observations are present: LR3 observations may be reported at radiologist's discretion.
- If LR3 observations are reported, they may be reported in aggregate.
- Exception: LR3 observations that on the previous examination were reported as LR4 or LR5 usually should be reported, regardless of the presence of LR4, LR5, or OM observations elsewhere in the liver. If they are reported, it may be more appropriate to report them individually rather than in aggregate.
  - **Rationale:** The interval downgrade in category may alter management or prognosis.

### Management:

Variable follow-up (depends on observation size, stability, and clinical considerations).



Apply Ancillary Features and then Tie-Breaking Rules to Adjust Category

## LR4: Probably HCC

### Concept:

High probability observation is HCC but there is not 100% certainty.

### Definition:

Observation with imaging features suggestive but not diagnostic of HCC.

### Criteria:

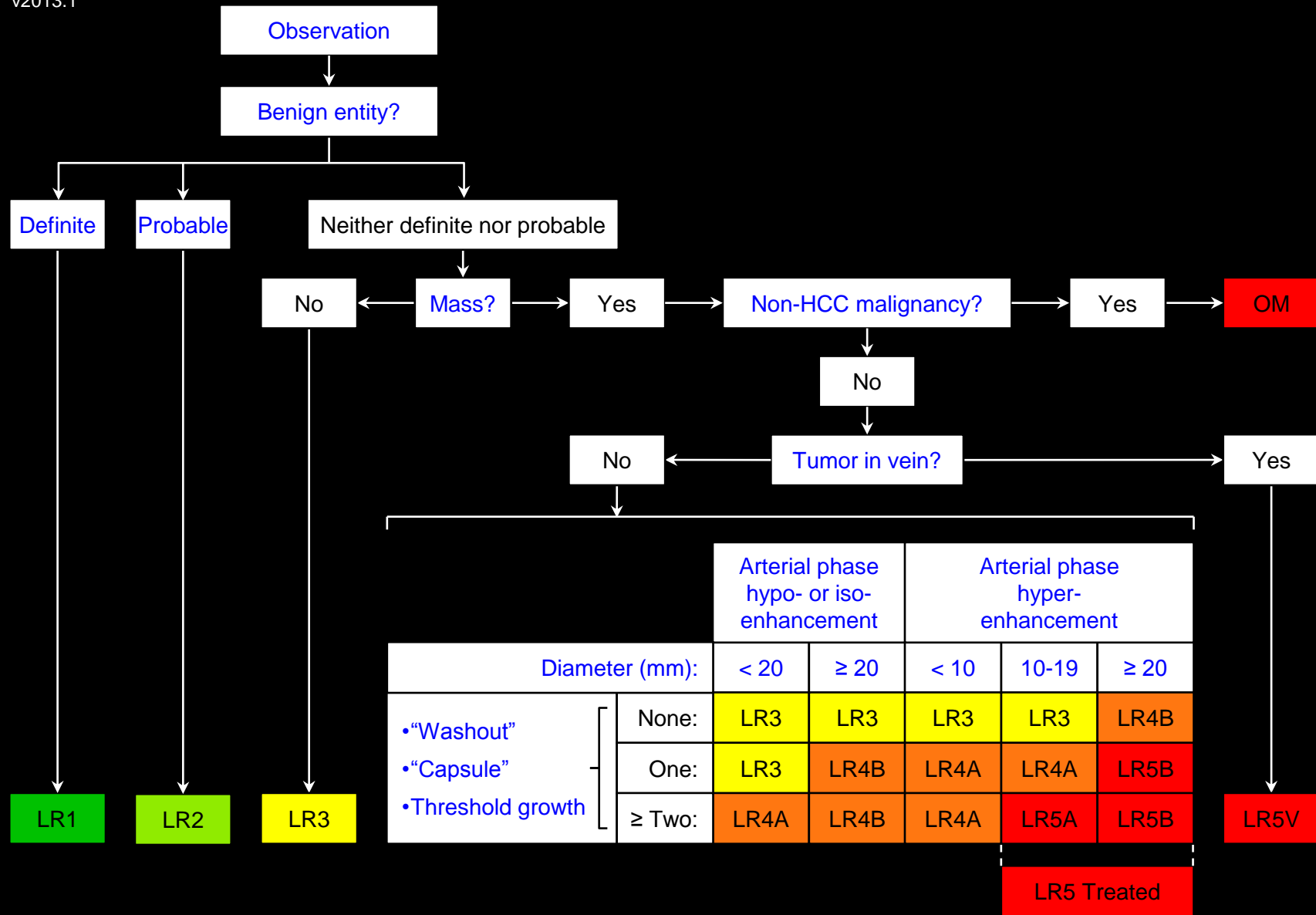
Not definite benign entity, not probable benign entity, not non-HCC malignancy, and as follows:

#### LR 4A (< 20mm mass)

- Mass with arterial phase hypo- or iso-enhancement
  - ≥ 2 of following: "washout", "capsule", threshold growth
- Mass with arterial phase hyper-enhancement
  - < 10mm mass with ≥ 1 of following: "washout", "capsule", threshold growth OR
  - 10-19mm mass with only 1 of following: "washout", "capsule", threshold growth

#### LR 4B (≥ 20mm mass)





Apply **Ancillary Features** and then **Tie-Breaking Rules** to Adjust Category

LR4: Probably HCC

**Criteria (continued):**

**LR 4B (≥ 20mm mass)**

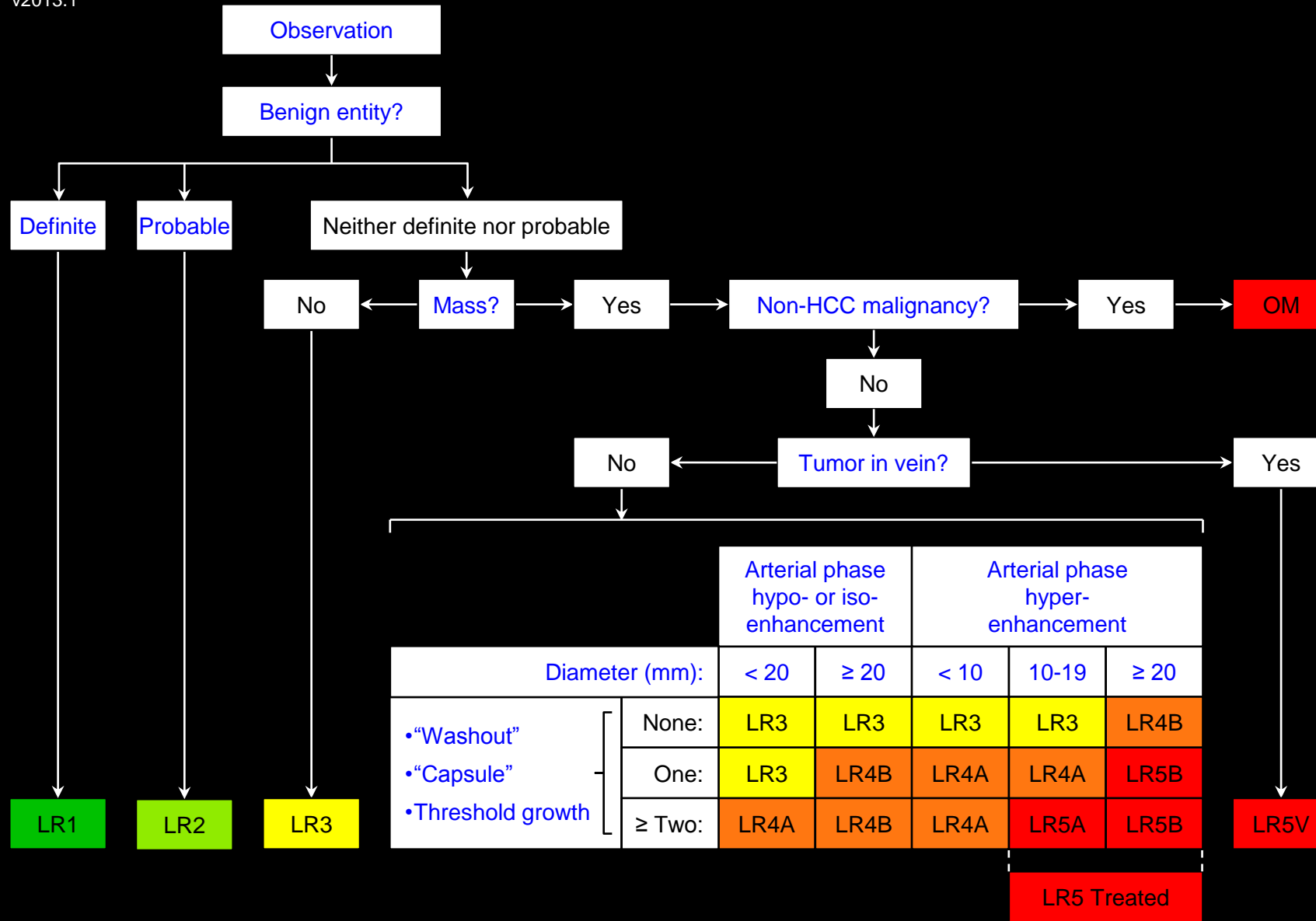
- **Mass** with [arterial phase hypo- or iso-enhancement](#)
- ≥ 1 of following: ["washout"](#), ["capsule"](#), [threshold growth](#)
- **Mass** with [arterial phase hyper-enhancement](#)
- None of following: ["washout"](#), ["capsule"](#), [threshold growth](#)

**Reporting:**

Must be reported.

**Management:**

- Close follow up, additional imaging, biopsy, or treatment (loco-regional treatment, sub-total hepatic resection) may be appropriate.
- Does not contribute to [radiologic T-staging](#) unless multiple LR4 observations are present that individually do not meet LR5 criteria but in aggregate are interpreted as multifocal (T-stage 4a) HCC.
- Does not provide HCC exception points for determining priority on liver transplantation list.



Apply Ancillary Features and then Tie-Breaking Rules to Adjust Category

## LR5: Definitely HCC

### Concept:

100% certainty observation is HCC. LR5 is essentially equivalent to [OPTN 5](#).

### Definition:

Observation with imaging features [diagnostic](#) of HCC or proven to be HCC at histology.

### Criteria:

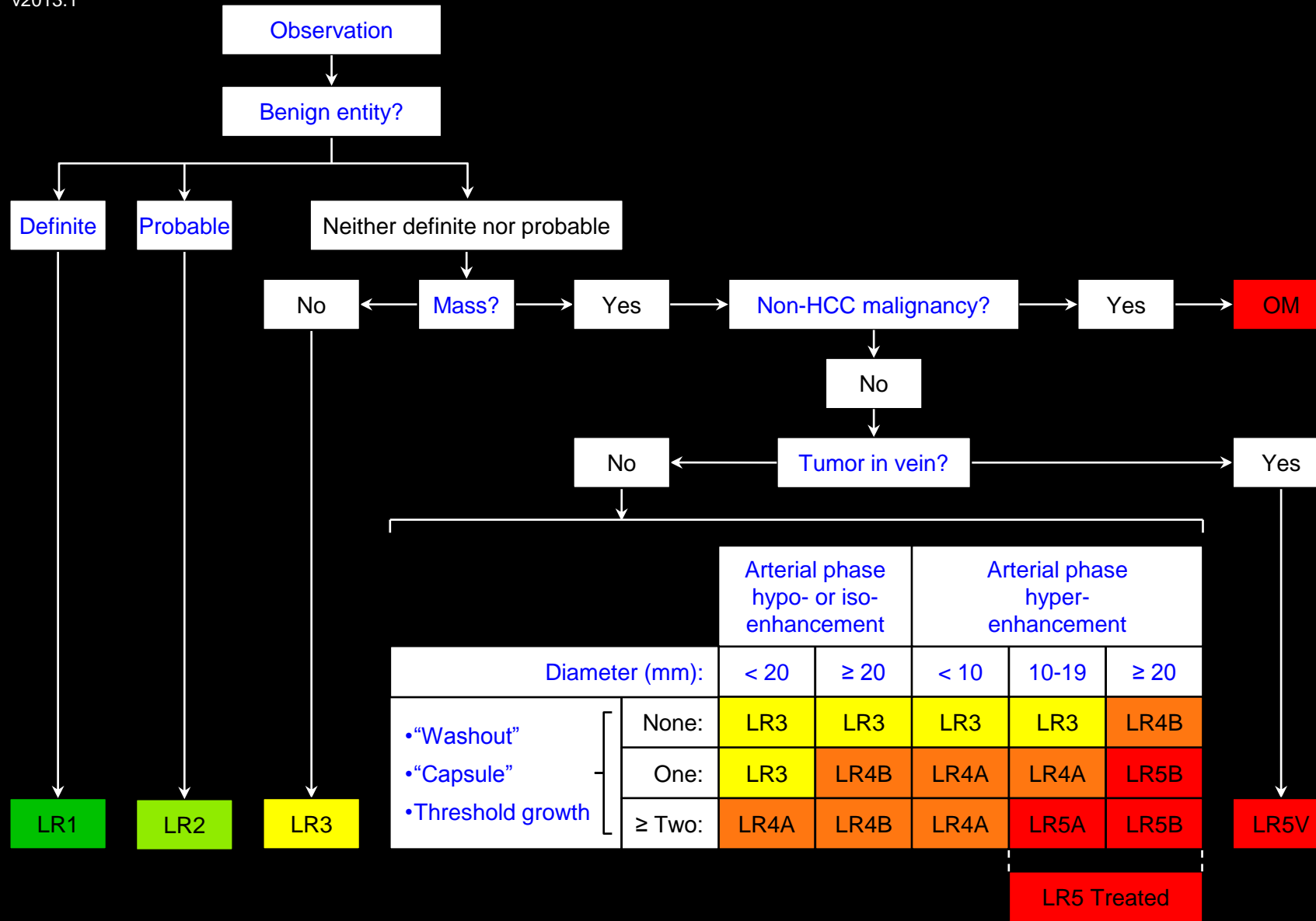
Not [definite benign entity](#), not [probable benign entity](#), not [non-HCC malignancy](#), and as follows:

#### LR 5A (10-19mm mass)

- [Mass](#) with [arterial phase hyper-enhancement](#)
- [10-19mm](#) mass with ≥ 2 of following: [“washout”](#), [“capsule”](#), [threshold growth](#)

#### LR 5B (≥ 20mm mass)

- [Mass](#) with [arterial phase hyper-enhancement](#)
- [≥ 20mm](#) mass with ≥ 1 of following: [“washout”](#), [“capsule”](#), [threshold growth](#)



Apply Ancillary Features and then Tie-Breaking Rules to Adjust Category

LR5: Definitely HCC

### Reporting:

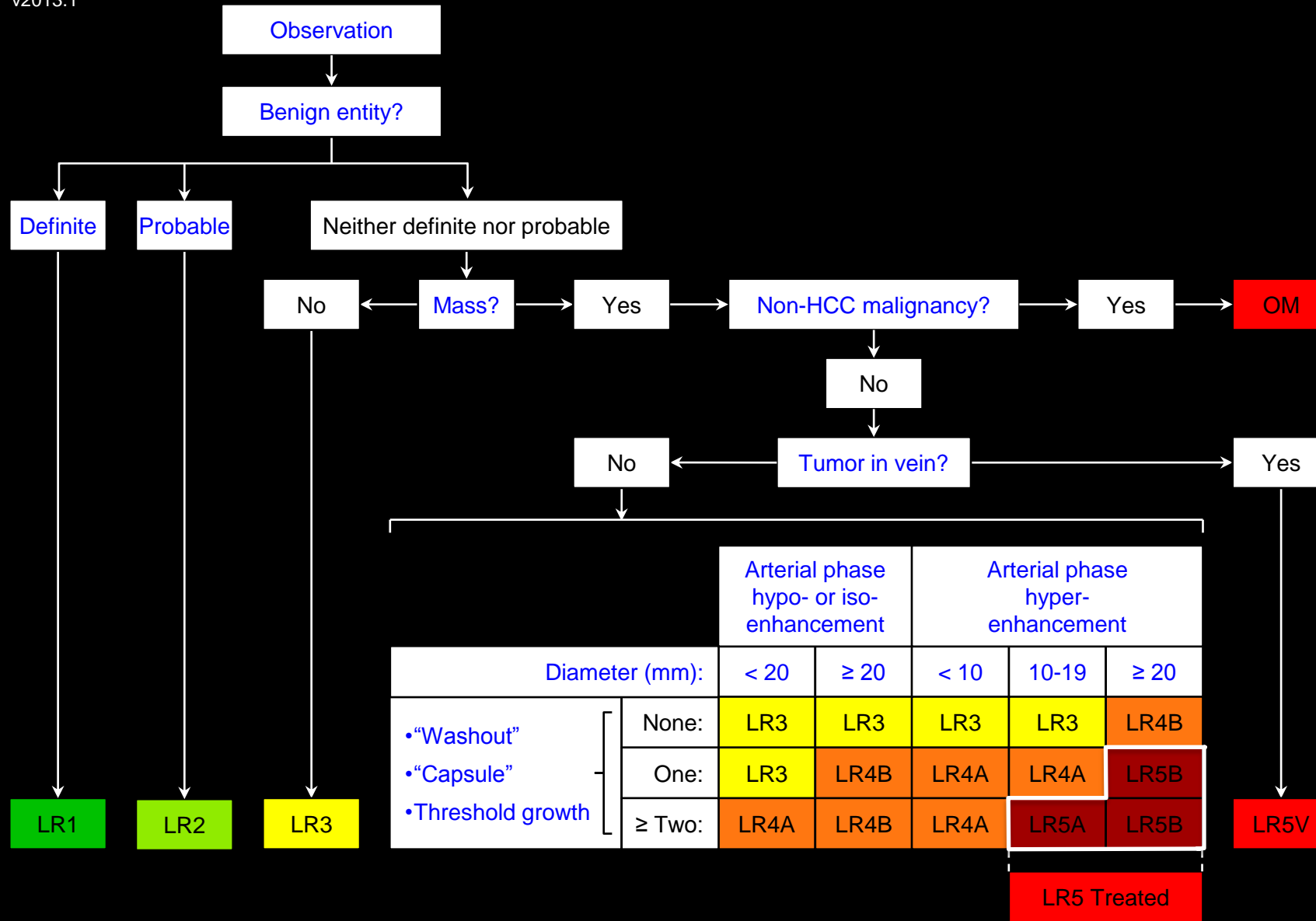
Must be reported.

### Management:

- Treatment without biopsy is appropriate.
- Contributes to [radiologic T-staging](#).
- May provide HCC exception points for determining priority on liver transplantation list. See OPTN policy 3.6.4.4.

### Comments:

- Note that LR5 observations must have [diameter](#) ≥ 10mm.
- **Rationale:** < 10mm masses are unlikely to be HCC, difficult to characterize at CT and MRI and, if resection/explantation is performed, difficult to co-localize on imaging and pathology. Hence, < 10mm masses cannot be diagnosed at CT or MRI with 100% certainty as HCC. Close follow-up will allow LR5A categorization once diameter exceeds 10 mm.
- This also maintains congruency with OPTN classification, which does not allow <10mm masses to be classified [OPTN 5](#).



Apply Ancillary Features and then Tie-Breaking Rules to Adjust Category

## LR5 Treated: Treated HCC

### Concept:

A loco-regionally treated HCC.

### Definition:

LR5A or 5B observation or biopsy-proven HCC lesion that has undergone loco-regional [treatment](#) (i.e., was ablated or embolized).

### Reporting:

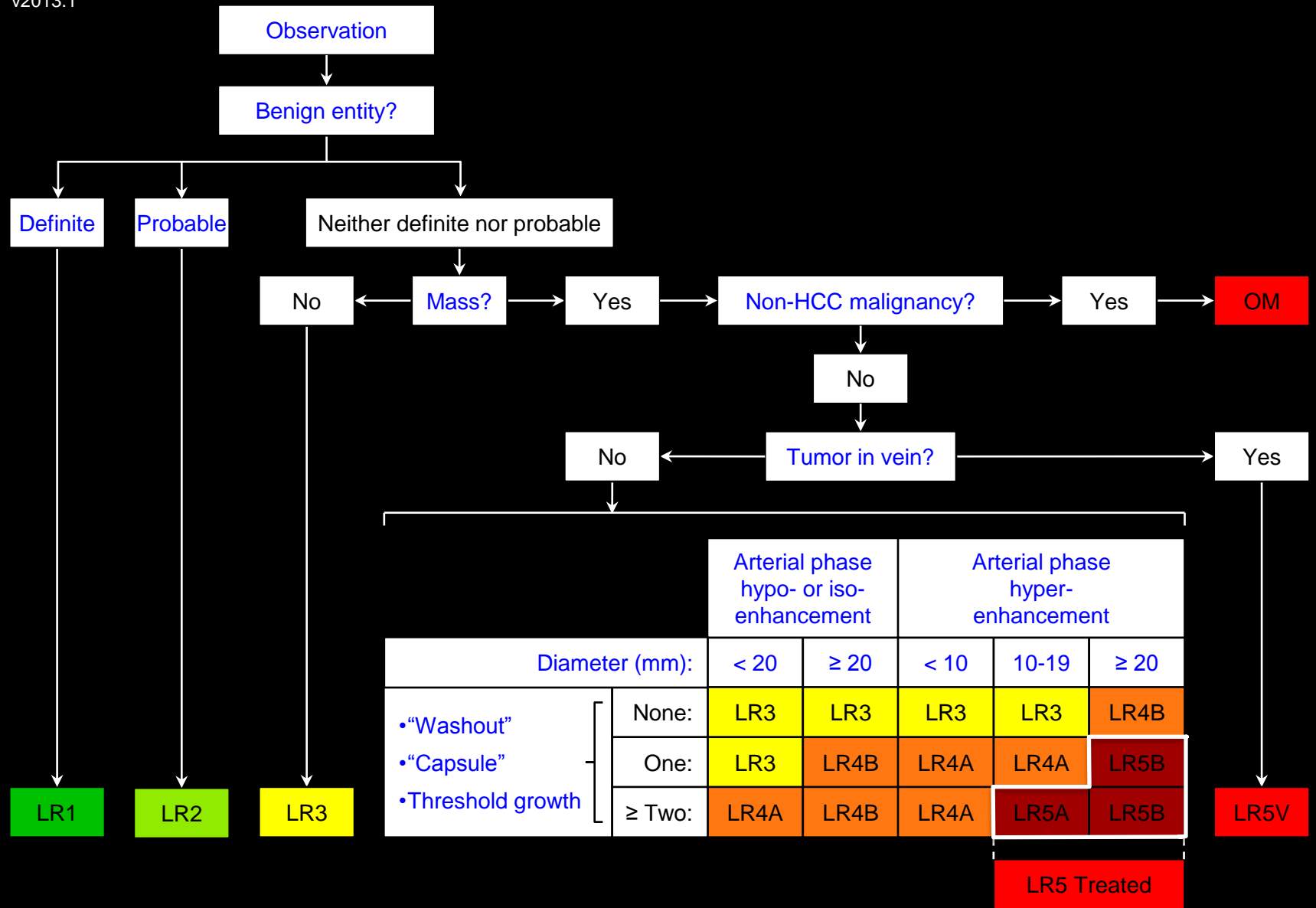
Must be reported.

### Management:

- LR5 Treated observations require close follow up to assess treatment response.
- If close follow up indicates persistent/recurrent tumor, LR5 Treated observations may require re-treatment.
- LR5 Treated observations qualify for continued priority points predicated on their pre-treatment categorization. See OPTN policy 3.6.4.4.

### Criteria for assessing treatment response:

- These criteria are in development.



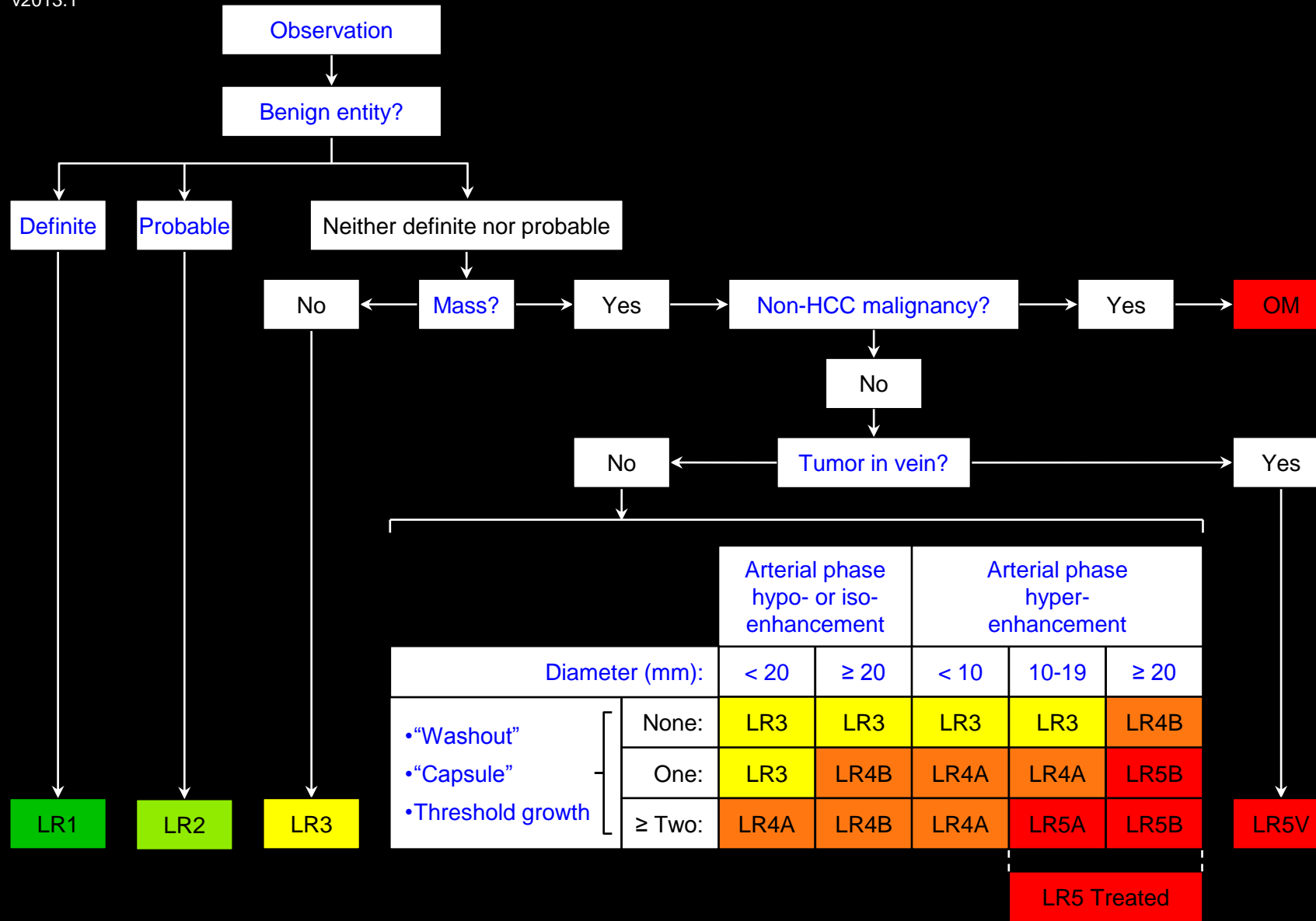
Apply Ancillary Features and then Tie-Breaking Rules to Adjust Category

LR5 Treated: Treated HCC

**Comments:**

- LR 5 Treated applies only to LR5 observations or biopsy-proven HCCs that were ablated or located within a region of the liver that was embolized.
- To maintain congruency between LI-RADS and OPTN, LR5 Treated does not apply to
  - LR≤4 observations that have undergone loco-regional treatment.
  - Observations treated only with systemic therapies.
  - Observations that have been resected.
  - Observations located outside the ablation zone or embolization field.
- LR5 Treated does not imply that loco-regional treatment was successful or that residual or recurrent HCC is absent.
- Observations undergoing systemic therapy should be assigned their pre-treatment LI-RADS category regardless of treatment-related changes in imaging features; the pre-treatment LI-RADS category should not be downgraded.





Apply Ancillary Features and then Tie-Breaking Rules to Adjust Category

**LR5V: Definitely HCC with Tumor in vein**

**Concept:**

100% certainty observation is HCC invading vein.

**Definition:**

Observation with imaging features diagnostic of HCC invading vein.

**Criterion:**

Definite enhancing soft tissue in vein.

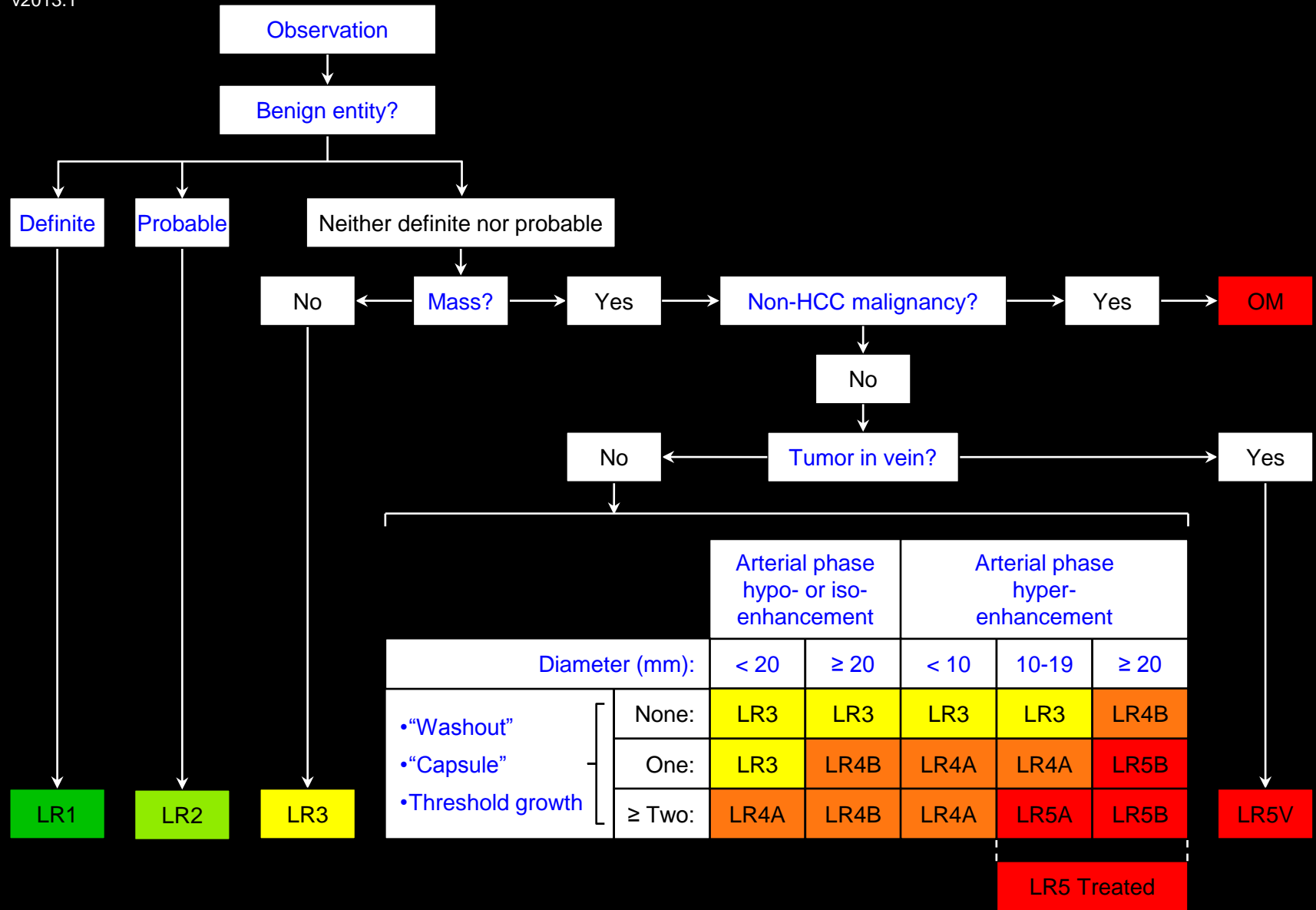
**Reporting:**

Must be reported.

**Management:**

- Treatment without biopsy is appropriate.
- Denotes radiologic T-stage 4b.
- Contra-indication to liver transplantation.

Comments

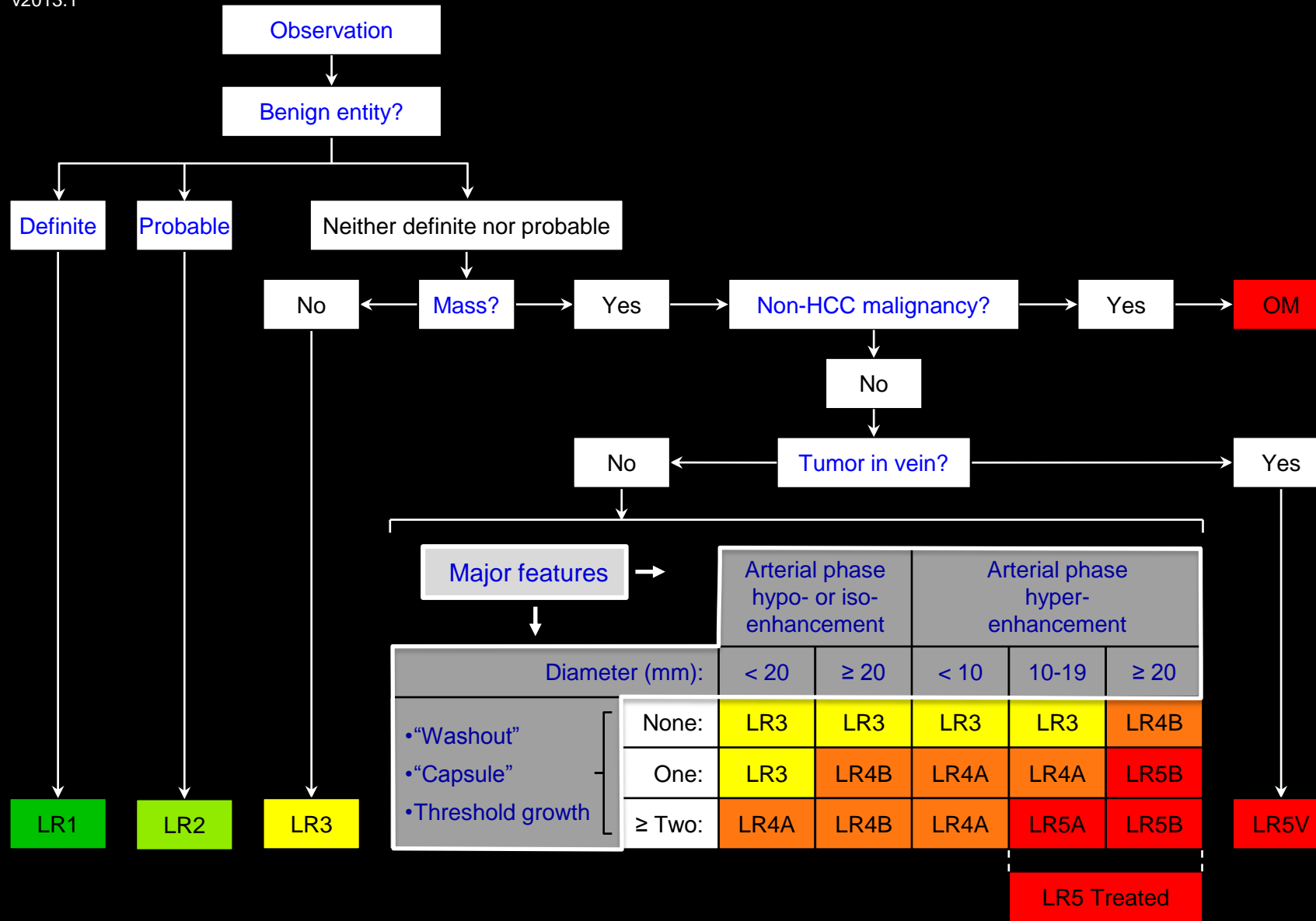


Apply Ancillary Features and then Tie-Breaking Rules to Adjust Category

LR5V: Definitely HCC with Tumor in vein

**Comments:**

- LR5V applies even if parenchymal component of mass is not identified at imaging.
- The term tumor in vein is preferred over the term tumor thrombus.
- **Rationale:** the pathological spectrum ranges from thrombus with scant tumor cells to solid tumor with scant thrombus.
- While not diagnostic of tumor in vein, features that may alert radiologist to diagnosis include:
  - Occluded vein with any of the following:
    - Moderately to markedly expanded lumen
    - Ill-defined walls
    - Restricted diffusion
    - Contiguity with LR5 observation
  - Obscured, partially visualized vein
  - Heterogeneous enhancement of vein not attributable to mixing artifact
- By comparison, non-tumoral bland thrombus does not enhance and usually does not expand lumen to same degree as tumor in vein.



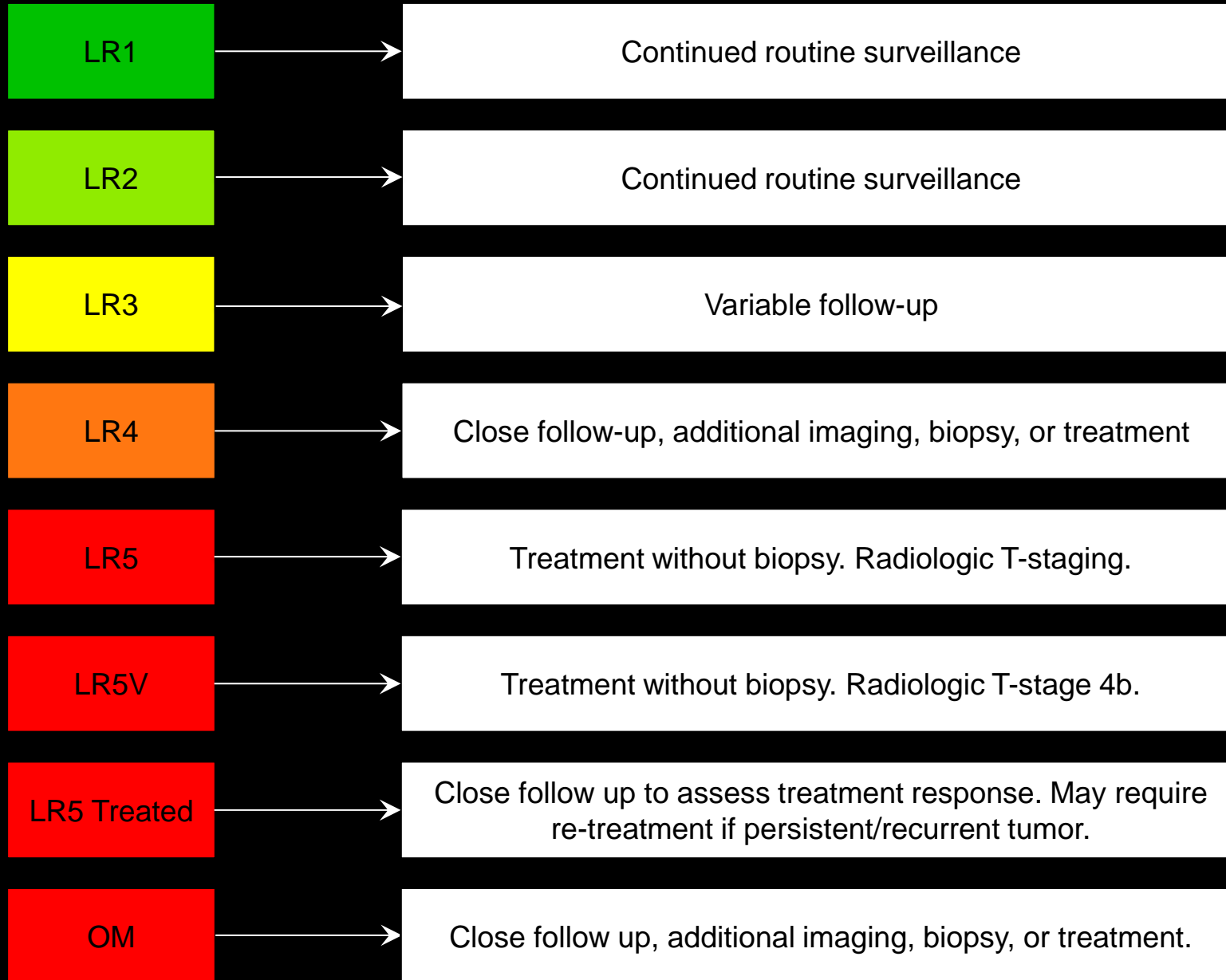
Apply Ancillary Features and then Tie-Breaking Rules to Adjust Category

## Major Features:

Imaging features used to categorize [LR3](#), [LR4](#), or [LR5](#) masses.

## Comments:

- Major features are applied to masses that are neither [definite benign entities](#) nor [probable benign entities](#) and that lack features of [non-HCC malignancy](#) or [tumor in vein](#).
- Major features include:
  - [Arterial phase](#) features:
    - [Arterial phase hypo- or iso-enhancement](#)
    - [Arterial phase hyper-enhancement](#)
  - [Diameter](#)
    - For arterial phase hyper-enhancing masses:
      - [Diameter < 10mm](#)
      - [Diameter 10-19mm](#)
      - [Diameter ≥ 20mm](#)
    - For arterial phase hypo- or iso-enhancing masses:
      - [Diameter < 20mm](#)
      - [Diameter ≥ 20mm](#)
  - [Washout appearance](#)
  - [Capsule appearance](#)
  - [Threshold growth](#)



## Management:

### LR1:

- Continued routine surveillance usually is appropriate.

### LR2:

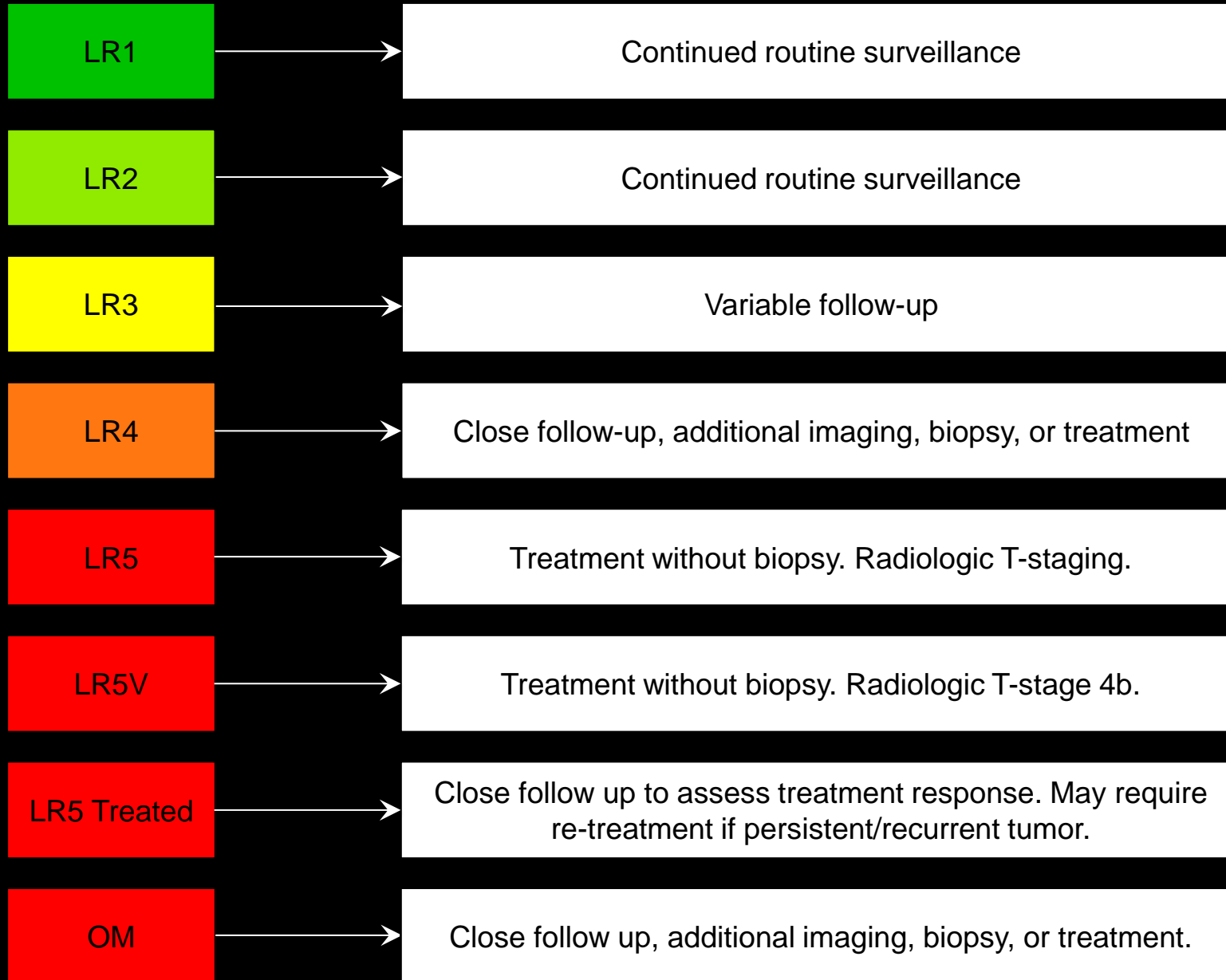
- Continued routine surveillance usually is appropriate.

### LR3:

- Appropriate management is variable, depending mainly on size, stability, and clinical considerations.

### LR4:

- Close follow up, additional imaging, biopsy, or treatment (loco-regional treatment, sub-total hepatic resection) may be appropriate.
- Does not contribute to [radiologic T-staging](#) unless multiple LR4 observations are present that individually do not meet LR5 criteria but in aggregate are interpreted as multifocal (T-stage 4a) HCC.
- Does not provide HCC exception points for determining priority on liver transplantation list.



## Management:

### LR5:

- Treatment without biopsy is appropriate.
- Contributes to [radiologic T-staging](#).
- Essentially equivalent to OPTN Class 5, therefore may provide HCC exception points for determining priority on liver transplantation list (see OPTN policy 3.6.4.4).

### LR5V:

- Treatment without biopsy is appropriate.
- Denotes radiologic T-stage 4b.
- Contra-indication to liver transplantation.

### LR5 Treated:

- LR5 Treated observations require close follow up to assess treatment response.
- If close follow up indicates persistent/recurrent tumor, LR5 Treated observations may require re-treatment.
- LR5 Treated observations qualify for continued priority points predicated on their pre-treatment categorization. See OPTN policy 3.6.4.4.



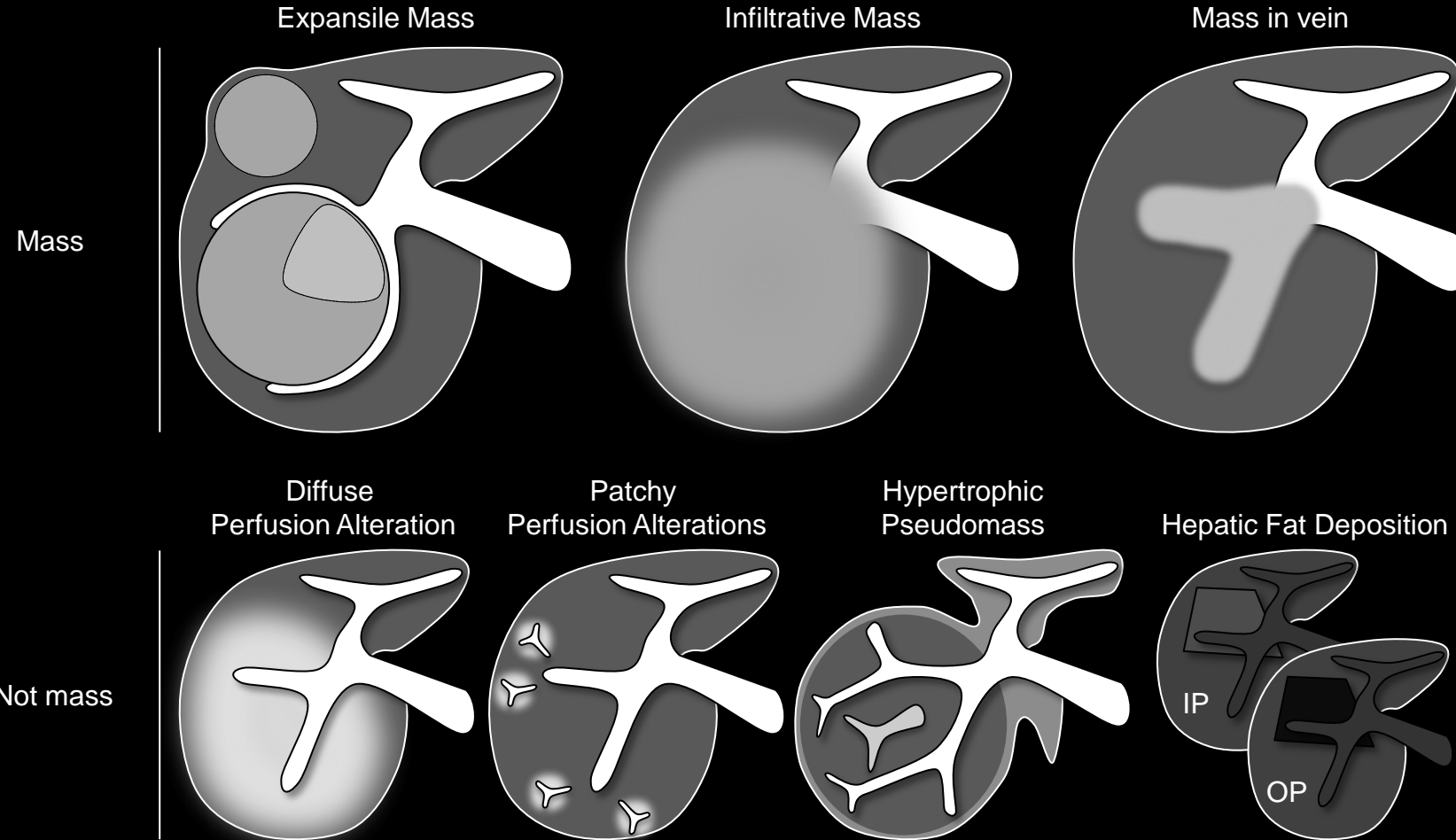
LR1	Continued routine surveillance
LR2	Continued routine surveillance
LR3	Variable follow-up
LR4	Close follow-up, additional imaging, biopsy, or treatment
LR5	Treatment without biopsy. Radiologic T-staging.
LR5V	Treatment without biopsy. Radiologic T-stage 4b.
LR5 Treated	Close follow up to assess treatment response. May require re-treatment if persistent/recurrent tumor.
OM	Close follow up, additional imaging, biopsy, or treatment.

## Management:

### OM:

- Variable, depending on clinical history and type of malignancy suspected.
- Appropriate management may include close follow up, additional imaging, biopsy, or treatment.
- Does not contribute to [radiologic T-staging](#) and does not provide HCC exception points for determining priority on liver transplantation list, unless tissue sampling with histology analysis establishes a diagnosis of HCC. See OPTN policy 3.6.4.4.





## Mass:

Three-dimensional space-occupying lesion that displaces or replaces underlying hepatic parenchyma.

### If unsure whether observation is mass:

- Characterize as mass if observation may represent [infiltrative HCC](#) or infiltrative [other malignancy \(OM\)](#).
- Otherwise characterize as not mass.

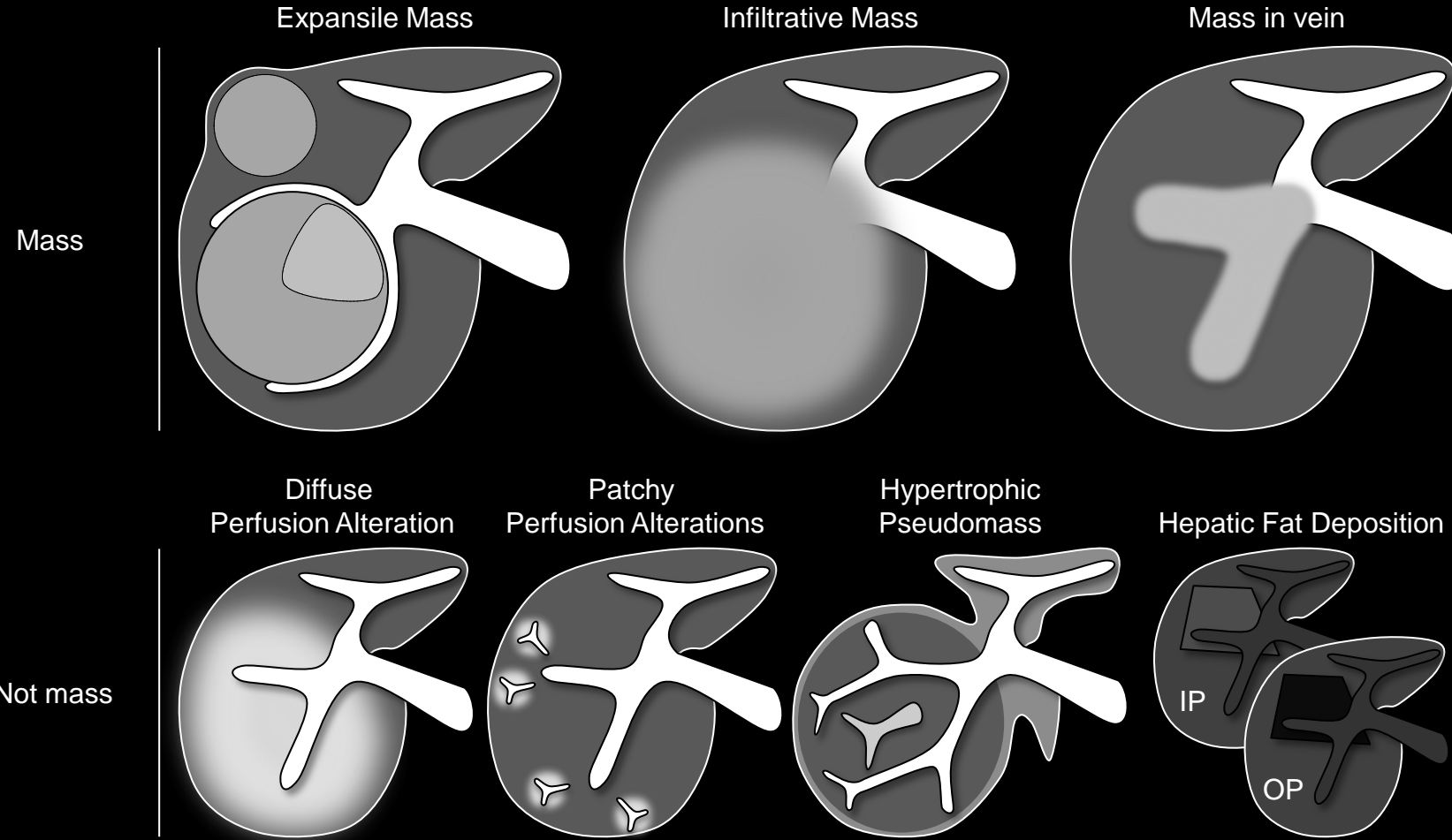
### Comments:

- Examples of mass:
  - Expansile mass
  - Infiltrative mass
  - Mass that invades vein (i.e., [tumor in vein](#)), even if parenchymal component of mass is not identified at imaging
- Masses may overlap in imaging appearance with observations that are not masses (e.g., rounded perfusion alterations, hypertrophic pseudomass, hepatic fat deposition/sparing).

### [More comments](#)

**Mass:** Schematic diagrams illustrate expansile mass, infiltrative mass, mass in vein and, for comparison, non-masses.

- Expansile mass – notice displacement of vessels and bulging of liver surface.
- Infiltrative mass – notice architectural distortion, obscuration of vessels, and heterogeneity.
- Mass in vein – notice enhancing mass within vein lumen. Parenchymal component of mass may or may not be visible at imaging.
- Non-mass – notice undistorted vessels traversing observations.



## Mass:

### Comments (continued):

- Imaging features that, if present, favor mass include:
  - Displacement of vessels
  - Bulging or retraction of liver surface
  - Architectural distortion
  - [Rounded](#) shape
  - [Capsule appearance](#)
- Imaging features that, if present, favor non-mass include:
  - [Undistorted vessels](#) traversing observation
  - Absence of mass effect
  - Preservation of hepatic architecture
  - Geographic shape
- Multiplanar images (source or reformatted) may help in the characterization of observations as masses or not masses by showing to better advantage some of the above features.

**Mass:** Schematic diagrams illustrate expansile mass, infiltrative mass, mass in vein and, for comparison, non-masses.

- Expansile mass – notice displacement of vessels and bulging of liver surface.
- Infiltrative mass – notice architectural distortion (disruption?), obscuration of vessels, and heterogeneity.
- Mass in vein – notice enhancing and expansile mass within vein lumen. Parenchymal component of mass may or may not be visible at imaging.
- Non-mass – notice undistorted vessels traversing observations.

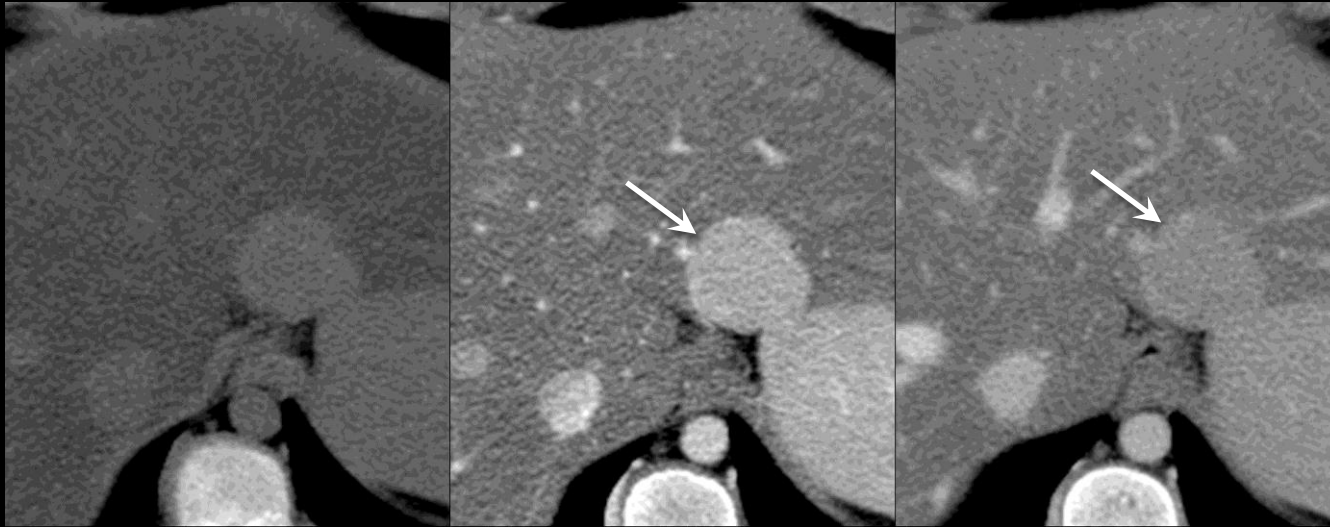

Pre

Arterial

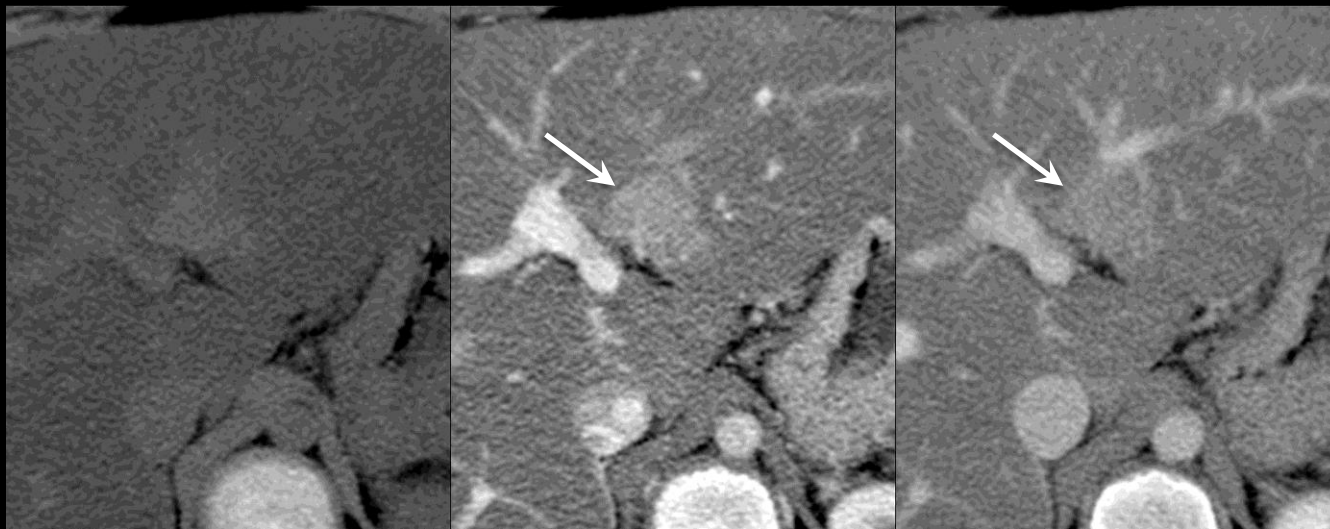
Portal Venous

Mass



First row –  
A hyper-enhancing 2.3cm mass replacing normal liver parenchyma and displacing blood vessels.

Not mass



Second row –  
A geographic perfusion alteration (~2cm) is shown. Note undistorted vessels in and adjacent to observation.

### Mass:

Three-dimensional space-occupying lesion that displaces or replaces underlying hepatic parenchyma.

### If unsure whether observation is mass:

- Characterize as mass if observation may represent [infiltrative HCC](#) or infiltrative [other malignancy \(OM\)](#).
- Otherwise characterize as not mass.

### Comments:

- Examples of mass:
  - Expansile mass
  - Infiltrative mass
  - Mass that invades vein (i.e., [tumor in vein](#)), even if parenchymal component of mass is not identified at imaging
- Masses may overlap in imaging appearance with observations that are not masses (e.g., rounded perfusion alterations, hypertrophic pseudomass, hepatic fat deposition/sparing).

### [More comments](#)

**Mass (CT):** Figure collage shows a mass and not a mass (in this case, a perfusion alteration due to anomalous non-portal venous supply to portion of segment 2/3) at CT. Background liver is fatty.



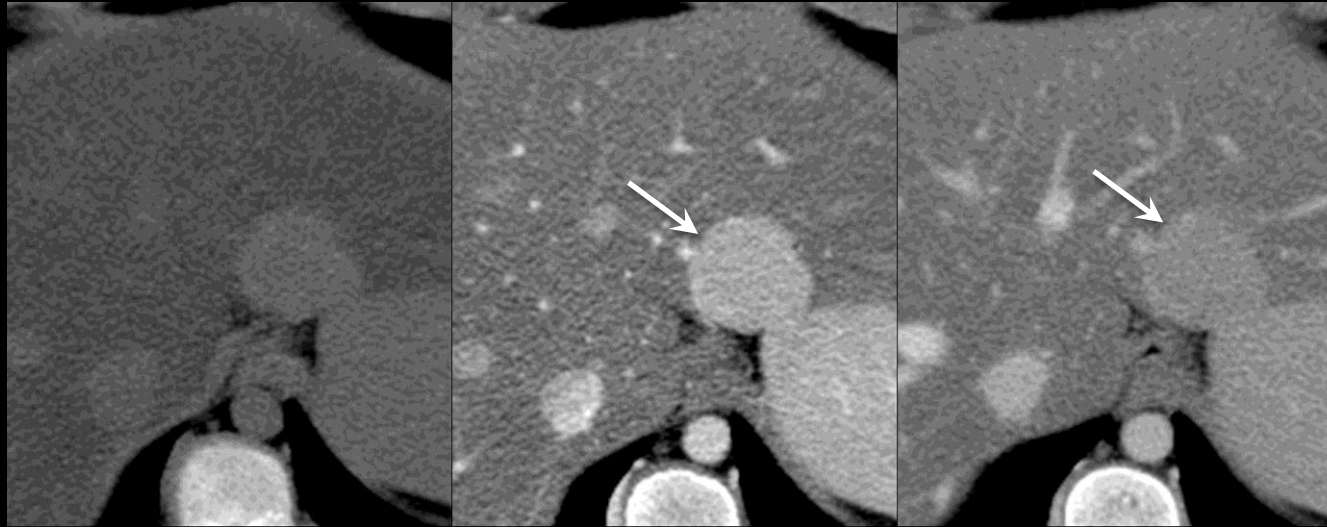

Pre

Arterial

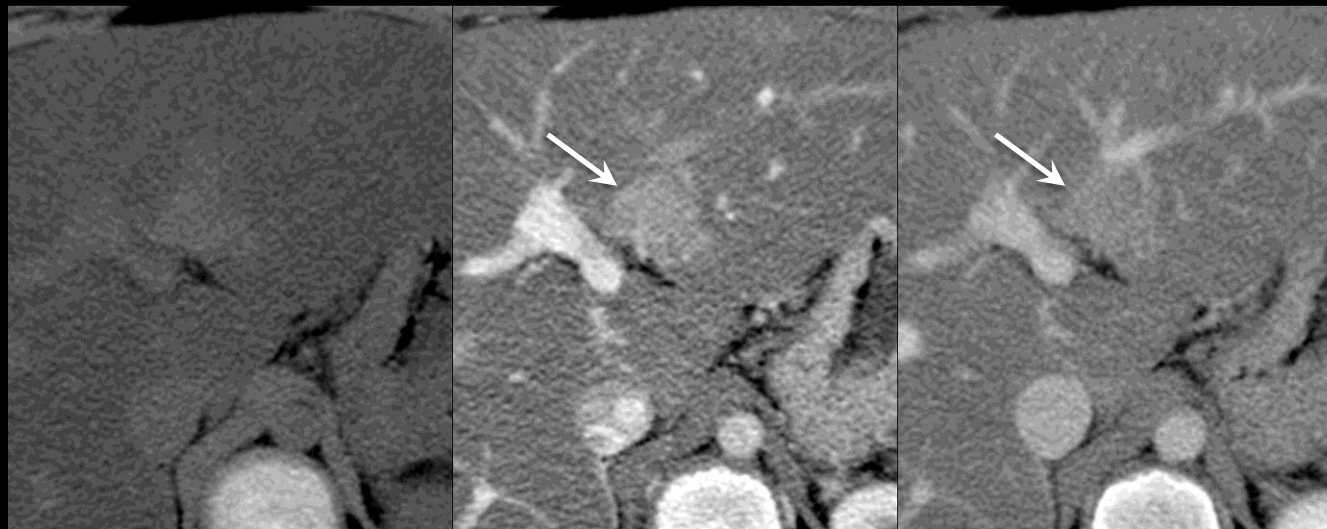Portal Venous

Mass



First row –  
A hyper-enhancing 2.3cm mass replacing normal liver parenchyma and displacing blood vessels.

Not mass



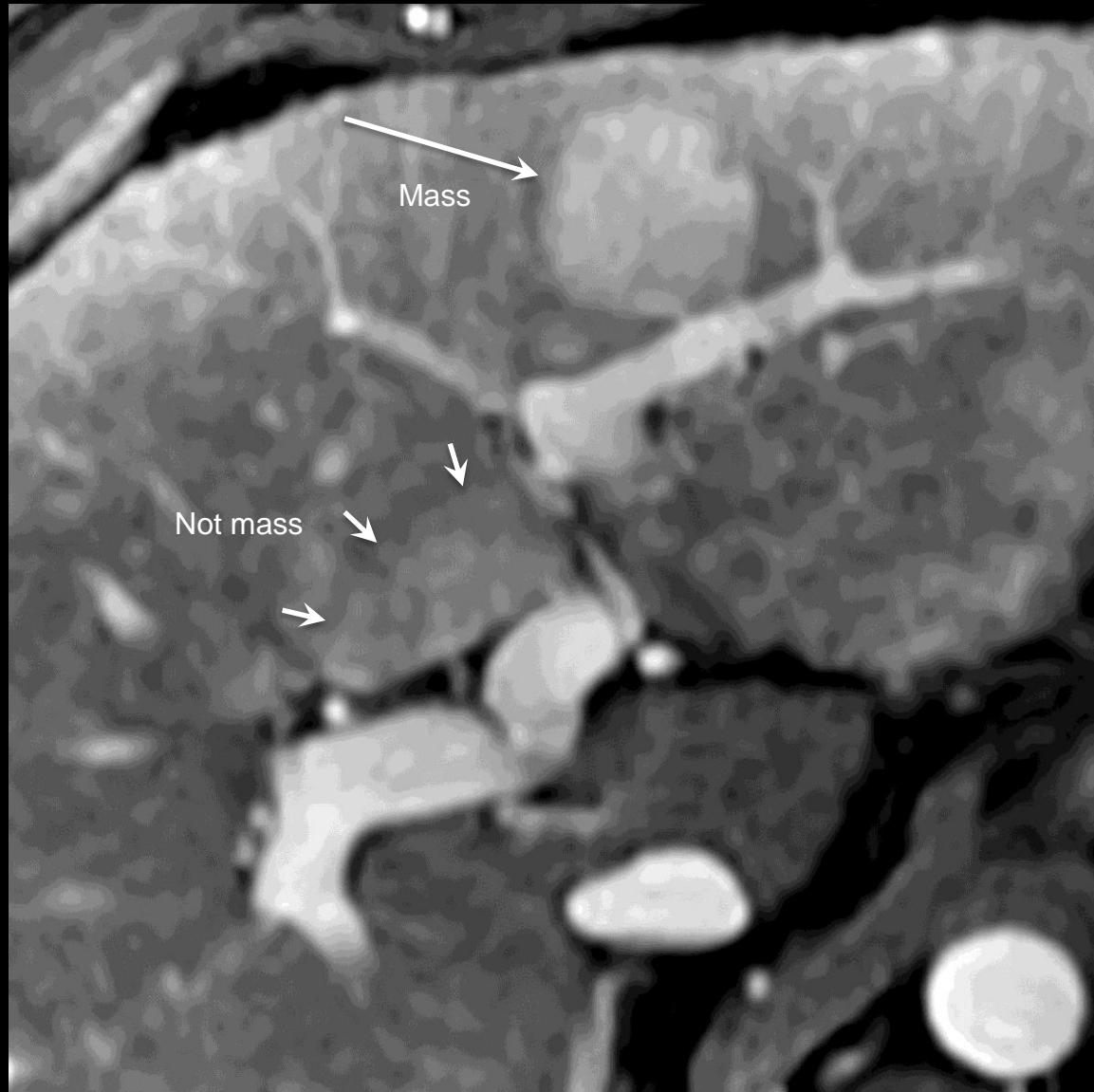Second row –  
A geographic perfusion alteration (~2cm) is shown. Note undistorted vessels in and adjacent to observation.

**Mass:**

**Comments (continued):**

- Imaging features that, if present, favor mass include:
  - Displacement of vessels
  - Bulging or retraction of liver surface
  - Architectural distortion
  - [Rounded](#) shape
  - [Capsule appearance](#)
- Imaging features that, if present, favor non-mass include:
  - [Undistorted vessels](#) traversing observation
  - Absence of mass effect
  - Preservation of hepatic architecture
  - Geographic shape
- Multiplanar images (source or reformatted) may help in the characterization of observations as masses or not masses by showing to better advantage some of the above features.

**Mass (CT):** Figure collage shows a mass and not a mass (in this case, a perfusion alteration due to anomalous non-portal venous supply to portion of segment 2/3) at CT. Background liver is fatty.

**Mass:**

Three-dimensional space-occupying lesion that displaces or replaces underlying hepatic parenchyma.

**If unsure whether observation is mass:**

- Characterize as mass if observation may represent [infiltrative HCC](#) or infiltrative [other malignancy \(OM\)](#).
- Otherwise characterize as not mass.

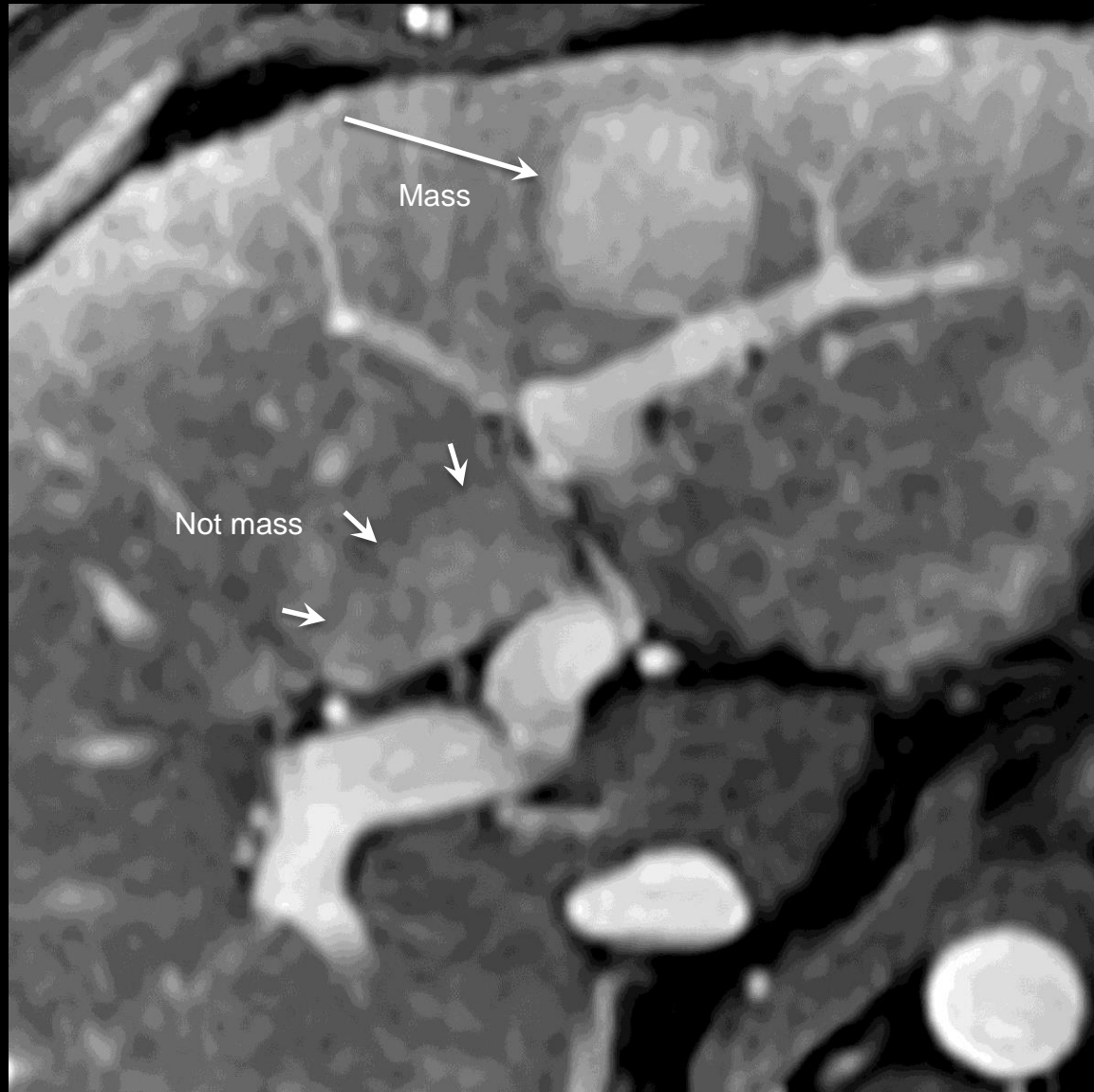
**Comments:**

- Examples of mass:
  - Expansile mass
  - Infiltrative mass
  - Mass that invades vein (i.e., [tumor in vein](#)), even if parenchymal component of mass is not identified at imaging
- Masses may overlap in imaging appearance with observations that are not masses (e.g., rounded perfusion alterations, hypertrophic pseudomass, hepatic fat deposition/sparing).

[More comments](#)

**Mass (MRI):** Figure collage shows a mass and not a mass (in this case, a perfusion alteration due to anomalous non-portal venous supply to para-hilar portion of segment 4) at MRI.



**Mass:****Comments (continued):**

- Imaging features that, if present, favor mass include:
  - Displacement of vessels
  - Bulging or retraction of liver surface
  - Architectural distortion
  - [Rounded](#) shape
  - [Capsule appearance](#)
- Imaging features that, if present, favor non-mass include:
  - [Undistorted vessels](#) traversing observation
  - Absence of mass effect
  - Preservation of hepatic architecture
  - Geographic shape
- Multiplanar images (source or reformatted) may help in the characterization of observations as masses or not masses by showing to better advantage some of the above features.

**Mass (MRI):** Figure collage shows a mass and not a mass (in this case, a perfusion alteration due to anomalous non-portal venous supply to para-hilar portion of segment 4) at MRI.



Mild-moderate T2 hyper-intensity,  
well-definedMild-moderate T2 hyper-intensity,  
ill defined

Marked T2 hyper-intensity



Mild T2 hypo-intensity

Mild-moderate  
T2 hyper-intensityNot  
mild-moderate  
T2 hyper-intensity**Mild-moderate T2 hyper-intensity:**

Having mildly or moderately higher signal intensity on T2w images than liver and less than that of bile ducts or other simple-fluid filled structures.

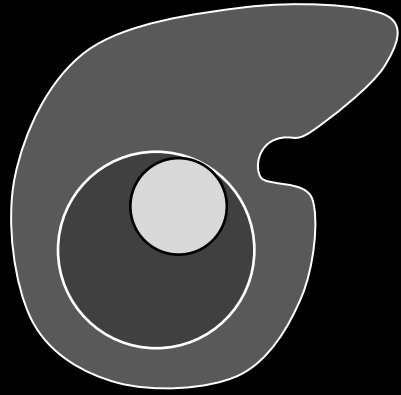
**Comments:**

- Applies to observations that, on T2w images, [unequivocally](#) are
  - Mildly or moderately hyper-intense relative to liver AND
  - Hypo-intense relative to bile ducts and other simple-fluid filled structures.
- Mild-moderate T2 hyper-intensity is an [ancillary feature](#) favoring HCC.
- Radiologists at their discretion may apply mild-moderate T2 hyper-intensity to upgrade category (up to LR4).

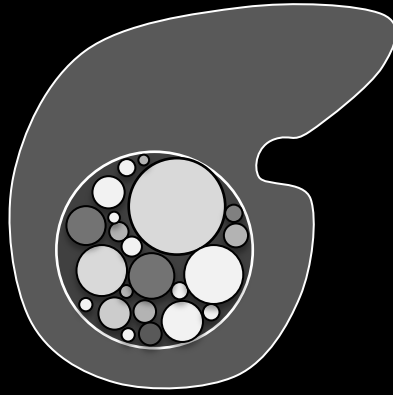
**Mild-moderate T2 hyper-intensity:** Schematic diagrams illustrate observations with (top row) and without (bottom row) mild-moderate T2 hyper-intensity. Mild-moderate T2 hyper-intensity refers to signal intensity on T2w images that unequivocally is greater than that of liver and less than that of bile ducts or other simple-fluid filled structures. It may apply to well-defined (top left) or ill-defined (top right) observations. Marked T2 hyper-intensity refers to signal intensity on T2w images similar to that of bile ducts or other simple fluid-filled structures. Mild T2 hypo-intensity refers to signal intensity on T2w images slightly lower than that of liver.



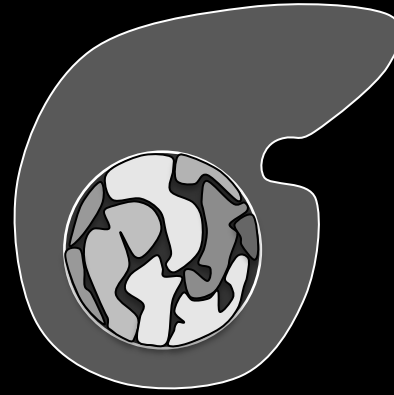
Nodule-in-nodule



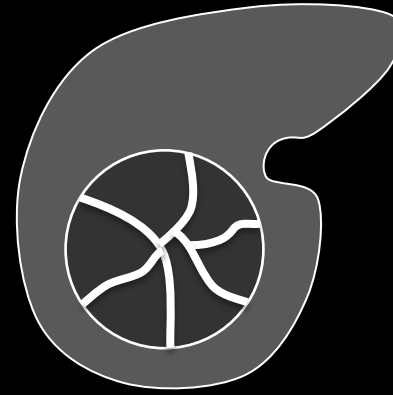
Multi-nodule-in-nodule



Multi-compartment-in-nodule



Septated solid mass



**Mosaic architecture:** Schematic diagrams illustrate four subtypes of mosaic architecture. Nodule-in-nodule (left) is characterized by presence of a single nodule within a larger mass. Multi-nodule-in-nodule (center) is characterized by presence of multiple nodules within a larger mass. Multi-compartment-in-nodule is characterized by presence of multiple discrete compartments within a larger mass. The nodules and compartments appear randomly distributed within the mass, and they have differing features (enhancement, attenuation, intensity, size). Septated mass is characterized by presence of irregular enhancing internal septa.

**Mosaic architecture:**

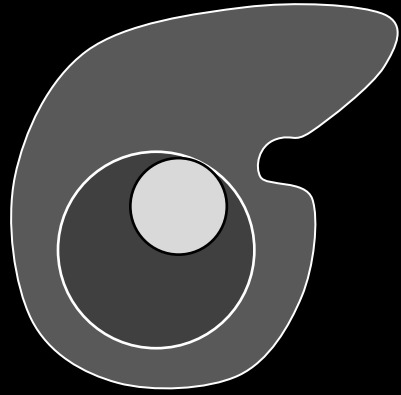
Observation that consists of nodules or compartments with differing features (enhancement, attenuation, intensity, size). This term can also be applied to lesions with internal enhancing septations. The nodules, compartments, or septations appear randomly distributed within the observation.

**Comments:**

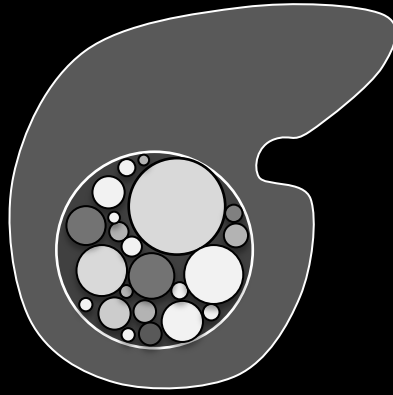
- Mosaic architecture may manifest as different subtypes:
  - [Nodule-in-nodule](#)
  - Multi-nodule-in-nodule
  - Multi-compartment-in-nodule
  - Septated solid mass
- In patients with cirrhosis or other risk factors for HCC, most masses with mosaic architecture are HCCs. These masses usually can be categorized LR5 based on [major features](#) such as [arterial-phase hyper-enhancement](#), [diameter  \$\geq\$  20mm](#), [“washout”](#), and [“capsule”](#).
- A mosaic mass that does not meet major feature criteria for LR5 (e.g., lacks arterial phase hyper-enhancement), cannot be categorized LR5. For such masses, mosaic architecture is an [ancillary feature](#) favoring HCC.
- Radiologists at their discretion may apply mosaic architecture to upgrade category (up to LR4) for such masses.



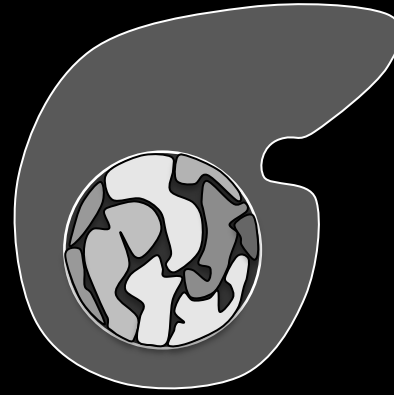
Nodule-in-nodule



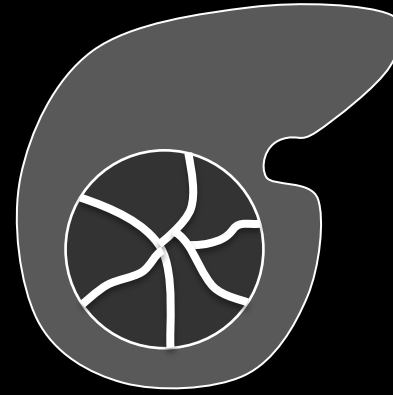
Multi-nodule-in-nodule



Multi-compartment-in-nodule



Septated solid mass

**Mosaic architecture:****Comments (continued):**

- [Diameter](#) measurement: For masses with mosaic architecture, include the entire mass in the measurement, not just the internal nodule(s) or compartment(s).

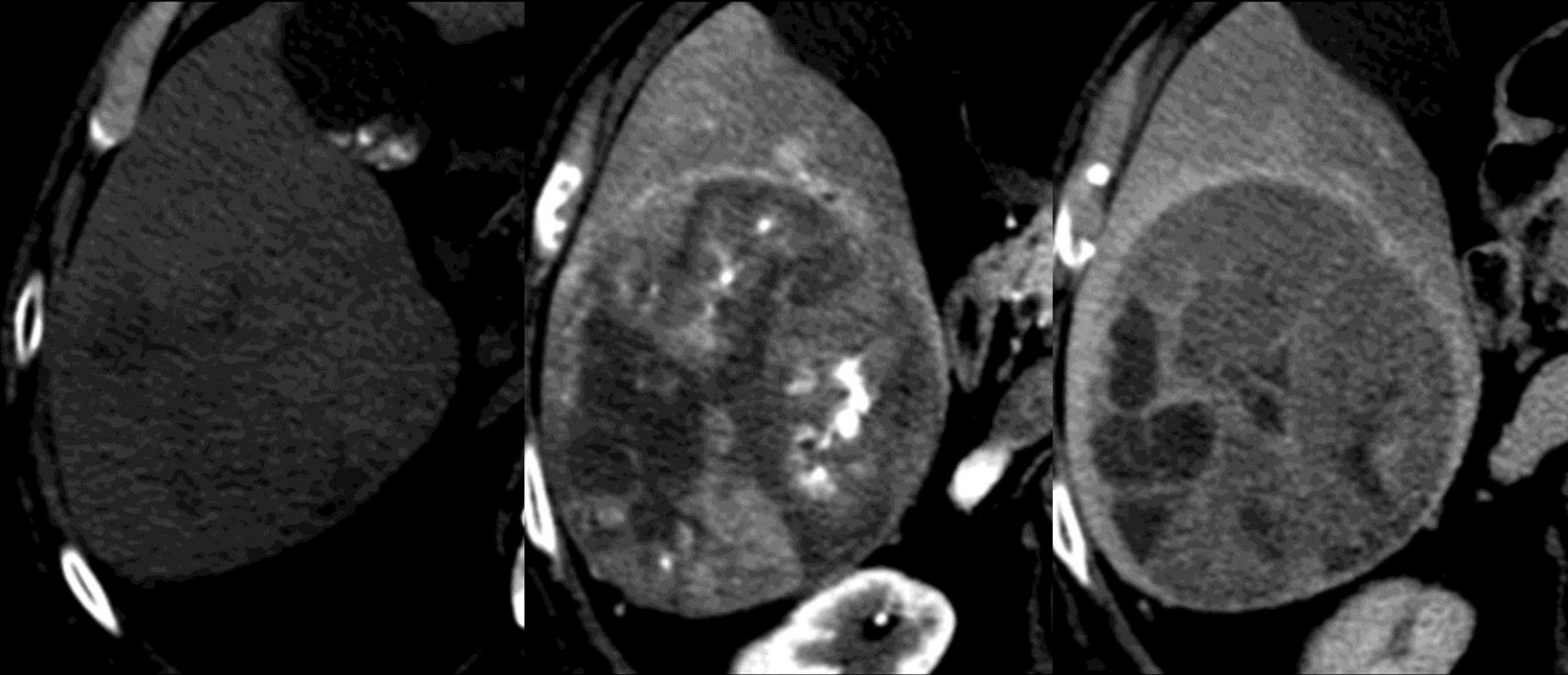
**Mosaic architecture:** Schematic diagrams illustrate four subtypes of mosaic architecture. Nodule-in-nodule (left) is characterized by presence of a single nodule within a larger mass. Multi-nodule-in-nodule (center) is characterized by presence of multiple nodules within a larger mass. Multi-compartment-in-nodule is characterized by presence of multiple discrete compartments within a larger mass. The nodules and compartments appear randomly distributed within the mass, and they have differing features (enhancement, attenuation, intensity, size). Septated mass is characterized by presence of irregular enhancing internal septa.



Pre

Arterial

Portal Venous



**Mosaic architecture (multiple compartments within mass):** CT shows a large mass slightly hypo-attenuating on pre contrast image, showing marked heterogeneous enhancement in the hepatic arterial and portal venous phases. Notice random distribution within mass of different compartments.

**Mosaic architecture:**

Observation that consists of nodules or compartments with differing features (enhancement, attenuation, intensity, size). This term can also be applied to lesions with internal enhancing septations. The nodules, compartments, or septations appear randomly distributed within the observation.

**Comments:**

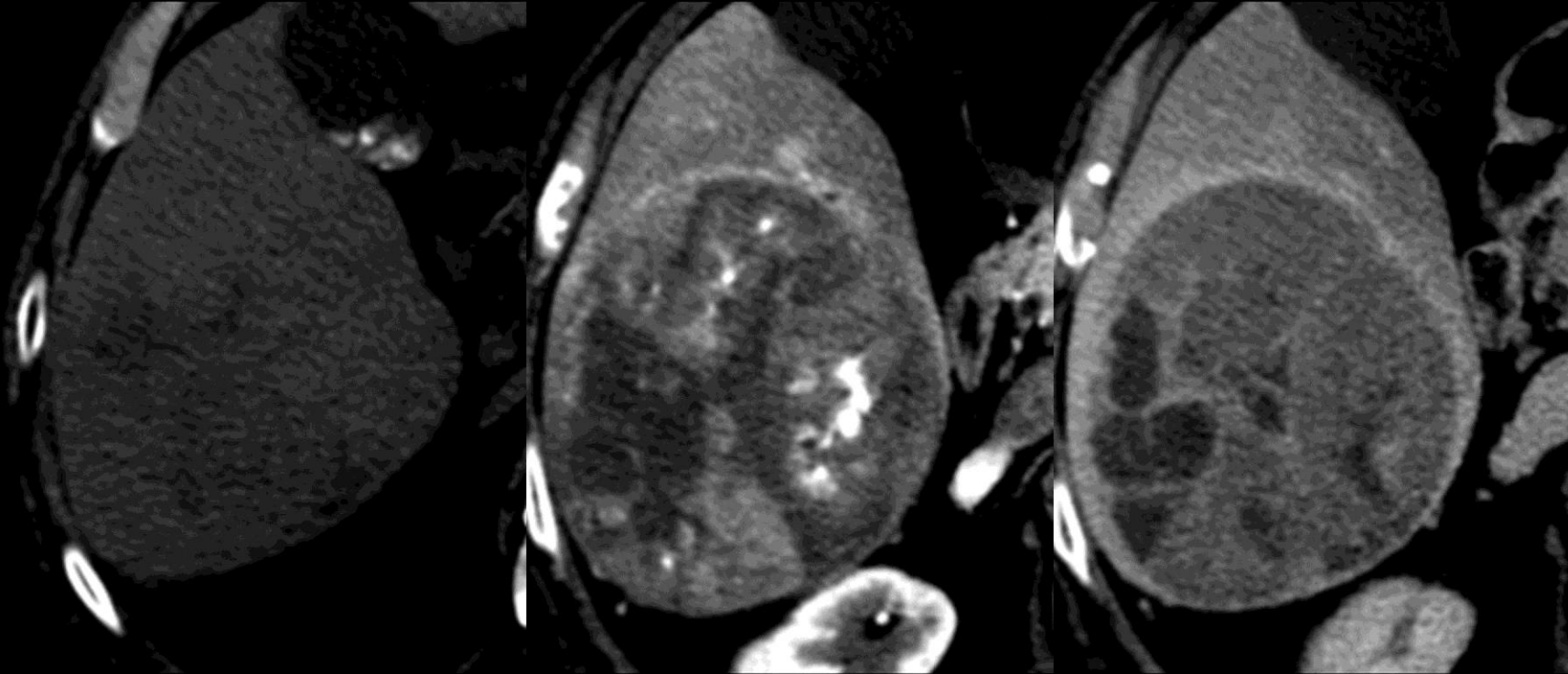
- Mosaic architecture may manifest as different subtypes:
  - [Nodule-in-nodule](#)
  - Multi-nodule-in-nodule
  - Multi-compartment-in-nodule
  - Septated solid mass
- In patients with cirrhosis or other risk factors for HCC, most masses with mosaic architecture are HCCs. These masses usually can be categorized LR5 based on [major features](#) such as [arterial-phase hyper-enhancement](#), [diameter  \$\geq\$  20mm](#), [“washout”](#), and [“capsule”](#).
- A mosaic mass that does not meet major feature criteria for LR5 (e.g., lacks arterial phase hyper-enhancement), cannot be categorized LR5. For such masses, mosaic architecture is an [ancillary feature](#) favoring HCC.
- Radiologists at their discretion may use mosaic architecture to upgrade category (up to LR4) for such masses.



Pre

Arterial

Portal Venous

**Mosaic architecture:****Comments (continued):**


- Diameter measurement: For masses with mosaic architecture, include the entire mass in the measurement, not just the internal nodule(s) or compartment(s).

**Mosaic architecture (multiple compartments within mass):** CT shows a large mass slightly hypo-attenuating on pre contrast image, showing marked heterogeneous enhancement in the hepatic arterial and portal venous phases. Notice random distribution within mass of different compartments.





Nodule-in-nodule architecture



**Nodule-in-nodule architecture:** Schematic diagram illustrates nodule-in-nodule architecture, which is characterized by presence of a single nodule within a larger mass. The nodule and the larger mass typically have differing features (enhancement, attenuation, intensity). Nodule-in-nodule is a sub-type of [mosaic architecture](#).

**Nodule-in-nodule architecture:**

Presence of a nodule within a larger nodule or mass. The internal nodule differs in enhancement or other feature from the larger nodule/mass.

**Comments:**

- “Nodule-in-nodule” architecture is a subtype of [mosaic architecture](#); hence, similar comments apply.
- In patients with cirrhosis or other risk factors for HCC, most masses with nodule-in-nodule architecture are HCCs. These masses usually can be categorized LR5 based on [major features](#) such as [arterial-phase hyper-enhancement](#), [diameter  \$\geq 20\text{mm}\$](#) , [“washout”](#), and [“capsule”](#).
- A mass with nodule-in-nodule architecture that does not meet major feature criteria for LR5 (e.g., lacks arterial phase hyper-enhancement), cannot be categorized LR5. For such masses, nodule-in-nodule architecture is an [ancillary feature](#) favoring HCC.
- Radiologists at their discretion may apply nodule-in-nodule architecture to upgrade category (up to LR4) for such masses.
- [Diameter](#) measurement: For masses with nodule-in-nodule architecture, include the entire mass in the measurement, not just the internal nodule(s).

**Atlas:** CT, MR





## Nodule-like arterial phase hyper-enhancement (NAPH):

< 20mm [hyper-enhancement](#) with nodular configuration and visible only in the [arterial phase](#).

NAPHs are thought to usually represent either perfusion alterations or small non-malignant masses (e.g., FNH-like lesion, hemangioma, dysplastic nodule), but occasionally small HCC.

### LI-RADS Categorization:

- NAPHs should be categorized [LR2](#), [LR3](#), or [LR4](#), depending on their number and stability, clinical history (e.g., history of prior locoregional ablation), presence of LR4 or LR5 observations elsewhere in liver, and radiologist's certainty (see below).

**If unsure whether a < 20mm hyper-enhancing observation is a [perfusion alteration](#) or a [mass](#):**

- Categorize as LR3.

**If imaging features favor perfusion alteration over mass:**

- Categorize as LR2.

**If imaging features favor mass over perfusion alteration:**

- Categorize as LR3 or LR4.

**Atlas:** CT, MR

**Non-enhancement:**

Lack of enhancement relative to [pre-contrast imaging](#).

**Comments:**

- Applies to imaging observations that, after contrast injection, do not enhance relative to pre-contrast imaging.

**Atlas:** CT, MR



## Clinical and Imaging Features of HCC and Non-HCC Malignancies in the Liver

Malignancy	Clinical Features	Imaging Features
<b>HCC</b>	<ul style="list-style-type: none"> <li>Major risk factors: cirrhosis or chronic hepatitis B viral infection; history of HCC</li> <li>Minor risk factors: old age, male gender, diabetes, obesity, alcohol abuse, co-infection, iron overload, smoking</li> <li>Elevated tumor markers: AFP, AFP-L3, DCP/PIVKA</li> </ul>	<ul style="list-style-type: none"> <li>Diffuse arterial phase hyper-enhancement</li> <li>Arterial phase hyper-enhancement with portal venous or delayed phase washout appearance</li> <li>Intra-lesional fat</li> <li>Blood products</li> <li>Capsule appearance</li> <li>Mosaic architecture</li> <li>Tumor in vein</li> </ul>
<b>CCC</b>	<ul style="list-style-type: none"> <li>Risk factors for CCC overlap with those for HCC and include cirrhosis and chronic viral hepatitis, as well as chronic inflammatory conditions of the biliary system such as PSC</li> <li>Elevated tumor markers: CA19-9, CEA</li> </ul>	<ul style="list-style-type: none"> <li>Arterial phase target enhancement</li> <li>Portal venous and delayed phase central enhancement</li> <li>± Markedly restricted diffusion</li> <li>Liver surface retraction</li> <li>Biliary obstruction disproportionate to that expected based on size of mass</li> </ul>
<b>Lymphoma</b>	<ul style="list-style-type: none"> <li>History of extra-hepatic lymphoma with secondary involvement of liver</li> <li>AIDS, immune suppression, HCV infection</li> </ul>	<ul style="list-style-type: none"> <li><i>Pending</i></li> </ul>
<b>PTLD</b>	<ul style="list-style-type: none"> <li>History of prior solid organ transplantation</li> <li>Increased risk:                             <ul style="list-style-type: none"> <li>Epstein-Barr virus (EBV) negative recipient and EBV positive donor</li> <li>Prolonged, high-dose immune suppression</li> </ul> </li> <li>Usually occurs 2-12 months post transplant</li> <li>Extra-hepatic involvement is common</li> <li>Liver-only involvement may occur</li> </ul>	<ul style="list-style-type: none"> <li><i>Pending</i></li> </ul>
<b>Metastases</b>	<ul style="list-style-type: none"> <li>Extremely rare in cirrhosis</li> <li>History of primary extra-hepatic malignancy</li> <li>± Elevated tumor biomarkers depending on primary</li> </ul>	<ul style="list-style-type: none"> <li>Arterial phase ring or target enhancement</li> <li>± Portal venous and delayed phase central enhancement</li> <li>± Markedly restricted diffusion</li> <li>± Multiplicity</li> <li>± Central necrosis or ischemia</li> </ul>

### Non-HCC Malignancy:

A malignancy in the liver that is not HCC.

### LI-RADS Categorization:

- Observations thought to represent a non-HCC malignancy should be categorized [OM](#).

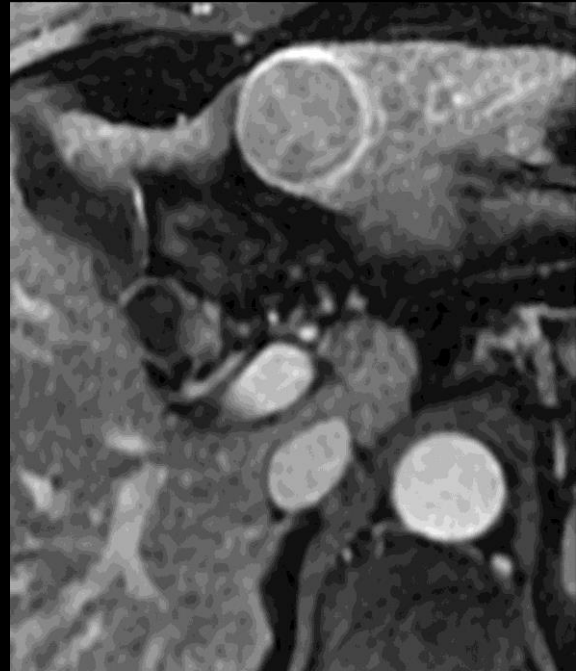### Comments:

- HCC is the most common malignancy in patients with cirrhosis or other risk factors for HCC. Non-HCC malignancies may occur, however.
- Examples of non-HCC malignancy include:
  - [Cholangiocellular carcinoma \(CCC\)](#)
  - Metastasis
  - Lymphoma,
  - Post-transplant lymphoproliferative disorder (PTLD)
- Differentiation between HCC and non-HCC malignancies is important as the management and prognosis differ.
- See table on left for clinical and imaging features that may help in the differentiation.

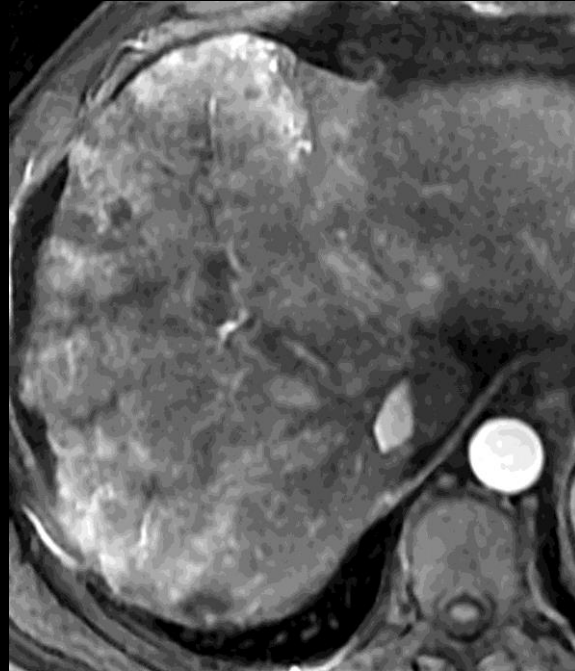**Atlas:** CT, MR



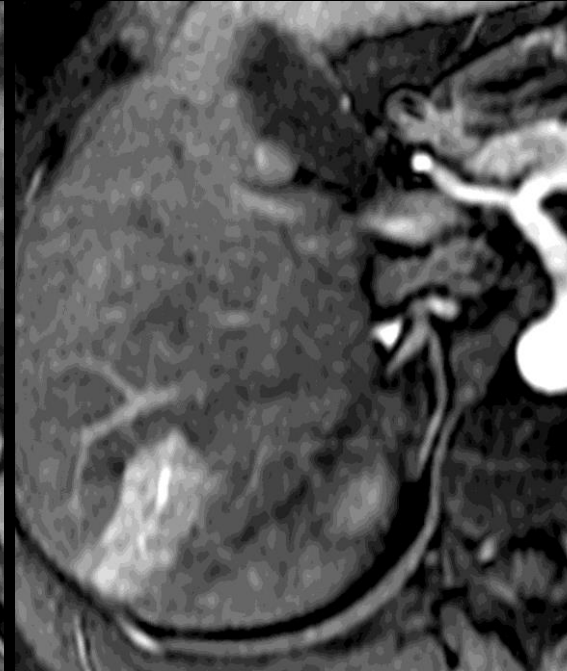## Expansile Mass



## Infiltrative Mass



## Not Mass



### Observation:

Area with imaging features that differ from those of adjacent liver parenchyma.

### Comments:

- The term observation is preferred over the term lesion, since some observations (e.g. [perfusion alterations](#), artifacts) may represent pseudo-lesions rather than true lesions.
- Observations are categorized [LR1](#), [LR2](#), [LR3](#), [LR4](#), [LR5](#), [LR5V](#), [LR5 Treated](#), or [OM](#).
- Click on the following links for for additional details on LI-RADS:
  - [Diagnostic algorithm](#)
  - [Categories](#)
  - [Reporting](#)
  - [Management](#)

**Observation (MRI):** An observation may be an expansile mass, an infiltrative mass, or not a mass (e.g., perfusion alteration, as shown above).

**Atlas:** CT, [MR](#)

[Acknowledgments](#)

Feedback? Email [nrd@acr.org](mailto:nrd@acr.org)



## Comparison of OPTN Class 5 and LI-RADS Category 5

### OPTN Class 5

### LI-RADS Category 5

<b>1-2cm HCC</b>	<p><b>OPTN Class 5A: <math>\geq 1\text{cm}</math> and <math>&lt; 2\text{cm}</math> nodule</b></p> <ul style="list-style-type: none"> <li>Increased contrast enhancement on late hepatic arterial phase AND both:             <ul style="list-style-type: none"> <li>Washout during later contrast phases</li> <li>Peripheral rim enhancement (capsule/pseudocapsule)</li> </ul> </li> </ul> <p><b>OPTN Class 5A-g: <math>\geq 1\text{cm}</math> and <math>&lt; 2\text{cm}</math> nodule</b></p> <ul style="list-style-type: none"> <li>Increased contrast enhancement on late hepatic arterial phase AND the following:             <ul style="list-style-type: none"> <li>Growth*</li> </ul> </li> </ul>	<p><b>LR5A: 10-19mm mass</b></p> <ul style="list-style-type: none"> <li>Arterial phase hyper-enhancement AND <math>\geq 2</math> of following:             <ul style="list-style-type: none"> <li>Washout appearance</li> <li>Capsule appearance</li> <li>Threshold growth**</li> </ul> </li> </ul>
<b><math>\geq 2\text{cm}</math> HCC</b>	<p><b>OPTN Class 5B: <math>\geq 2\text{cm}</math> and <math>\leq 5\text{cm}</math> nodule</b></p> <ul style="list-style-type: none"> <li>Increased contrast enhancement on late hepatic arterial phase AND <math>\geq 1</math> of following:             <ul style="list-style-type: none"> <li>Washout during later contrast phases</li> <li>Peripheral rim enhancement (capsule/pseudocapsule)</li> <li>Growth*</li> </ul> </li> </ul> <p><b>OPTN Class 5X: <math>&gt; 5\text{cm}</math> nodule</b></p> <ul style="list-style-type: none"> <li>Increased contrast enhancement on late hepatic arterial phase AND <math>\geq 1</math> of following:             <ul style="list-style-type: none"> <li>Washout during later contrast phases.</li> <li>Peripheral rim enhancement (capsule/pseudocapsule)</li> </ul> </li> </ul>	<p><b>LR5B: <math>\geq 20\text{mm}</math> mass</b></p> <ul style="list-style-type: none"> <li>Arterial phase hyper-enhancement AND <math>\geq 1</math> of following:             <ul style="list-style-type: none"> <li>Washout appearance</li> <li>Capsule appearance</li> <li>Threshold growth**</li> </ul> </li> </ul>
<b>HCC with tumor in vein</b>	<p>Imaging criteria not provided, as patients with tumor in vein are not eligible for liver transplantation</p>	<p><b>LR5V: HCC with tumor in vein</b></p> <ul style="list-style-type: none"> <li>Definite enhancing soft tissue in vein</li> </ul>

### OPTN Class 5:

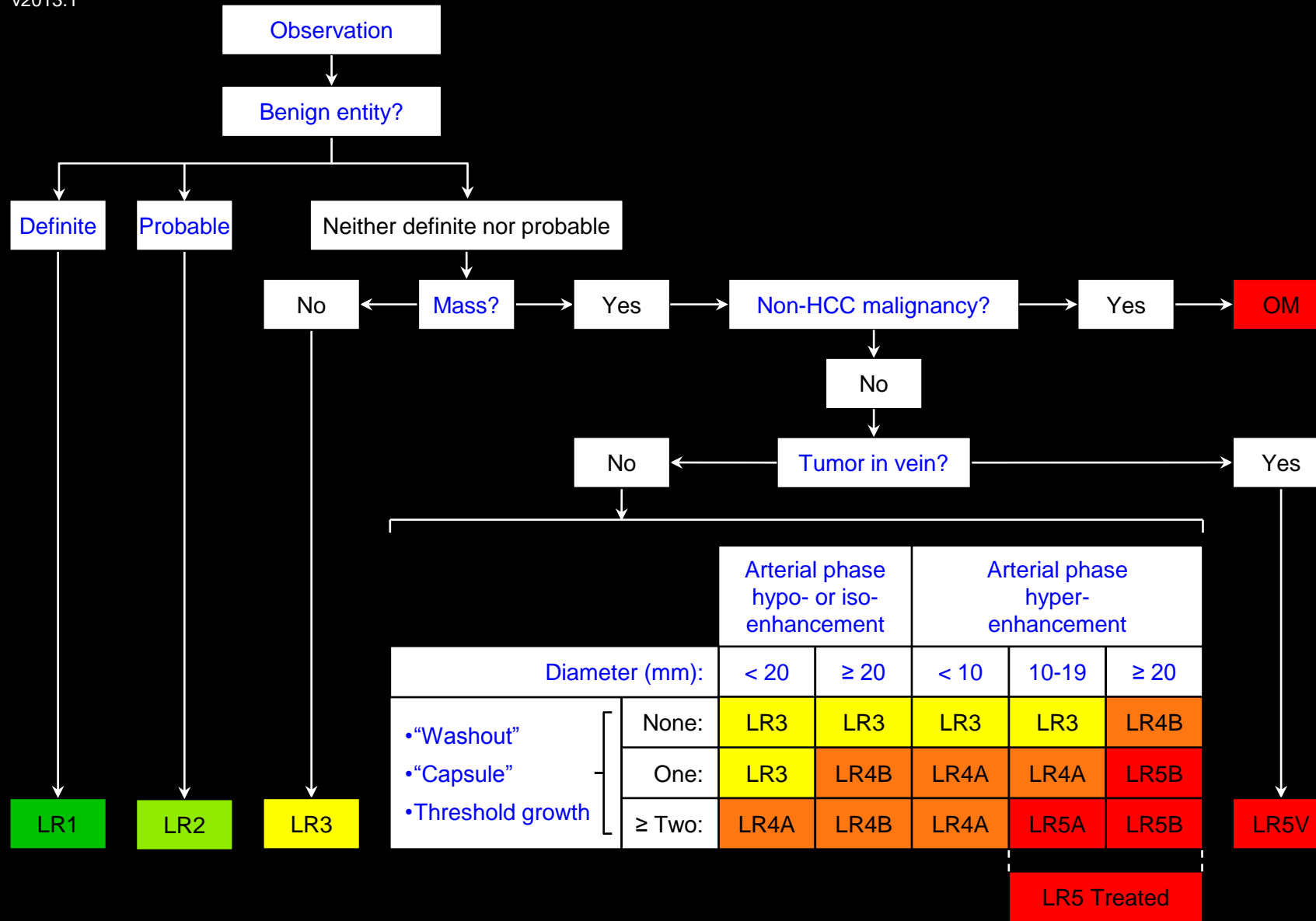
An observation that “meets radiologic criteria for HCC”, according to the Organ Procurement and Transplantation Network (OPTN) system. This system is used in the United States to help determine priority for liver transplantation.

#### Comments:

- LR5 and OPTN Class 5 are essentially equivalent. Both convey near-100% certainty for HCC and use similar imaging features. Terminology differs, mainly because LI-RADS applies to many clinical settings, not just consideration for liver transplantation.
- As shown in Table, differences include:
  - OPTN has 5A-g and 5X classes; these are integrated into the LI-RADS 5A and 5B categories, respectively.
  - OPTN 5A-g nodules with arterial-phase hyper-enhancement and threshold growth but with neither “washout” nor “capsule” are categorized LR4A.
  - OPTN Class 5X nodules are categorized LR5B. As long as the size of LR5B observations is reported, the conversion from LR5B to OPTN Class 5X is straightforward.
  - LI-RADS provides a 5V category for HCC with tumor in vein; OPTN does not provide criteria for tumor in vein.
  - OPTN definition of growth and LI-RADS definition of threshold growth differ. See table footnote.

\*OPTN requires growth by 50% or more in diameter during a  $\leq 6\text{-month}$  time interval.

\*\* LI-RADS defines threshold growth as 50% or more diameter increase during a  $\leq 6\text{-month}$  time interval or as 100% or more diameter increase during a  $> 6\text{-month}$  time interval.



Apply Ancillary Features and then Tie-Breaking Rules to Adjust Category

OM: Other Malignancy

**Concept:**

High probability that observation is a malignancy other than HCC.

**Definition:**

Observation with features suggestive of [non-HCC malignancy](#).

**Reporting:**

Must be reported.

**Management:**

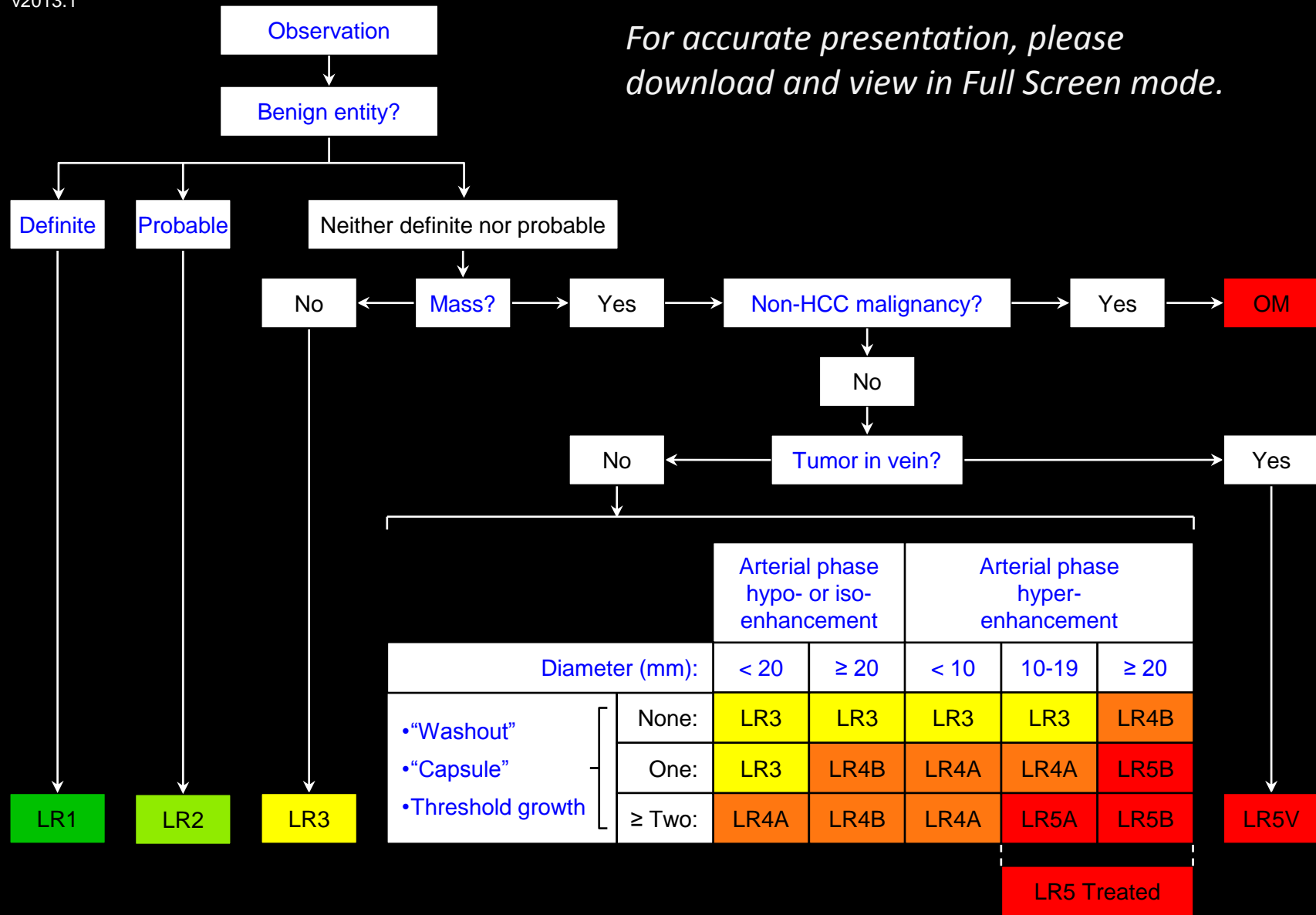
- Variable, depending on clinical history and type of malignancy suspected.
- Appropriate management may include close follow up, additional imaging, biopsy, or treatment.
- Does not contribute to [radiologic T-staging](#) and does not provide HCC exception points for determining priority on liver transplantation list, unless tissue sampling with histology analysis establishes a diagnosis of HCC. See OPTN policy 3.6.4.4.

Atlas: CT, MR





*For accurate presentation, please download and view in Full Screen mode.*



Apply **Ancillary Features** and then **Tie-Breaking Rules** to **Adjust Category**

## Overview:

LI-RADS [categorizes observations](#) reflecting likelihood of benignity or HCC in at-risk patients, as shown in algorithm.

Definitely or probably benign observations are categorized [LR1](#) and [LR2](#), respectively.

Remaining observations that are not [masses](#) then are categorized [LR3](#).

Masses with features suggestive of [non-HCC malignancy](#) are categorized [Other Malignancy \(OM\)](#).

Remaining masses with definite [tumor in vein](#) are categorized [LR5V](#).

Masses without definite tumor in vein are categorized [LR3](#), [LR4](#), or [LR5](#) as shown in [Table](#) based on [major features](#).

LR4 observations are [designated A](#) ([diameter < 20mm](#)) or B ([diameter ≥ 20mm](#)).

LR5 observations are [designated A](#) ([diameter 10-19mm](#)) or B ([diameter ≥ 20mm](#)).

Smaller observations must satisfy stricter criteria to be assigned an equivalent LR category.

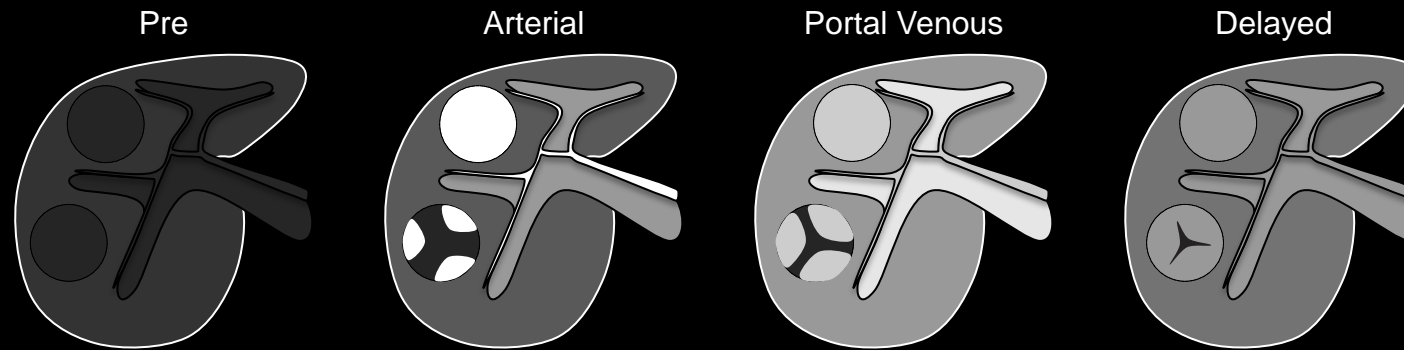
The final category may be [adjusted](#) using [ancillary features](#) and then [tie-breaking rules](#).

LR5A or 5B observations or biopsy-proven HCC lesions that have undergone loco-regional [treatment](#) are categorized [LR5 Treated](#).

Click on the following links for details on LI-RADS: [Reporting](#), [Management](#), [Technical Requirements](#).



Parallels  
blood  
pool  
enhancement



## Parallels blood pool enhancement

Temporal enhancement pattern in which enhancement in all phases approximates that of the blood pool.

### Comments:

- Applies to observations that enhance in all phases to a similar degree as the blood pool.
- This temporal enhancement pattern is a characteristic feature of hemangioma. Most masses with this pattern are hemangiomas and usually can be interpreted as definite or probable hemangiomas. Some masses with this pattern cannot be confidently diagnosed as definite or probable hemangiomas due to small size or presence of features not characteristic of hemangiomas. For such masses, this enhancement pattern is an [ancillary feature](#) favoring benignity.
- Radiologists at their discretion may apply parallels blood pool enhancement to downgrade category.

**Parallels blood pool enhancement:** Schematic diagram illustrates observations that in whole or in part enhance in all phases to a similar degree as the blood pool.

**Atlas:** CT, MR



## **Patchy:**

Having uneven or non-uniform distribution.

**Atlas:** CT, MR



### Perfusion alteration:

Change from the usual blood supply.

### LI-RADS Categorization:

- Observations thought to [definitely](#) represent perfusion alteration should be categorized LR1.
- Observations thought to [probably](#) represent perfusion alteration should be categorized LR2.
- Observations that are indeterminate for perfusion alteration versus HCC should be categorized LR3 or LR4.

### [Mechanisms](#)

### [Imaging Manifestations](#)

### [Pitfalls, Challenges, Differential Diagnosis](#)

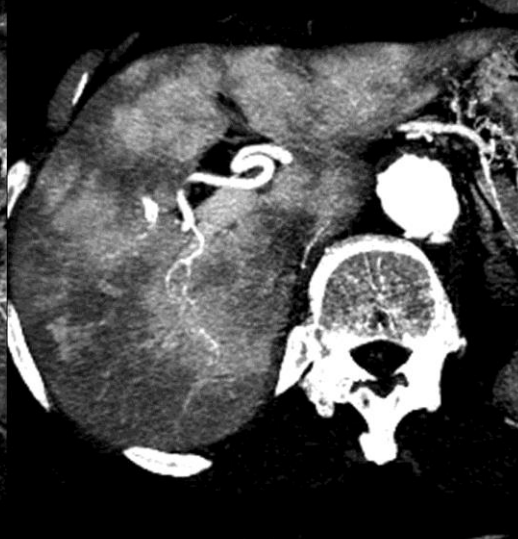
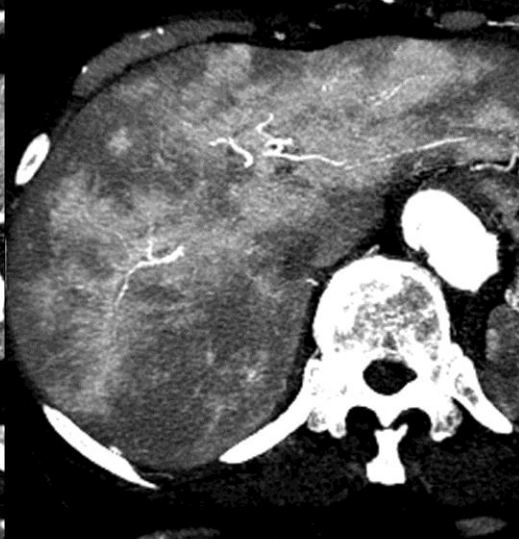
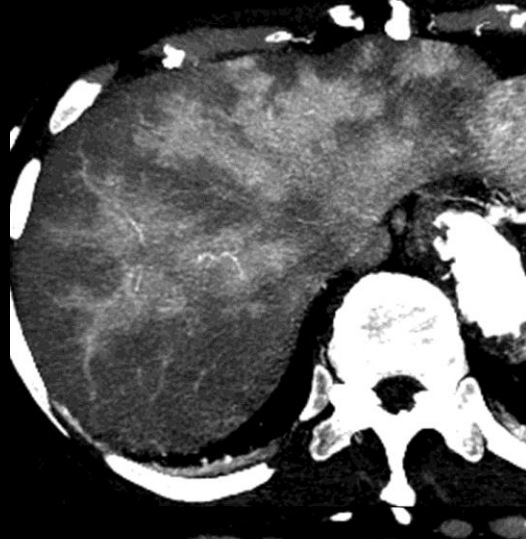
### [Other Comments](#)

Slice 1

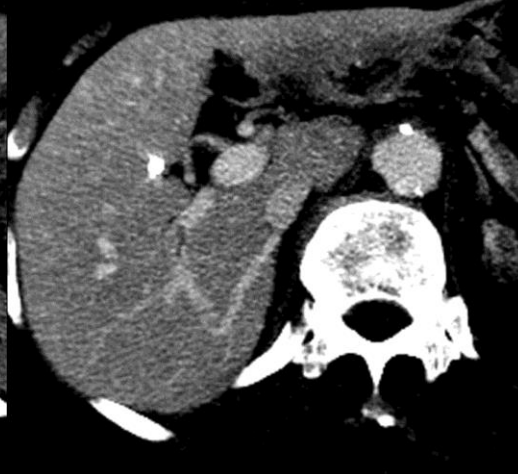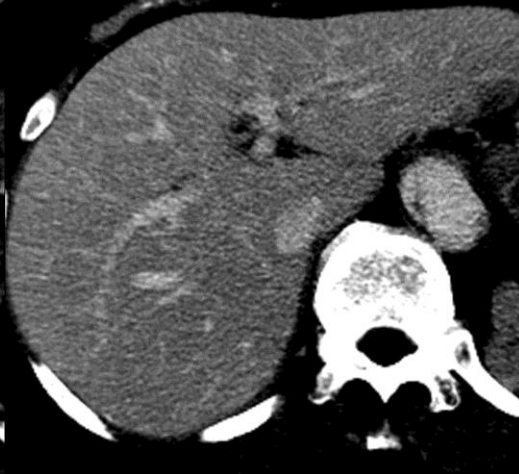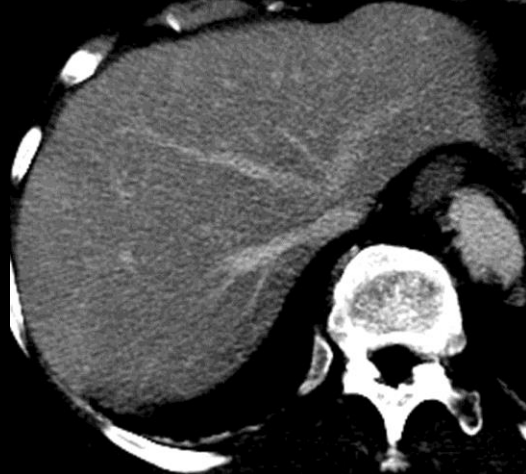Slice 2

Slice 3

Arterial phase



Portal venous phase



**Perfusion alteration (CT):** Figure collage shows a diffuse transient hepatic attenuation difference (THAD) in a per-vascular distribution on three representative, non-consecutive images. The arterial hyper-enhancement fades to iso-attenuation on portal venous phase. Notice undistorted vessels and absence of mass effect.





## Perfusion alteration:

### Mechanisms:

Perfusion alterations may be caused by several mechanisms:

- Regional arterial hyperemia induced by hyper-vascular tumor.
- Arterio-portal shunting due to cirrhosis, benign or malignant tumor, or arterio-portal fistula. The shunting causes increase in arterial flow to the territory supplied by the portal vein/venule.
  - Shunting due to a macroscopic fistula usually causes a wedge-shaped perfusion alteration.
  - Many arterioportal shunts in cirrhosis are due to tiny arterio-portal communications in the microcirculation. These microcirculatory shunts may cause small perfusion alterations, often nodule-like in configuration.
- Portal hypo-perfusion due to portal vein obstruction, portal vein invasion, or regional elevation in sinusoidal pressure. Portal hypo-perfusion causes compensatory increase in arterial flow (hepatic arterial buffer response).
- Anomalous (non-portal) venous inflow. Compared to portal veins, these anomalous veins have a shorter circulatory path from aorta to liver and are fully enhanced in the hepatic arterial phase.

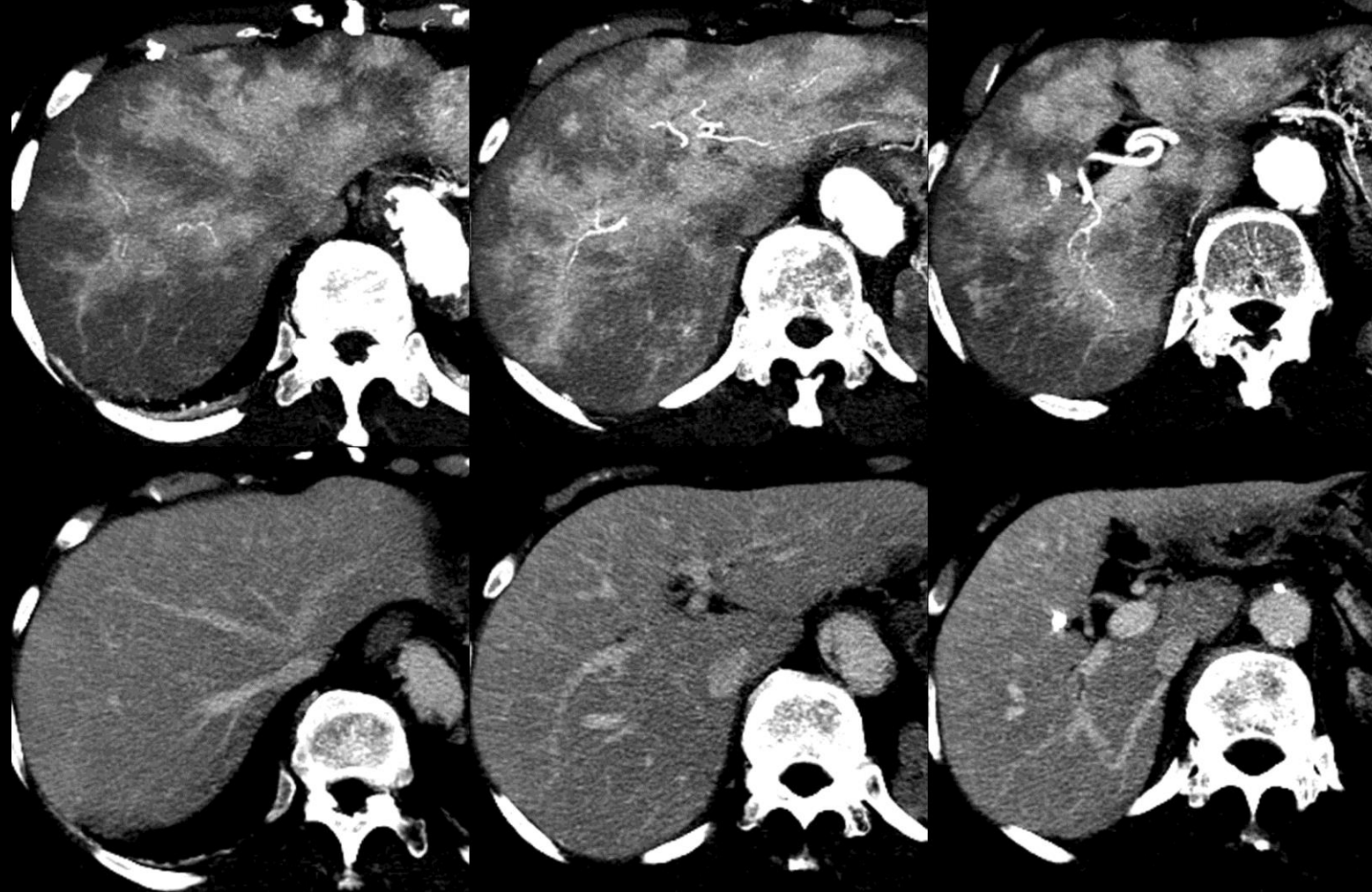
Slice 1

Slice 2

Slice 3

Arterial phase

Portal venous phase



**Perfusion alteration (CT):** Figure collage shows a diffuse transient hepatic attenuation difference (THAD) in a per-vascular distribution on three representative, non-consecutive images. The arterial hyper-enhancement fades to iso-attenuation on portal venous phase. Notice undistorted vessels and absence of mass effect.



**Perfusion alteration:****Imaging manifestations:**

- Perfusion alterations manifest at CT and MRI as transient hepatic enhancement differences (THEDs), also known as transient hepatic attenuation differences or transient hepatic intensity differences.
- Perfusion alterations/THEDs typically show, relative to liver:
  - [Hyper-enhancement](#) in the [arterial phase](#)
  - [Iso-enhancement](#) in the [portal venous phase](#) and [delayed phase](#)
  - [Iso-attenuation](#) at unenhanced CT and [iso-intensity](#) at T2w, DW, and unenhanced T1w MRI
- Perfusion alterations/THEDs may have variable morphologies ([wedge-shaped](#), [rounded](#)) and distributions ([diffuse](#), lobar, segmental, peritumoral, [subcapsular](#), [patchy](#)).
- Perfusion alterations/THEDs are not masses. Hence they exert no mass effect and they preserve the underlying hepatic parenchyma. Undistorted vessels traverse them.

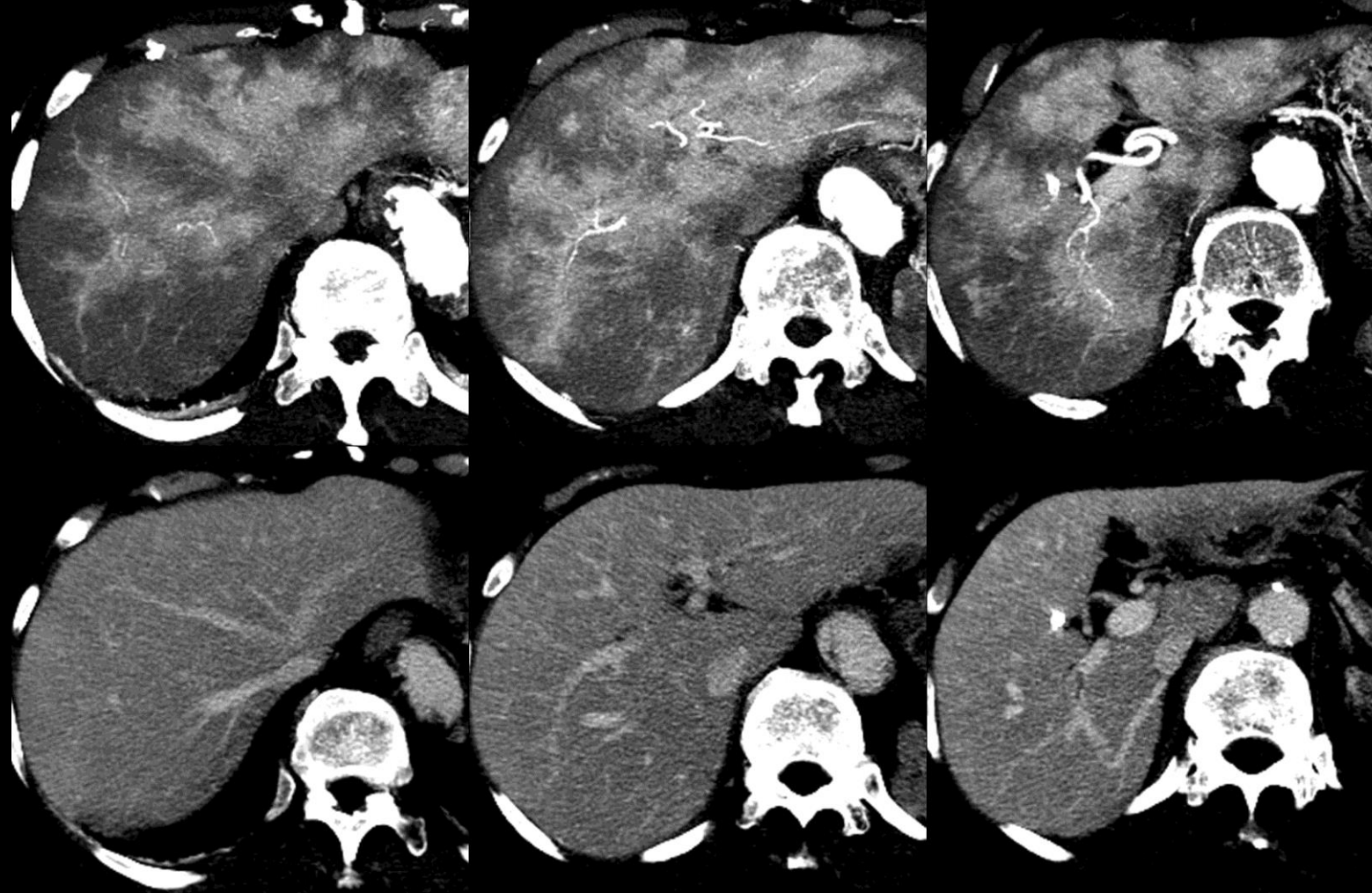
Slice 1

Slice 2

Slice 3

Arterial phase

Portal venous phase



**Perfusion alteration (CT):** Figure collage shows a diffuse transient hepatic attenuation difference (THAD) in a per-vascular distribution on three representative, non-consecutive images. The arterial hyper-enhancement fades to iso-attenuation on portal venous phase. Notice undistorted vessels and absence of mass effect.

**Perfusion alteration:****Pitfalls/Challenges/Differential Diagnosis:**

- Small rounded perfusion alterations may overlap in imaging appearance with small HCCs or other masses.
- Imaging features that, if present, favor perfusion alterations/THEDs over HCCs include:
  - Iso-enhancement to liver in portal venous phase and, if acquired, delayed phase
  - [Undistorted vessels](#) traversing the observation
  - Preserved hepatic architecture
  - Absence of mass effect
  - Elongated shape (e.g., along orientation of shunt vessel)
  - Iso-attenuation at unenhanced CT and iso-intensity at T2w, DW, and unenhanced T1w MRI
- Multiplanar images (source or reformatted) may help correctly characterize observations as perfusion alterations by showing undistorted vessels, preserved hepatic architecture, elongated shape.

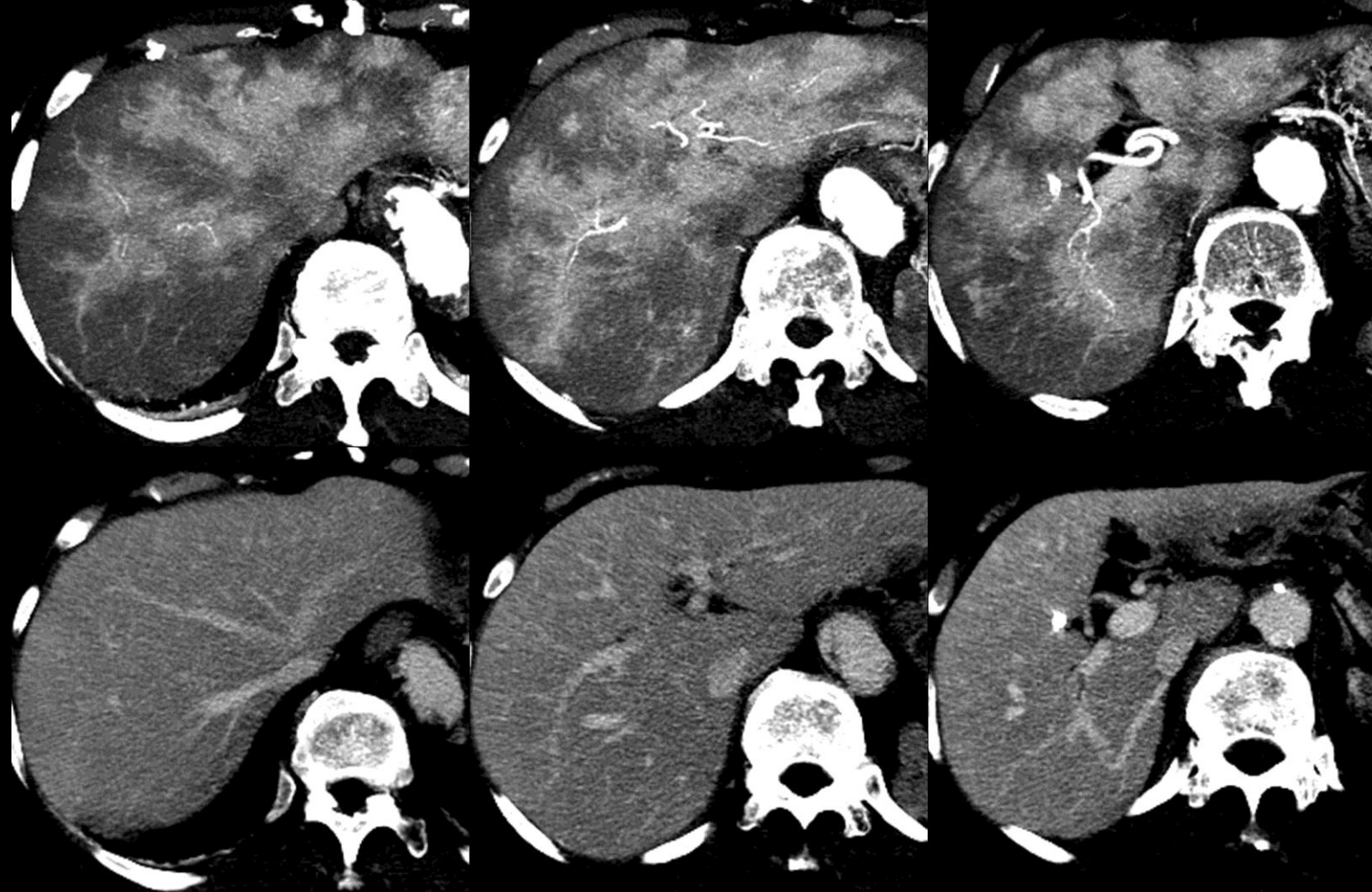
Slice 1

Slice 2

Slice 3

Arterial phase

Portal venous phase



**Perfusion alteration (CT):** Figure collage shows a diffuse transient hepatic attenuation difference (THAD) in a per-vascular distribution on three representative, non-consecutive images. The arterial hyper-enhancement fades to iso-attenuation on portal venous phase. Notice undistorted vessels and absence of mass effect.



**Perfusion alteration:****Pitfalls/Challenges/Differential Diagnosis (continued):**

- Nevertheless, some nodule-like perfusion alterations cannot reliably be differentiated from small masses at imaging.
- <20mm nodule-like areas of hyper-enhancement visible only in the arterial phase are known as [NAPHs](#).
  - NAPHs are thought to usually represent either perfusion alterations or small non-malignant masses (e.g., FNH-like lesion, hemangioma, dysplastic nodule), but occasionally small HCC. Click on [NAPH](#) link for additional details.
- While perfusion alterations/THEDs characteristically are hypo-attenuating at unenhanced CT and iso-intense at T1w and T2w MRI, perfusion alterations/THEDs occasionally show
  - Mild hypo-attenuation at CT or mild T1 hypo-intensity and T2 hyper-intensity at MRI (attributed to parenchymal edema)
  - Focal changes in hepatic parenchymal fat content (attributed to altered oxygen and nutrient supply).

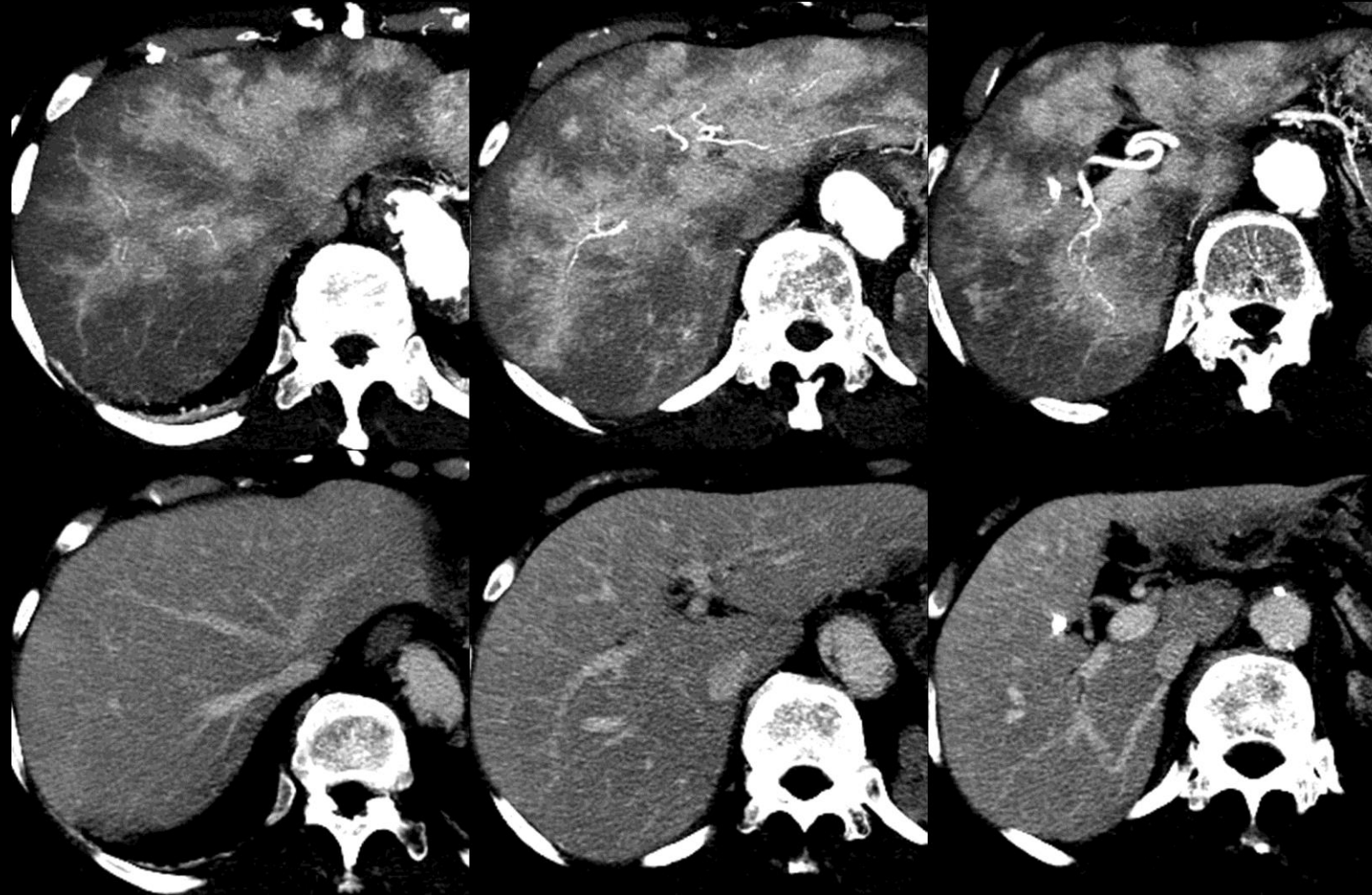
Slice 1

Slice 2

Slice 3

Arterial phase

Portal venous phase



**Perfusion alteration (CT):** Figure collage shows a diffuse transient hepatic attenuation difference (THAD) in a per-vascular distribution on three representative, non-consecutive images. The arterial hyper-enhancement fades to iso-attenuation on portal venous phase. Notice undistorted vessels and absence of mass effect.

**Perfusion alteration:****Other Comments:**

- While perfusion alterations/THEDs are benign, they may be caused by HCC via various mechanisms (regional hyperemia, trans-tumoral arterio-portal shunting, portal vein obstruction/invasion). Hence, perfusion alterations/THEDs should be scrutinized for presence of underlying HCC.
- In the setting of a geographic or triangular perfusion alteration, look carefully at the apex of the perfusion alteration for evidence of a small mass or portal vein obstruction.

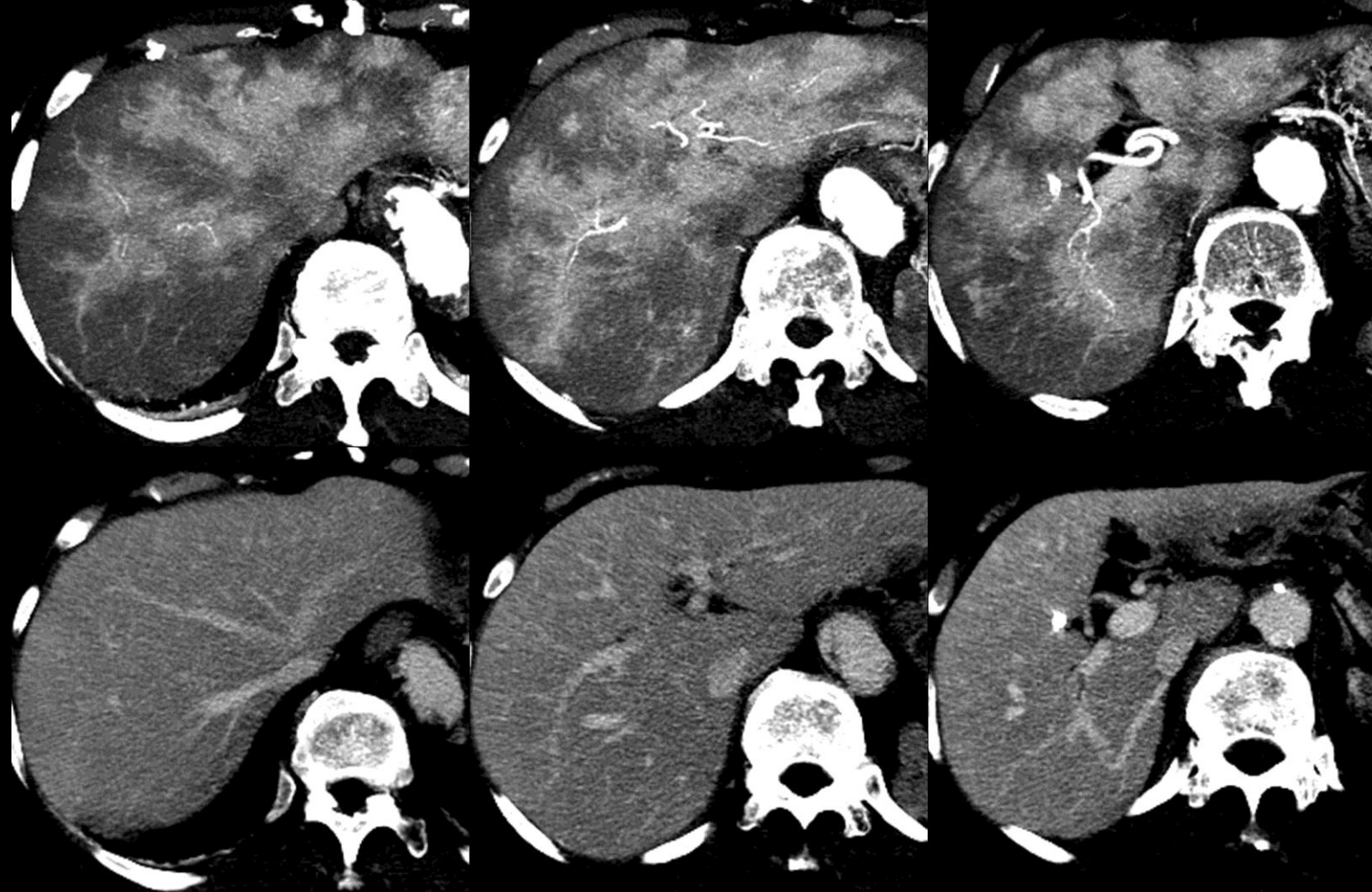
Slice 1

Slice 2

Slice 3

Arterial phase

Portal venous phase



**Perfusion alteration (CT):** Figure collage shows a diffuse transient hepatic attenuation difference (THAD) in a per-vascular distribution on three representative, non-consecutive images. The arterial hyper-enhancement fades to iso-attenuation on portal venous phase. Notice undistorted vessels and absence of mass effect.



## **Perivascular:**

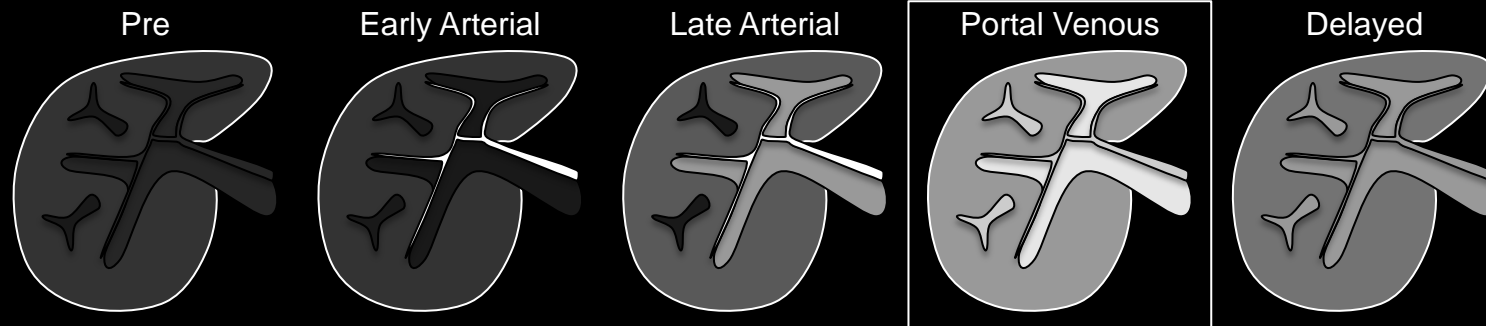
Along course of vessels, surrounding vessels.

## **Comments:**

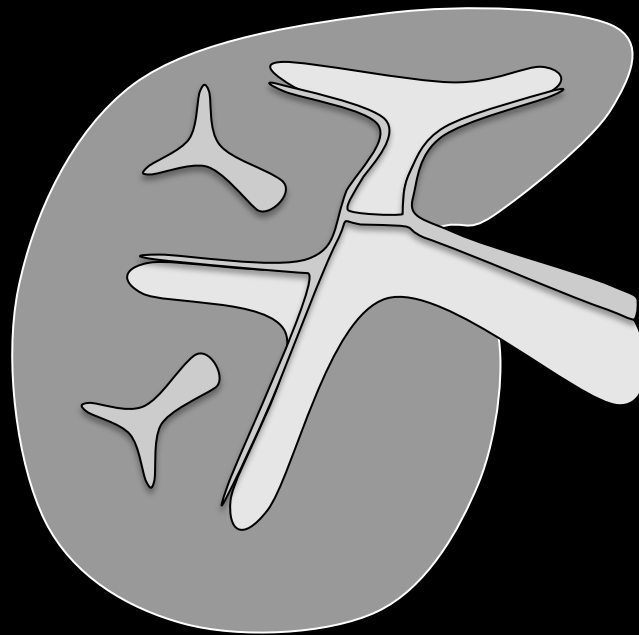
Used to describe the distribution of observations that run along the course of of vessels or that surround vessels.

**Atlas:** CT, MR





Portal Venous Phase

**Portal venous phase:**

Post-contrast injection time range in which images have the following characteristics:

- Portal veins are fully and maximally enhanced.
- Hepatic veins are enhanced by antegrade flow.
- Liver parenchyma usually is at peak enhancement.

**Comments:**

- Portal venous phase is required for both CT and MRI.

**Portal venous phase:** Schematic diagrams depict pre-contrast and post-extracellular contrast early arterial, late arterial, portal venous, and delayed phase images. Portal venous phase is defined by full enhancement of portal veins and antegrade enhancement of hepatic veins.

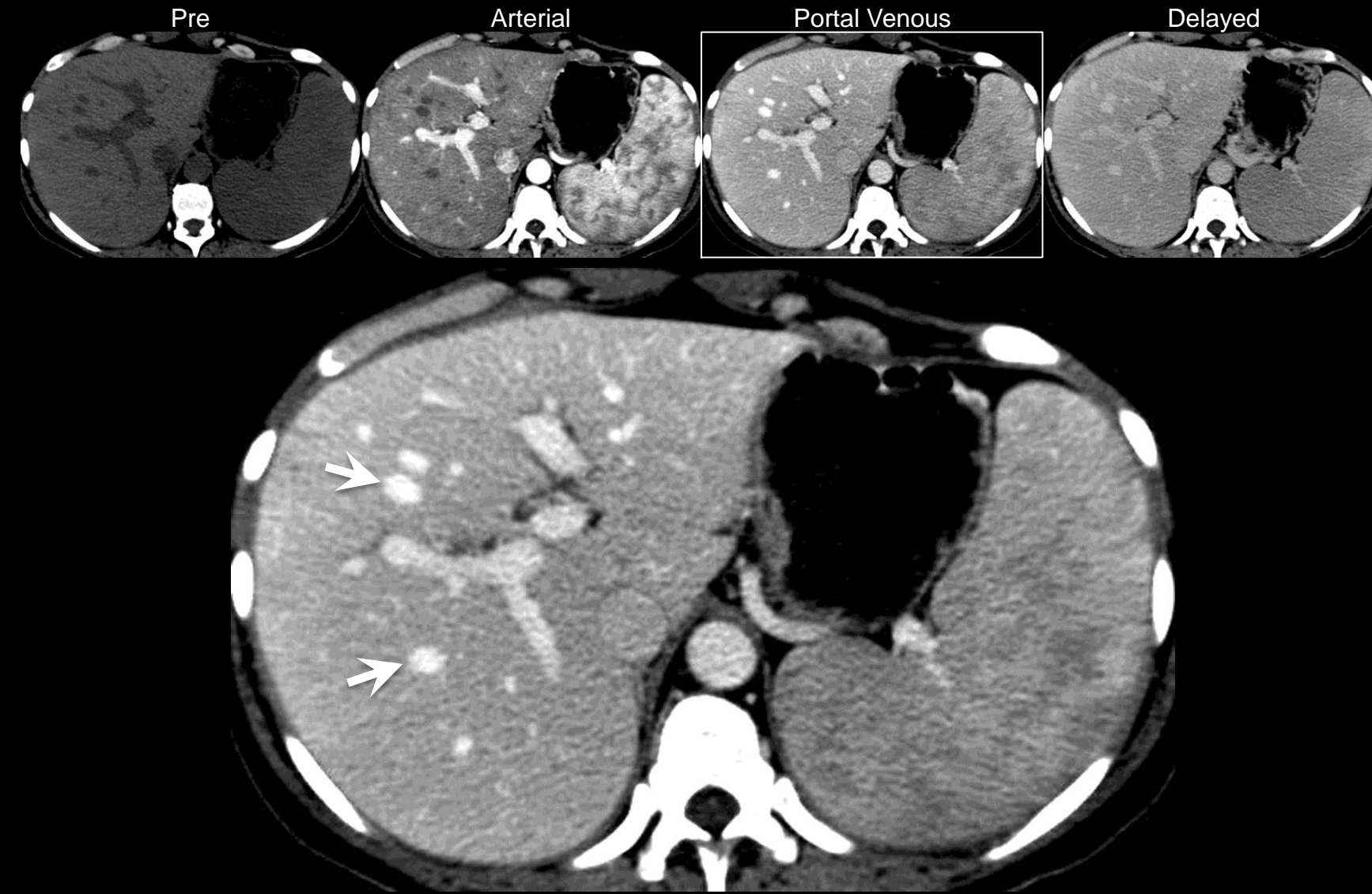**Portal venous phase:**

Post-contrast injection time range in which images have the following characteristics:

- Portal veins are fully and maximally enhanced.
- Hepatic veins are enhanced by antegrade flow.
- Liver parenchyma usually is at peak enhancement.

**Comments:**

- Portal venous phase is required for both CT and MRI.



**Portal venous phase (CT):** Portal venous phase CT image shows strong enhancement of portal vein branches. Hepatic veins (arrows) are enhanced by antegrade flow. Liver parenchyma is at peak enhancement.

**Portal venous phase:**

Post-contrast injection time range in which images have the following characteristics:

- Portal veins are fully and maximally enhanced.
- Hepatic veins are enhanced by antegrade flow.
- Liver parenchyma usually is at peak enhancement.

**Comments:**

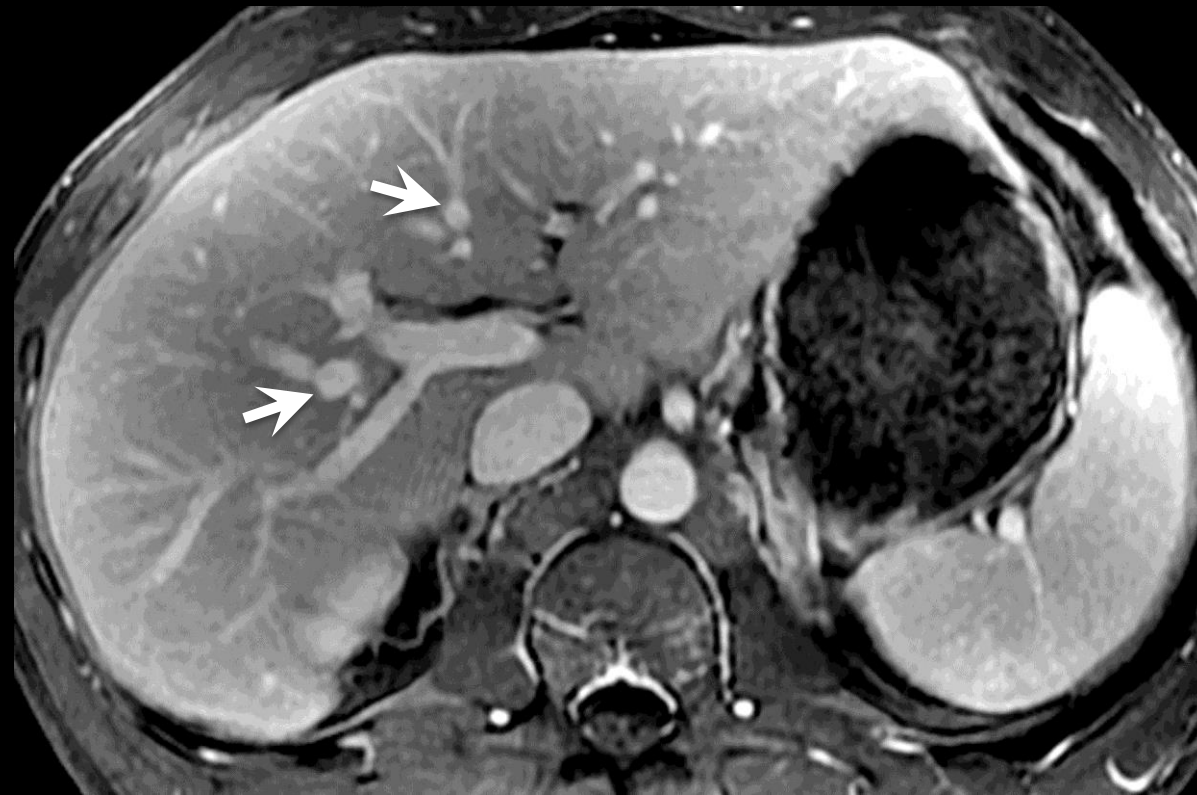
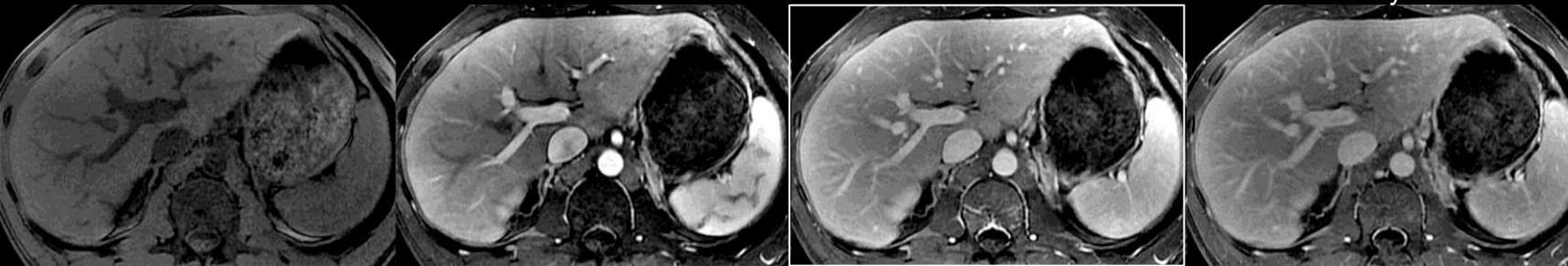
- Portal venous phase is required for both CT and MRI.

Pre

Arterial

Portal Venous

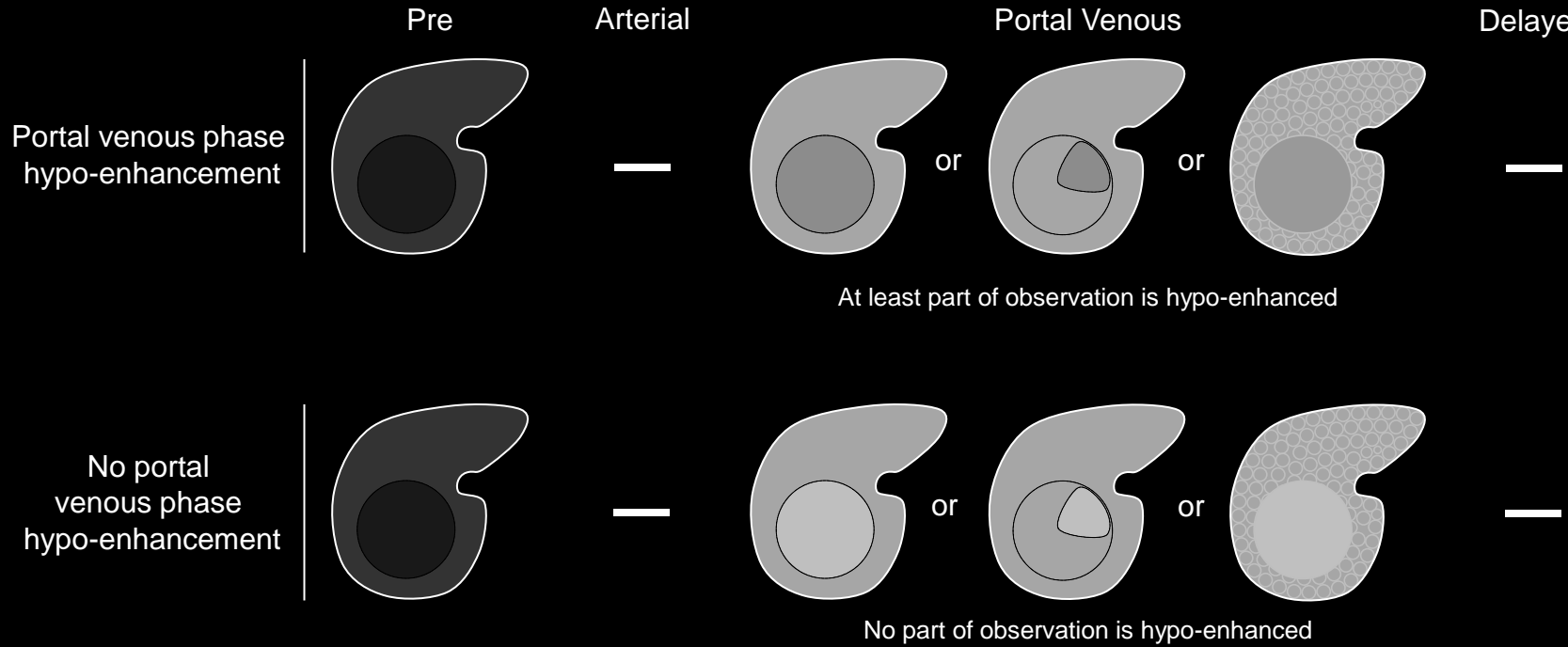
Delayed



**Portal venous phase (MRI):** Portal venous phase MR image shows strong enhancement of portal vein branches. Hepatic veins (arrows) are enhanced by antegrade flow. Liver parenchyma is at peak enhancement.

Atlas: [CT](#), [Schematic](#)





**Portal venous phase hypo-enhancement:** Schematic diagrams illustrate observations with (top row) and without (bottom row) portal venous phase hypo-enhancement. Observations with portal venous phase hypo-enhancement are enhancing observations that, in whole or in part, unequivocally are lower in attenuation or intensity than liver in the portal venous phase, regardless of degree of enhancement in arterial or delayed phase. Observations may be hypo-(this slide), iso- ([click here](#)), or hyper- ([click here](#)) attenuating/intense pre-contrast. If the liver parenchyma visually consists of both nodules and fibrosis (first row, portal venous phase, right-most liver), then enhancement of the observation should be compared to that of the composite liver tissue.

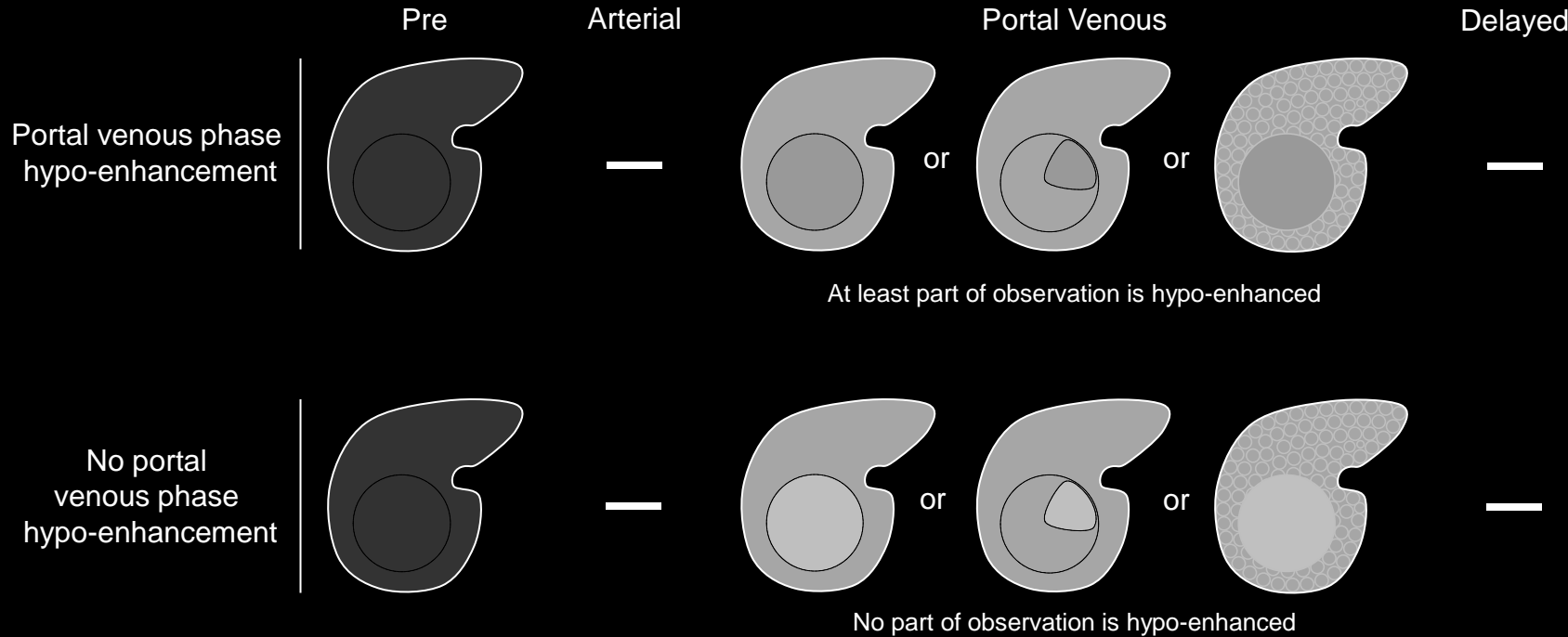
## Portal venous phase hypo-enhancement:

Enhancement in the [portal venous phase](#) that [unequivocally](#) is less than that of liver.

### Comments:

- Applies only to enhancing observations that, in whole or in part, unequivocally are lower in attenuation or intensity than liver in the portal venous phase.
- Does not apply to non-enhancing observations.
- The degree of arterial phase and delayed phase enhancement is not relevant for characterization of this imaging feature.
- The attenuation or intensity of the observation should be compared to that of the adjacent liver parenchyma. If the liver parenchyma visually consists of both nodules and fibrosis, then attenuation or intensity of the observation should be compared to that of the composite liver tissue (i.e., a visual average of the nodules and fibrosis) (see schematics on left).
- Portal venous phase hypo-enhancement is part of the definition of [“washout”](#).
- Washout appearance is a LI-RADS major feature. It is defined as a temporal reduction in enhancement relative to liver from an earlier to a later phase, resulting in portal venous phase hypo-enhancement or [delayed phase hypo-enhancement](#).

**Atlas:** CT, MR



**Portal venous phase hypo-enhancement:** Schematic diagrams illustrate observations with (top row) and without (bottom row) portal venous phase hypo-enhancement. Observations with portal venous phase hypo-enhancement are enhancing observations that, in whole or in part, unequivocally are lower in attenuation or intensity than liver in the portal venous phase, regardless of degree of enhancement in arterial or delayed phase. Observations may be hypo- ([click here](#)), iso- (this slide), or hyper- ([click here](#)) attenuating/intense pre-contrast. If the liver parenchyma visually consists of both nodules and fibrosis (first row, portal venous phase, right-most liver), then enhancement of the observation should be compared to that of the composite liver tissue.

## Portal venous phase hypo-enhancement:

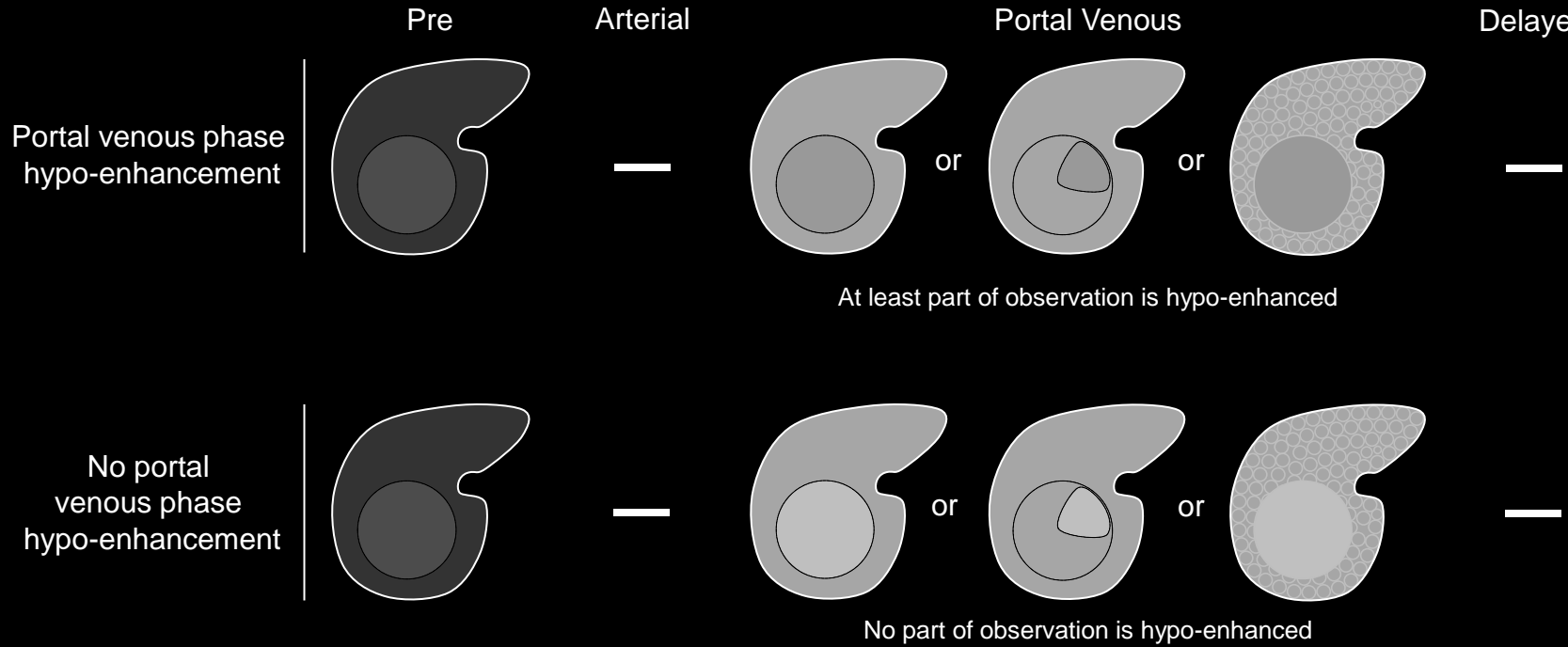
Enhancement in the [portal venous phase](#) that [unequivocally](#) is less than that of liver.

### Comments:

- Applies only to enhancing observations that, in whole or in part, unequivocally are lower in attenuation or intensity than liver in the portal venous phase.
- Does not apply to non-enhancing observations.
- The degree of arterial phase and delayed phase enhancement is not relevant for characterization of this imaging feature.
- The attenuation or intensity of the observation should be compared to that of the adjacent liver parenchyma. If the liver parenchyma visually consists of both nodules and fibrosis, then attenuation or intensity of the observation should be compared to that of the composite liver tissue (i.e., a visual average of the nodules and fibrosis) (see schematics on left).
- Portal venous phase hypo-enhancement is part of the definition of [“washout”](#).
- Washout appearance is a LI-RADS major feature. It is defined as a temporal reduction in enhancement relative to liver from an earlier to a later phase, resulting in portal venous phase hypo-enhancement or [delayed phase hypo-enhancement](#).

**Atlas:** CT, MR





## Portal venous phase hypo-enhancement:

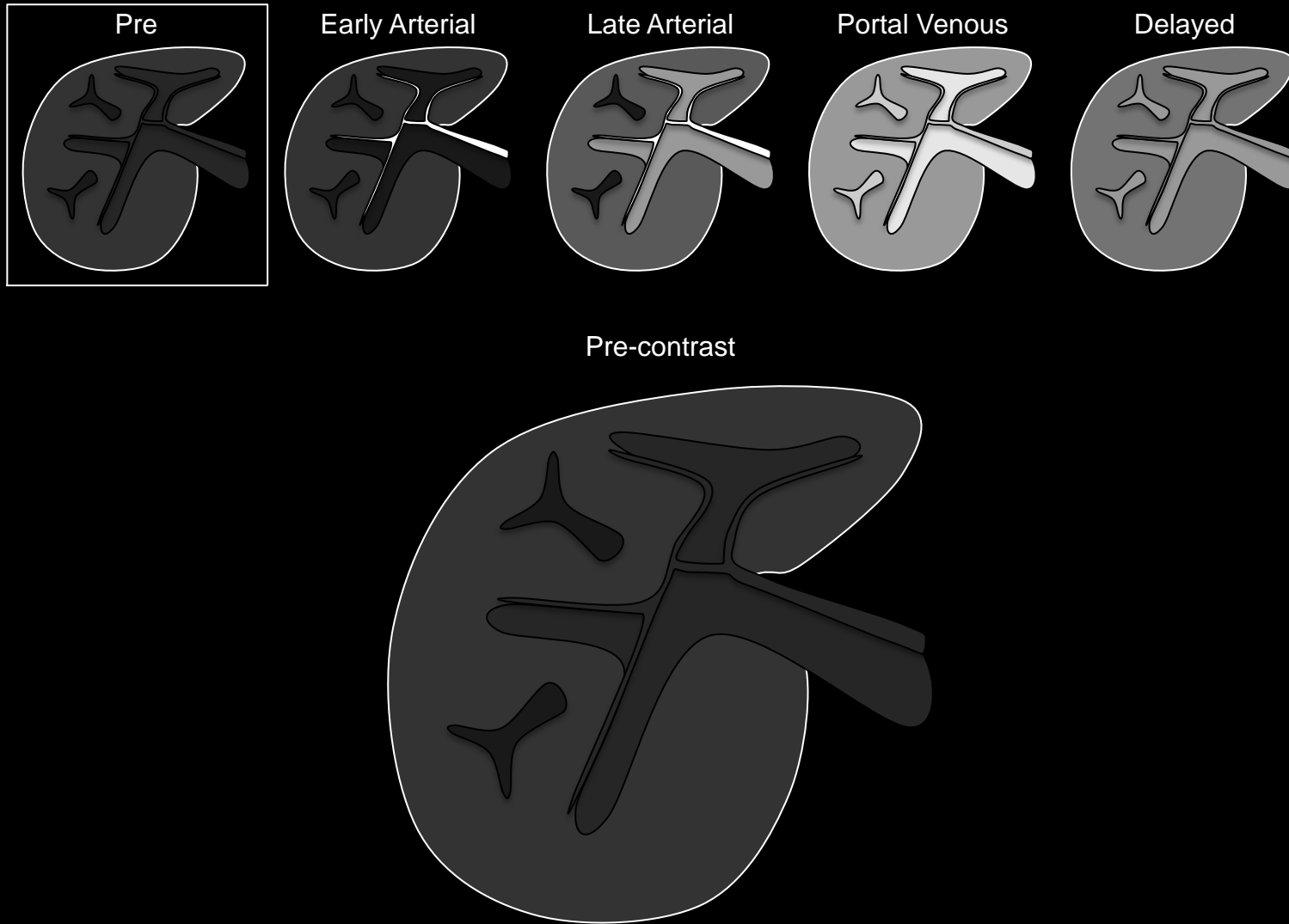
Enhancement in the [portal venous phase](#) that [unequivocally](#) is less than that of liver.

### Comments:

- Applies only to enhancing observations that, in whole or in part, unequivocally are lower in attenuation or intensity than liver in the portal venous phase.
- Does not apply to non-enhancing observations.
- The degree of arterial phase and delayed phase enhancement is not relevant for characterization of this imaging feature.
- The attenuation or intensity of the observation should be compared to that of the adjacent liver parenchyma. If the liver parenchyma visually consists of both nodules and fibrosis, then attenuation or intensity of the observation should be compared to that of the composite liver tissue (i.e., a visual average of the nodules and fibrosis) (see schematics on left).
- Portal venous phase hypo-enhancement is part of the definition of [“washout”](#).
- Washout appearance is a LI-RADS major feature. It is defined as a temporal reduction in enhancement relative to liver from an earlier to a later phase, resulting in portal venous phase hypo-enhancement or [delayed phase hypo-enhancement](#).

**Portal venous phase hypo-enhancement:** Schematic diagrams illustrate observations with (top row) and without (bottom row) portal venous phase hypo-enhancement. Observations with portal venous phase hypo-enhancement are enhancing observations that, in whole or in part, unequivocally are lower in attenuation or intensity than liver in the portal venous phase, regardless of degree of enhancement in arterial or delayed phase. Observations may be hypo-[\(click here\)](#), iso- [\(click here\)](#), or hyper- (this slide) attenuating/intense pre-contrast. If the liver parenchyma visually consists of both nodules and fibrosis (first row, portal venous phase, right-most liver), then enhancement of the observation should be compared to that of the composite liver tissue.

**Atlas:** CT, MR

**Pre-contrast imaging:**

Images acquired before intravenous contrast administration.

**Comments:**

- Pre-contrast imaging is required for MRI and suggested for CT.
- Should be acquired, if possible, with same acquisition parameters as post-contrast imaging.
- Used to determine intrinsic attenuation/T1 intensity of observations relative to reference tissue such as liver.
  - At CT: this may provide information on presence and distribution of fat, iron, calcification, blood products, and, if post embolization, iodized oil.
- Used as baseline to gauge enhancement on post-contrast images.
  - At MRI, pre-contrast images may be subtracted from arterial phase images. For observations that are hyper-intense pre-contrast, such subtractions may help in the assessment of arterial phase enhancement.
  - For subtractions to be valid, arterial phase and pre-contrast images need to be acquired with the same technique.

**Pre-contrast imaging:** Schematic diagrams depict pre-contrast and post-extracellular contrast early arterial, late arterial, portal venous, and delayed phase images. Pre-contrast imaging is required for MRI and suggested for CT. It is used as a baseline to gauge enhancement on post-contrast images.

**Pre-contrast imaging:**

Images acquired before intravenous contrast administration.

**Comments:**

- Pre-contrast imaging is required for MRI and suggested for CT.
- Should be acquired, if possible, with same acquisition parameters as post-contrast imaging.
- Used to determine intrinsic attenuation/T1 intensity of observations relative to reference tissue such as liver.
  - At CT: this may provide information on presence and distribution of fat, iron, calcification, blood products, and, if post embolization, iodized oil.
- Used as baseline to gauge enhancement on post-contrast images.
  - At MRI, pre-contrast images may be subtracted from arterial phase images. For observations that are hyper-intense pre-contrast, such subtractions may help in the assessment of arterial phase enhancement.
  - For subtractions to be valid, arterial phase and pre-contrast images need to be acquired with the same technique.

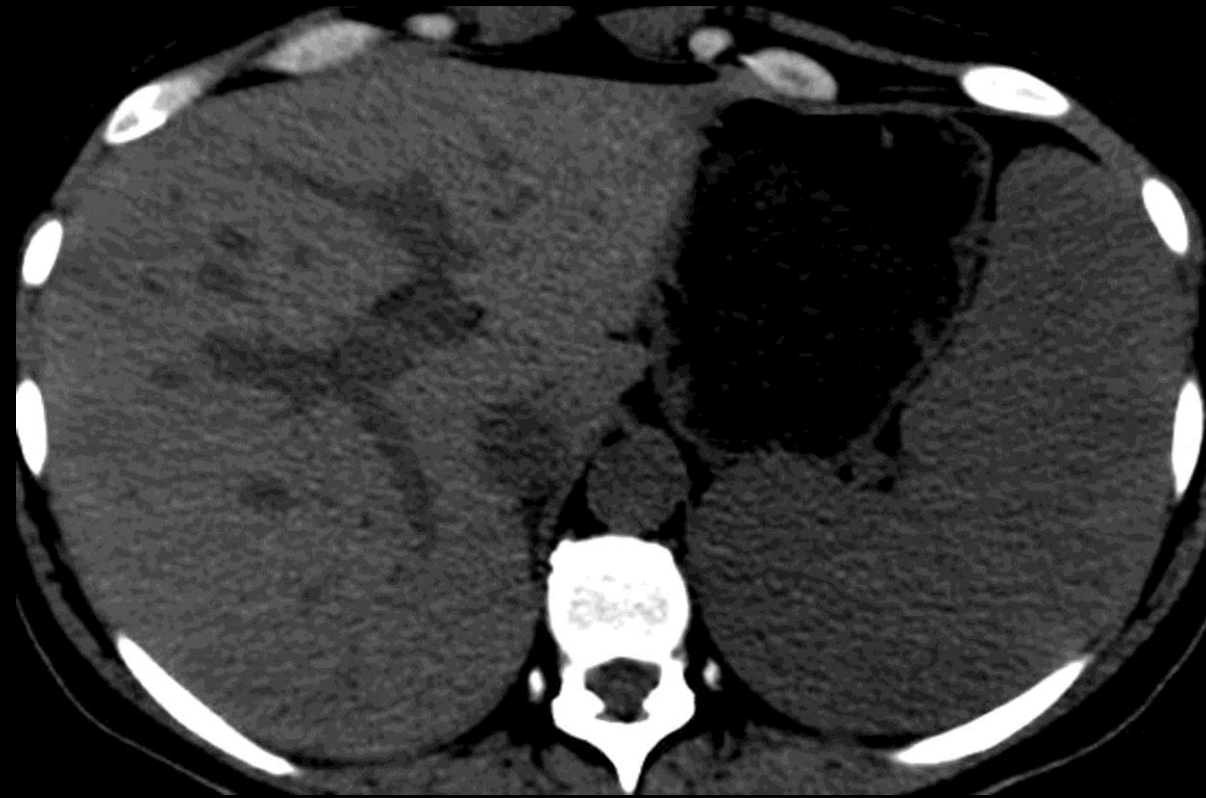
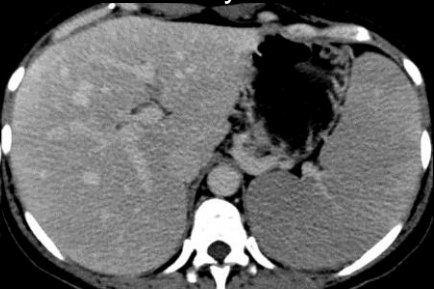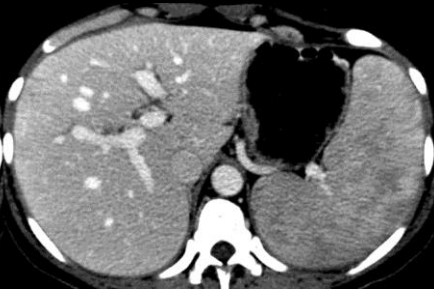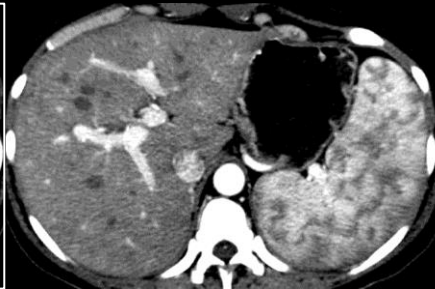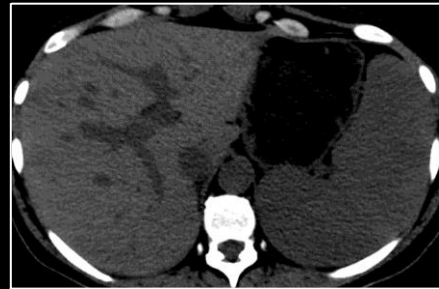Atlas: [MR](#), [Schematic](#)

Pre

Arterial

Portal Venous

Delayed



**Pre-contrast imaging (CT):** Pre-contrast CT image shows un-enhanced vessels, liver, and spleen.



**Pre-contrast imaging:**

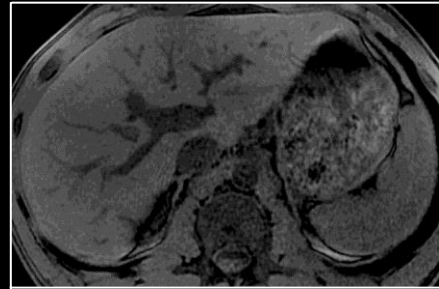
Images acquired before intravenous contrast administration.

**Comments:**

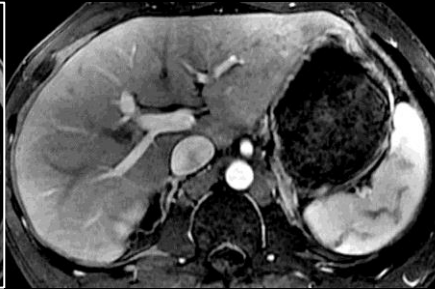- Pre-contrast imaging is required for MRI and suggested for CT.
- Should be acquired, if possible, with same acquisition parameters as post-contrast imaging.
- Used to determine intrinsic attenuation/T1 intensity of observations relative to reference tissue such as liver.
  - At CT: this may provide information on presence and distribution of fat, iron, calcification, blood products, and, if post embolization, iodized oil.
- Used as baseline to gauge enhancement on post-contrast images.
  - At MRI, pre-contrast images may be subtracted from arterial phase images. For observations that are hyper-intense pre-contrast, such subtractions may help in the assessment of arterial phase enhancement.
  - For subtractions to be valid, arterial phase and pre-contrast images need to be acquired with the same technique.

Atlas: [CT](#), [Schematic](#)

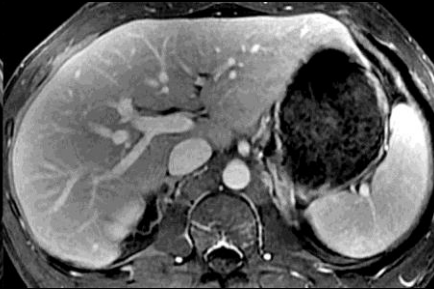Pre



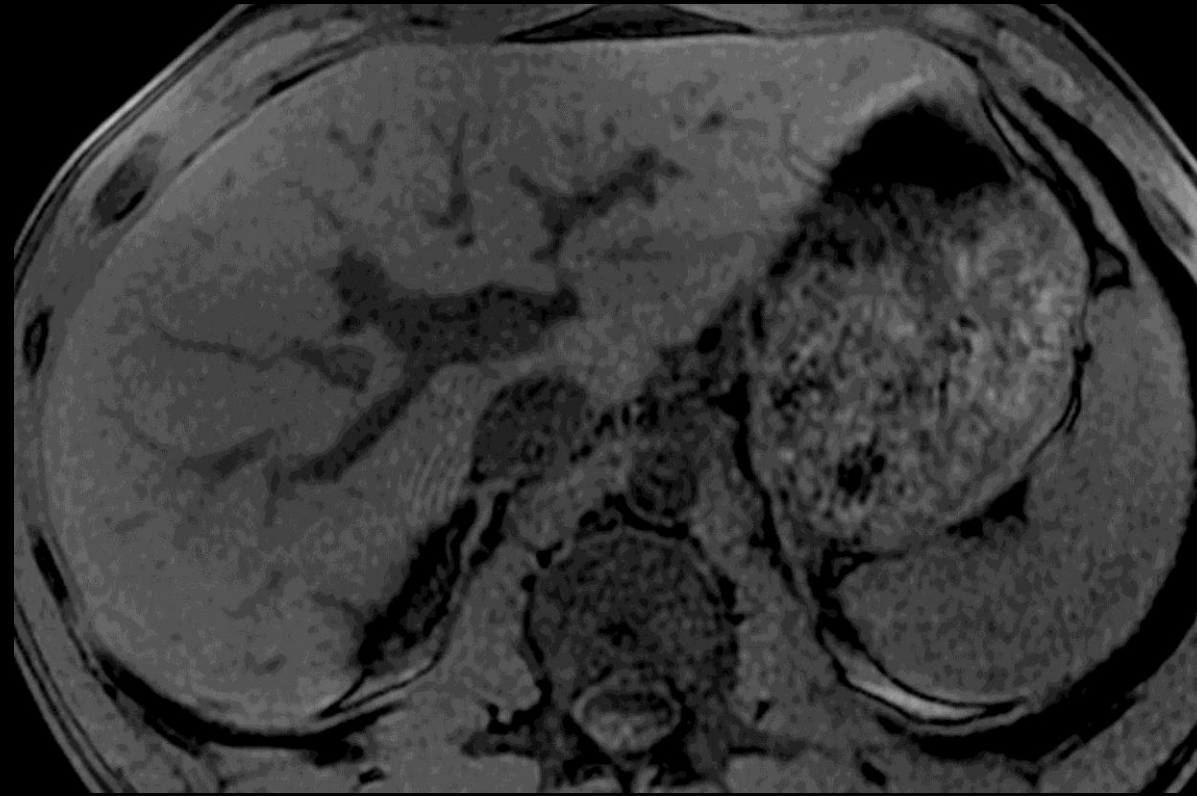
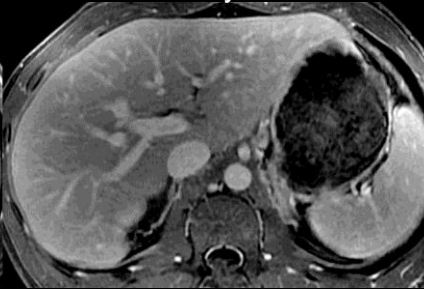Arterial



Portal Venous



Delayed



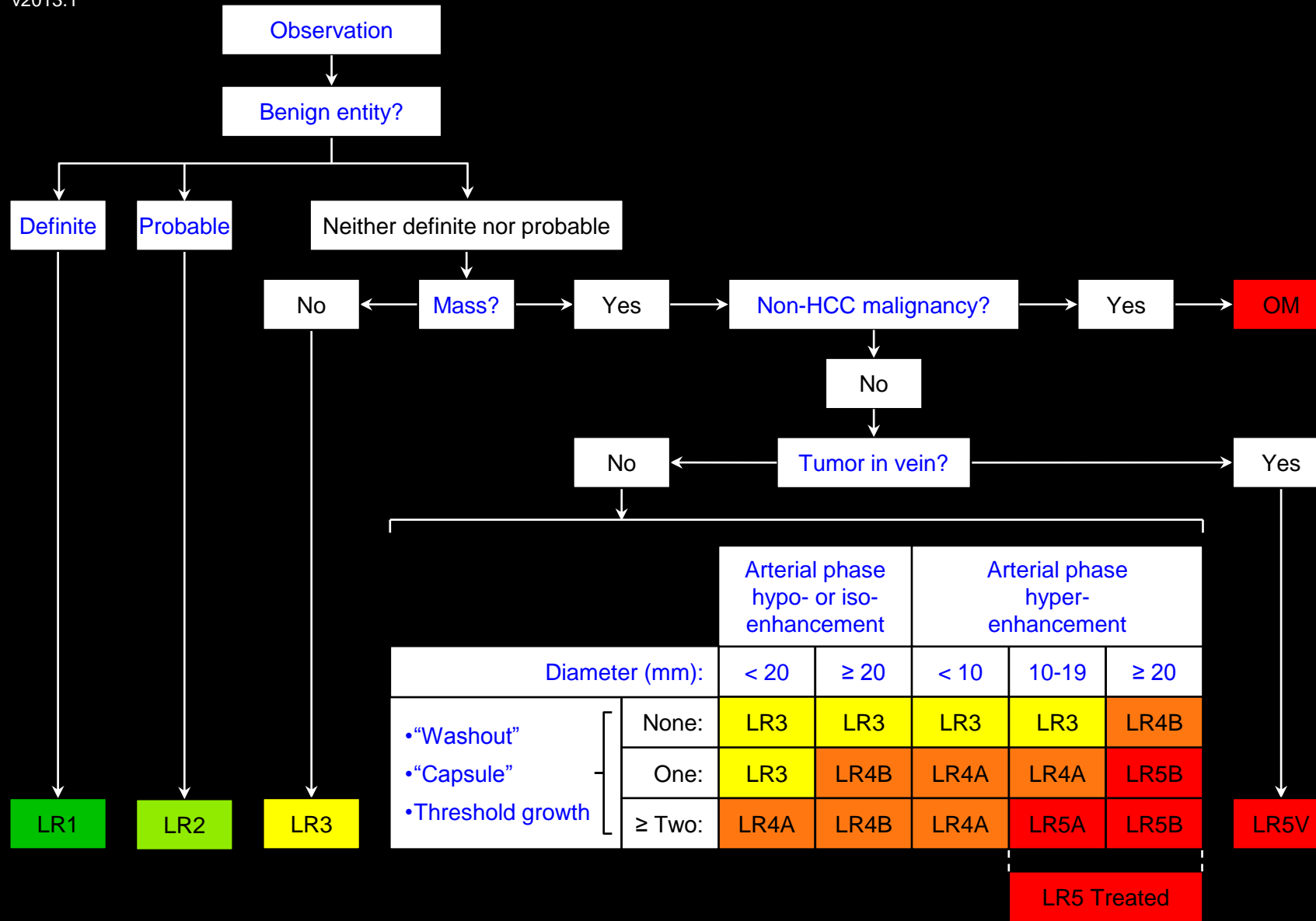
**Pre-contrast imaging (MRI):** Pre-contrast MR image shows un-enhanced vessels, liver, and spleen.



**Probable:**

Likely to be true.





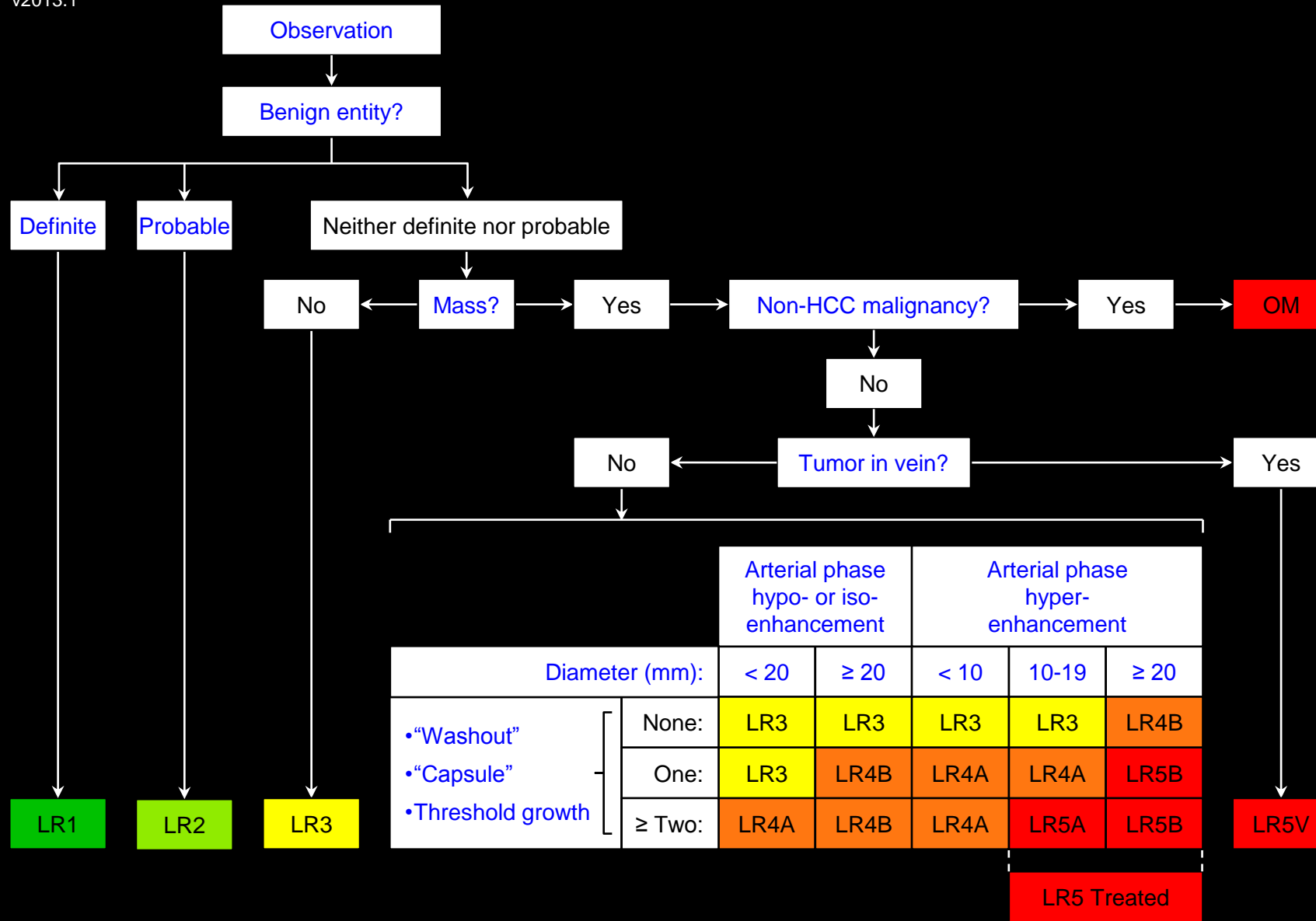
Apply Ancillary Features and then Tie-Breaking Rules to Adjust Category

## Probable benign entities (examples):

- Probable:
  - [Cyst](#)
  - [Hemangioma](#)
  - [Vascular anomaly](#)
  - [Perfusion alteration](#)
  - [Hepatic fat deposition](#) or [sparing](#)
  - [Hypertrophic pseudomass](#)
  - [Confluent fibrosis](#)
  - [Focal scar](#)
  - LR2 [cirrhosis associated nodule](#)

## Comments:

- With few exceptions, the list of [definite benign entities](#) and probable benign entities is the same. The categorization as LR1 or LR2 depends on the level of certainty.
- Observations with features [diagnostic](#) of a benign entity are categorized LR1.
- Observations with features [suggestive](#) of but not [diagnostic](#) of a benign entity are categorized LR2. For example, an observation thought to be a benign entity but with [atypical](#) imaging features is appropriately categorized LR2.
- Observations with features equivocal for benign entities, that do not meet LR4 or LR5 criteria, and that do not have features suggestive of [non-HCC malignancy](#) should be categorized LR3.



Apply Ancillary Features and then Tie-Breaking Rules to Adjust Category

## Probable benign entities (examples):

### Comments (continued):

- LI-RADS v2013.1 does not list focal nodular hyperplasia (FNH) or hepatocellular adenoma (HCA) as examples of benign entities.
- Rationale:** Although FNH-like lesions may occur in cirrhosis, they are rare and they are difficult to diagnose reliably by non-invasive imaging. HCAs are rare in cirrhosis.
- LI-RADS v2013.1 does not address regenerative nodules occurring in the absence of cirrhosis (e.g., Budd-Chiari-associated RNs).

**Pseudocapsule:**

Imaging appearance of a “capsule” around a mass when no true tumor capsule is present at histological evaluation.

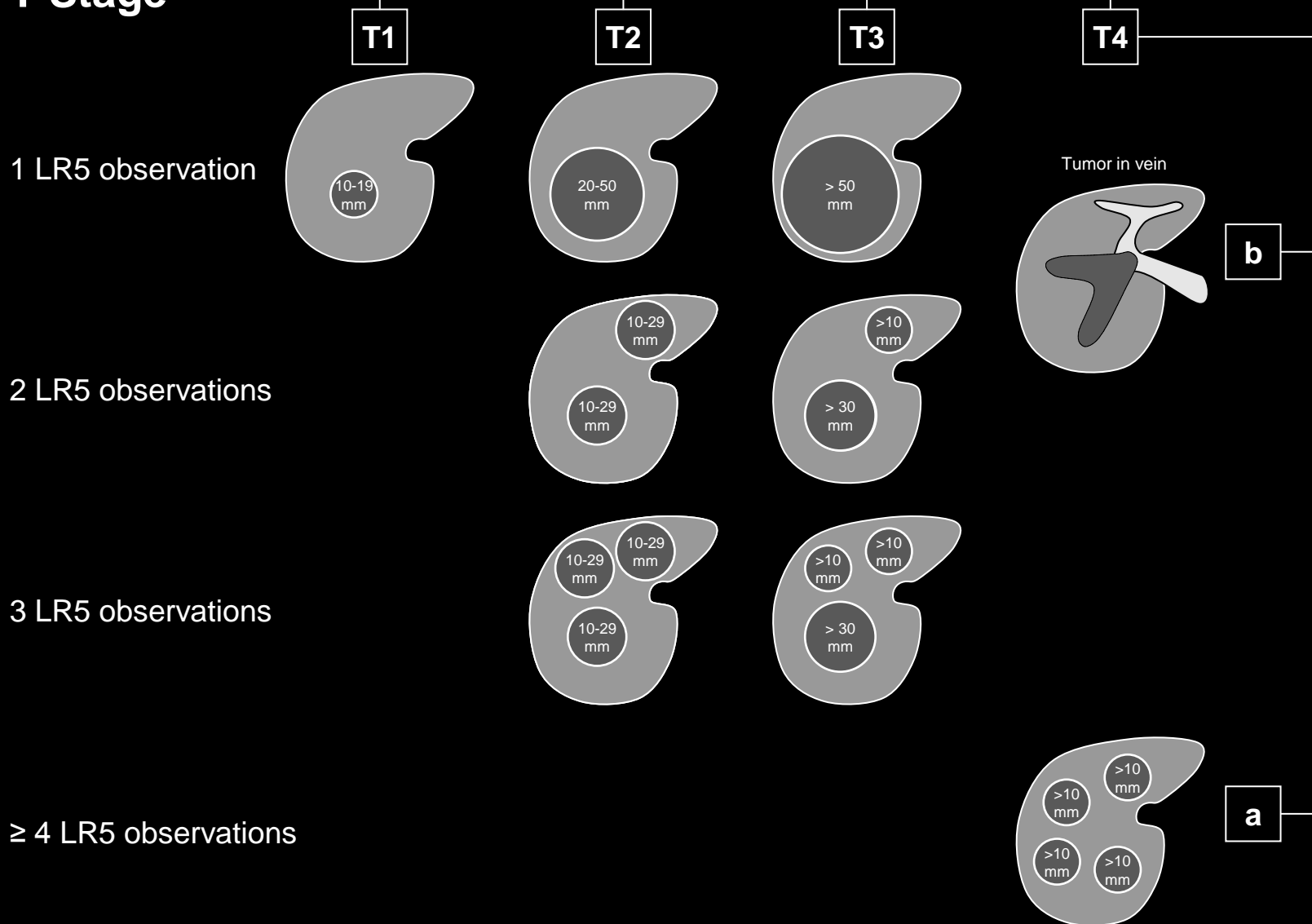
**Comments:**

- Attributed to compressed parenchyma, fibrosis (i.e., mixed fibrous tissue or septal fibrosis similar to that surrounding cirrhotic nodules), or dilated sinusoids/blood vessels around mass, or a combination of the above.
- A rim of [increasing enhancement](#) in the portal venous phase or delayed phase around a mass at imaging is termed [capsule appearance](#) (synonym: portal venous/delayed phase peripheral rim enhancement).
- Capsule appearance may represent a [true tumor capsule](#) or a pseudocapsule.
  - Imaging does not reliably differentiate between a true tumor capsule and a pseudocapsule.
  - The distinction between a true tumor capsule and pseudocapsule can only be made at pathology.
- In at-risk patients, capsule appearance has high positive predictive value for HCC, regardless of whether rim of enhancement represents a [true tumor capsule](#) or a pseudocapsule.

**Atlas:** CT, MR



## T-Stage



## Radiologic T-stage:

Tumor stage based on non-invasive imaging.

### Comments:

- Radiologic T-stages are based on the American Liver Tumor Study Group modified TNM staging classification. This system is used in transplant centers in the United States for determining priority for liver transplantation.
- Radiologic T-stages T1, T2, T3, and T4a are determined by the size and number of individual LR5 observations as illustrated in schematic and summarized below:
  - T1: One 10-19mm LR5 observation.
  - T2: One 20-50mm LR5 observation OR two to three 10-29mm LR5 observations.
  - T3: One >50mm LR5 observation OR two to three LR5 observations at least one of which is > 30mm.
  - T4a: At least four >10mm LR5 observations.
    - With caution, radiologists may assign a radiologic T-stage 4a to a patient with innumerable LR4 observations that, while individually not meeting LR5 criteria, in aggregate are interpreted as definite multifocal HCC.
- The presence of tumor in vein (LR5V) denotes radiologic T-stage 4b, regardless of the size or number of individual observations

**Radiologic T-staging using LI-RADS:** Schematic diagram illustrates assignment of T-stage based on size and number of LR5 observations. Regardless of size and number, presence of tumor in vein (LR5V) denotes stage T4b.



LR1	→	Report at radiologist's discretion
LR2	→	Report at radiologist's discretion
LR3	→	Should be reported
LR4	→	Must be reported
LR5	→	Must be reported
LR5V	→	Must be reported
OM	→	Must be reported

## LI-RADS Reporting:

[LR1 and LR2](#)

[LR3](#)

[LR4, LR5, LR5V, OM](#)

[Reporting standards](#)

[Reporting template](#)





LR1	→	Report at radiologist's discretion
LR2	→	Report at radiologist's discretion
LR3	→	Should be reported
LR4	→	Must be reported
LR5	→	Must be reported
LR5V	→	Must be reported
OM	→	Must be reported

## LI-RADS Reporting:

### LR1 and LR2:

Observations that are easily recognized as definite benign entities (LR1) or probable benign entities (LR2), that cause no diagnostic confusion, and that are considered to have little or no clinical relevance do not necessarily need to be reported.

- Radiologists at their discretion may report such observations. If they are reported, they may be reported in aggregate.
- Exception: LR1 and LR2 observations that on the previous examination were reported as LR3, LR4, or LR5 usually should be reported. If they are reported, it may be more appropriate to report them individually rather than in aggregate.
- **Rationale:** the interval downgrade in category may alter management or prognosis.



LR1	→	Report at radiologist's discretion
LR2	→	Report at radiologist's discretion
LR3	→	Should be reported
LR4	→	Must be reported
LR5	→	Must be reported
LR5V	→	Must be reported
OM	→	Must be reported

## LI-RADS Reporting:

### LR3:

The reporting of observations categorized LR3 depends on the presence of LR4, LR5, or OM observations elsewhere in the liver:

- If there are no LR4, LR5, or OM observations: LR3 observations should be reported.
- If LR4, LR5, or OM observations are present: LR3 observations may be reported at radiologist's discretion.
- If LR3 observations are reported, they may be reported in aggregate.
- Exception: LR3 observations that on the previous examination were reported as LR4 or LR5 usually should be reported, regardless of the presence of LR4, LR5, or OM observations elsewhere in the liver. If they are reported, it may be more appropriate to report them individually rather than in aggregate.
- **Rationale:** the interval downgrade in category may alter management or prognosis.



LR1	→	Report at radiologist's discretion
LR2	→	Report at radiologist's discretion
LR3	→	Should be reported
LR4	→	Must be reported
LR5	→	Must be reported
LR5V	→	Must be reported
OM	→	Must be reported

## LI-RADS Reporting:

### [LR4](#), [LR5](#), [LR5V](#), and [OM](#):

- Observations categorized LR4, LR5, LR5V, or OM must be reported, including if measurable their [diameter](#).
- Up to the five highest categorized observations should be reported individually; additional LR4, LR5, or OM observations may be reported in aggregate.



LR1	→	Report at radiologist's discretion
LR2	→	Report at radiologist's discretion
LR3	→	Should be reported
LR4	→	Must be reported
LR5	→	Must be reported
LR5V	→	Must be reported
OM	→	Must be reported

## LI-RADS Reporting:

### Reporting standards:

*Pending.*



LR1	→	Report at radiologist's discretion
LR2	→	Report at radiologist's discretion
LR3	→	Should be reported
LR4	→	Must be reported
LR5	→	Must be reported
LR5V	→	Must be reported
OM	→	Must be reported

## LI-RADS Reporting:

### Reporting template:

*Pending.*



**Restricted diffusion:**

Having higher signal intensity, not attributable solely to T2 shine-through, than liver on diffusion-weighted (DW) images.

**Comments:**

- Applies to observations that [unequivocally](#):
  - Are hyper-intense relative to liver on DW images acquired with at least moderate diffusion weighting (e.g.,  $b \geq 400$  s/mm<sup>2</sup>) AND
  - If ADC map is generated, have low apparent diffusion coefficient (ADC) – i.e., similar to or lower than that of liver by visual estimation.
- Restricted diffusion is an [ancillary feature](#) favoring HCC.
- Radiologists at their discretion may apply restricted diffusion to upgrade category (up to LR4).

**Atlas:** CT, MR



## **Rounded:**

Having a curved boundary.

**Atlas:** CT, MR



## Scar:

Fibrous tissue that has replaced normal liver parenchyma as a result of repetitive injury or insult.

**Atlas:** CT, MR



## Subcapsular:

Located at the liver periphery, subjacent to the liver capsule.

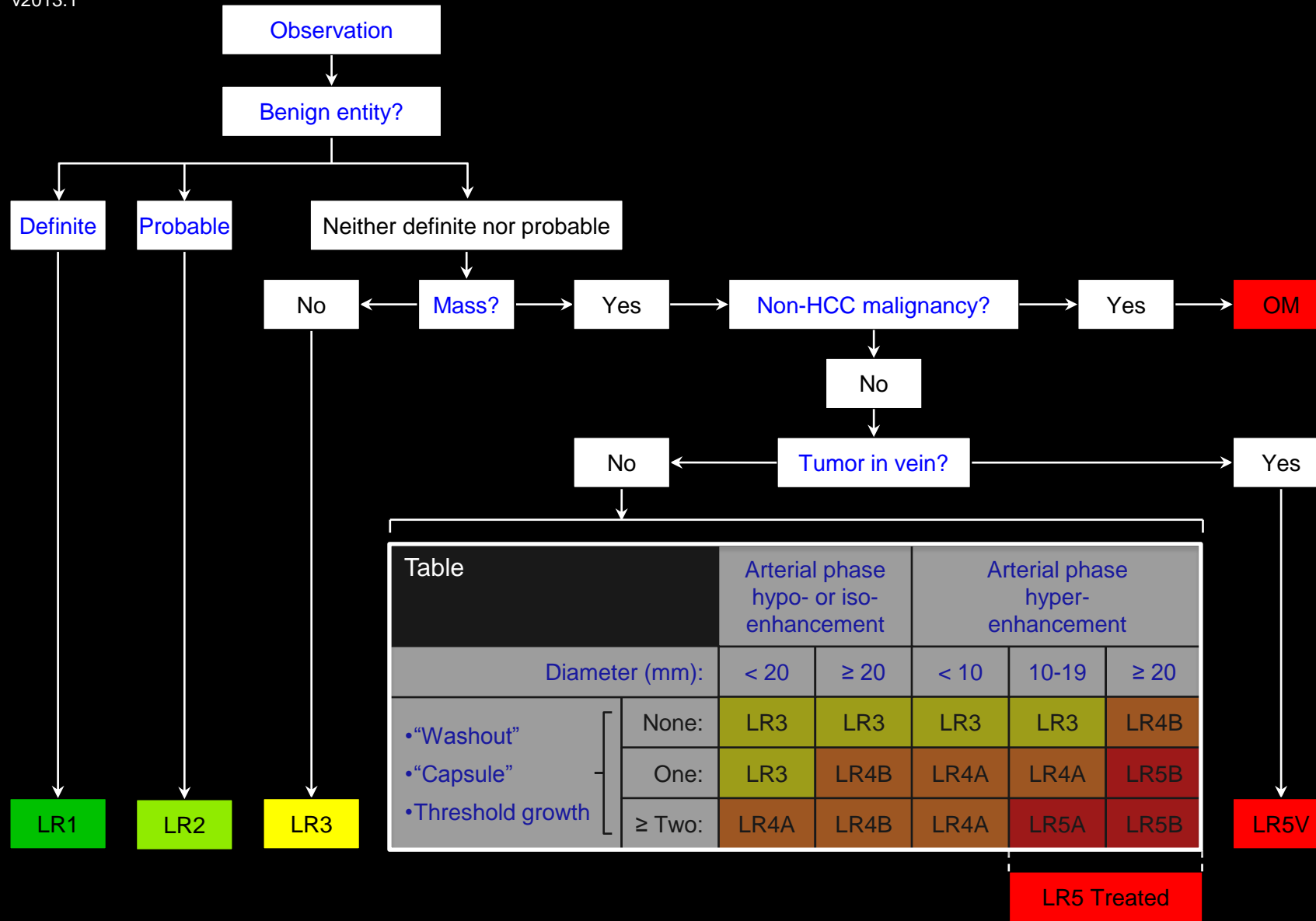
**Atlas:** CT, MR



## **Suggestive:**

Features that raise a strong possibility of a diagnosis.





Apply Ancillary Features and then Tie-Breaking Rules to Adjust Category

### Table:

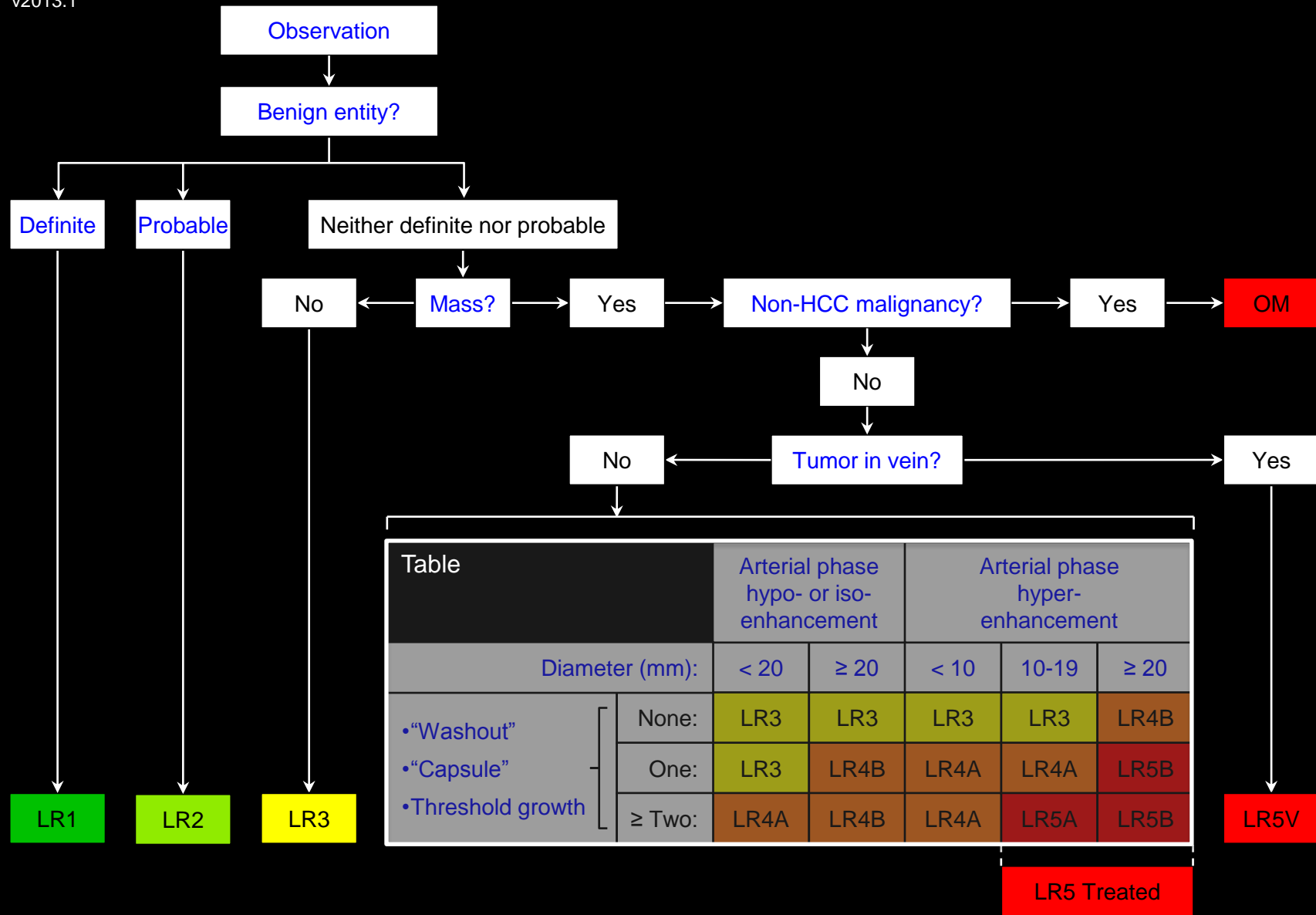
Table summarizes categorization as [LR3](#), [LR4](#), or [LR5](#) masses that are neither [definite benign entities](#) nor [probable benign entities](#) and that lack features of [non-HCC malignancy](#) or [tumor in vein](#).

### To assign a LI-RADS category using Table:

- Characterize each mass as follows:
  - Degree of arterial phase enhancement
    - [Arterial phase hypo- or iso-enhancement](#) vs. [arterial phase hyper-enhancement](#)
  - [Diameter](#)
    - [< 20mm](#) vs. [≥ 20mm](#) if [arterial phase hypo- or iso-enhancing](#)
    - [< 10mm](#) vs. [10-19mm](#) vs. [≥ 20mm](#) If [arterial phase hyper-enhancing](#)
  - Number of the following features: [“washout”](#), [“capsule”](#), [threshold growth](#)
    - None, one, two or more
- Then select corresponding cell in Table.

Table		Arterial phase hypo- or iso-enhancement		Arterial phase hyper-enhancement		
		< 20	≥ 20	< 10	10-19	≥ 20
Diameter (mm):						
•“Washout” •“Capsule” •Threshold growth	None:	LR3	LR3	LR3	LR3	LR4B
	One:	LR3	LR4B	LR4A	LR4A	LR5B
	≥ Two:	LR4A	LR4B	LR4A	LR5A	LR5B

LR5 Treated



Apply Ancillary Features and then Tie-Breaking Rules to Adjust Category

**Table:**

**Comments:**

Compared to larger masses and masses with [arterial phase hyper-enhancement](#), smaller masses and masses with [arterial phase hypo- or iso-enhancement](#) must satisfy stricter criteria to be assigned an equivalent LR [category](#). Masses with arterial phase hypo- or iso-enhancement cannot be categorized LR5. Masses with [diameter < 10mm](#) cannot be categorized LR5. LR4 and LR5 observations are [designated](#) A ([diameter < 20mm](#)) or B ([diameter ≥ 20 mm](#)).



## Technical Requirements:

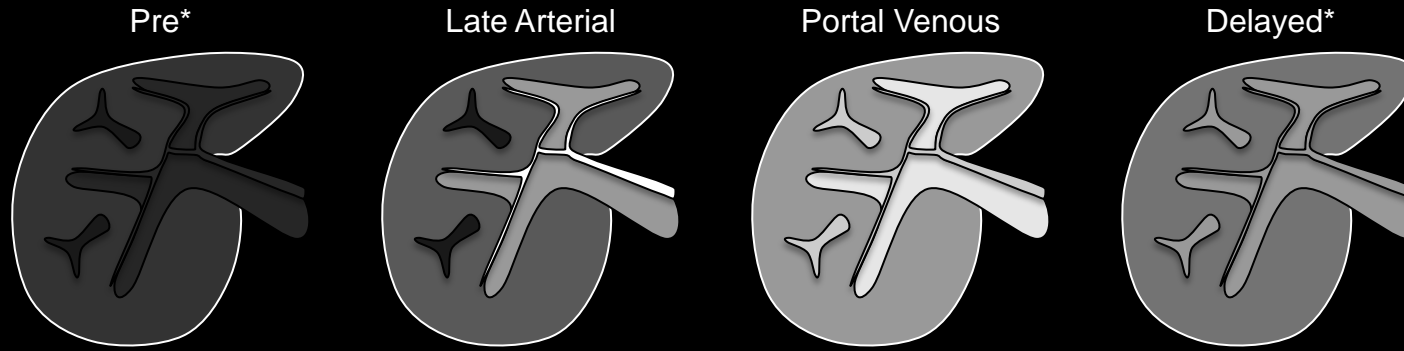
### [LI-RADS Technical Requirements for CT](#)

- [Rationale for LI-RADS Technical Requirements for CT](#)

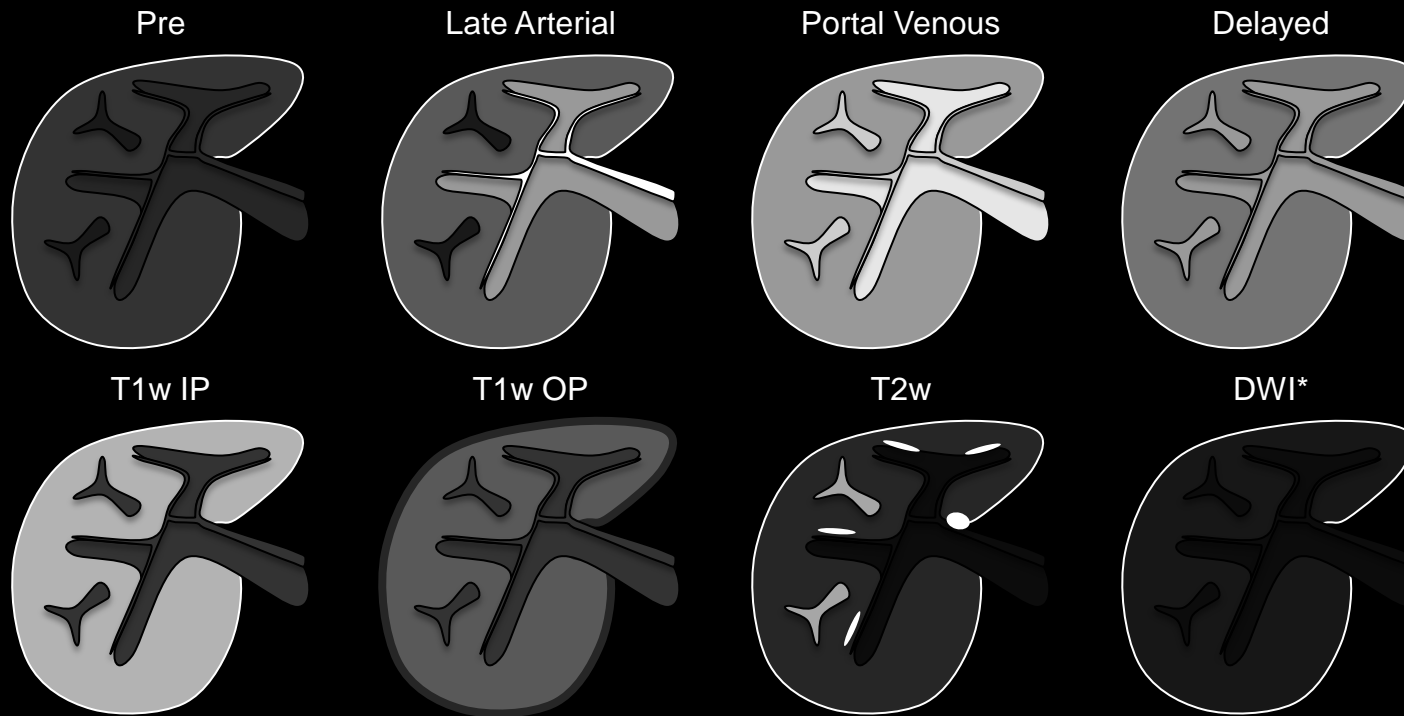
### [LI-RADS Technical Requirements for MRI](#)

- [Rationale for LI-RADS Technical Requirements for MRI](#)

CT



MRI with  
extra-cellular  
agents



**Technique:** Schematic diagrams illustrate optimal technique for CT and MRI with extra-cellular agents for HCC diagnosis and staging. \* = suggested sequences/phases. All other sequences/phases are required.

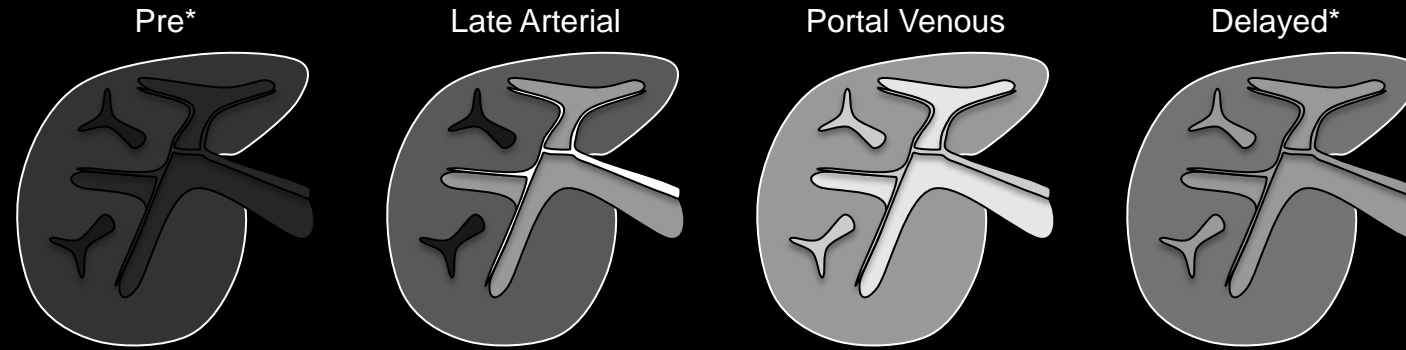


## Technical Requirements:

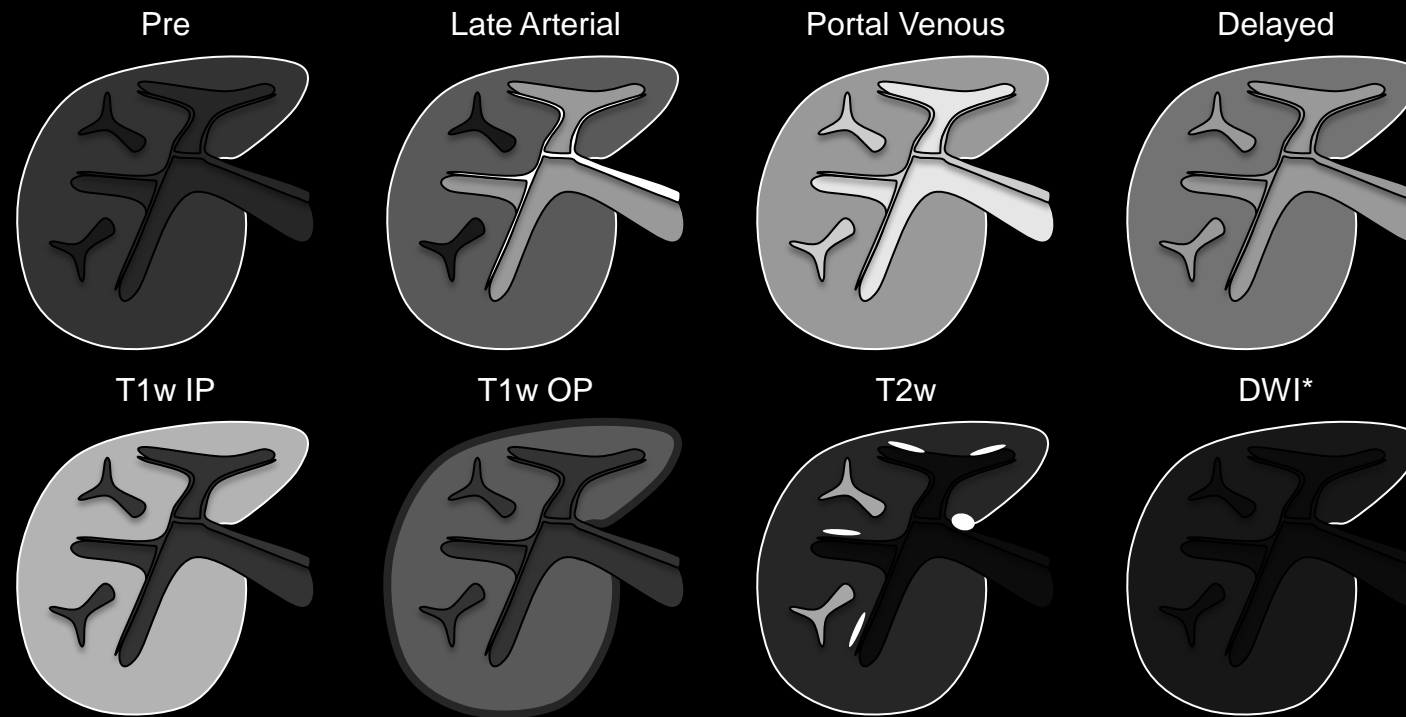
### LI-RADS Technical Requirements for CT:

- [Arterial phase](#) and [portal venous phase](#) imaging are required.
  - [Late arterial phase](#) **strongly** preferred over [early arterial phase](#).
- [Pre-contrast](#) imaging suggested.
- [Delayed phase](#) imaging suggested.
- Multi-planar reformations suggested.
- **Note** – arterial phase, portal venous phase, and delayed phase all are required for CT per OPTN policy 3.6.4.4 to assign HCC exception points. Pre-contrast imaging not required per OPTN policy 3.6.4.4.
- [Rationale for LI-RADS Technical Requirements for CT](#)

CT



MRI with  
extra-cellular  
agents



**Technique:** Schematic diagrams illustrate optimal technique for CT and MRI with extra-cellular agents for HCC diagnosis and staging. \* = suggested sequences/phases. All other sequences/phases are required.



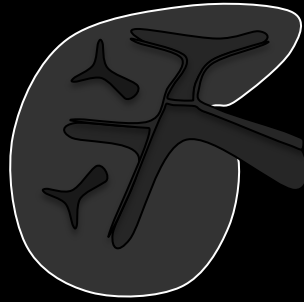
## Technical Requirements:

### • Rationale for LI-RADS Technical Requirements for CT:

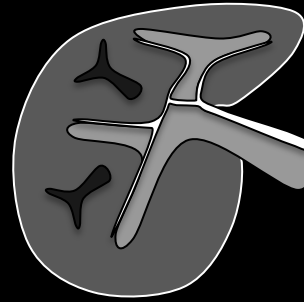
- Arterial phase and portal venous phase generally are the most useful phases for characterization of LI-RADS major features and hence are required.
  - Late arterial phase is **strongly** preferred. HCC enhancement usually is greater in the late than in the early arterial phase. Some HCCs show hyper-enhancement only in the late arterial phase.
- While pre-contrast and delayed phase CT imaging may contribute to LI-RADS categorization, the incremental benefit often is low, and the addition of these images increases radiation exposure. The risk-benefit of pre-contrast and delayed phase CT imaging is not established. Hence, LI-RADS suggests but does not mandate pre-contrast and delayed phase imaging.
- Multi-planar reformations may be helpful to differentiate [mass](#) from non-mass and to identify [capsule appearance](#). They also may be used to measure observation [diameter](#) if they depict observation margins more clearly than axial images.

CT

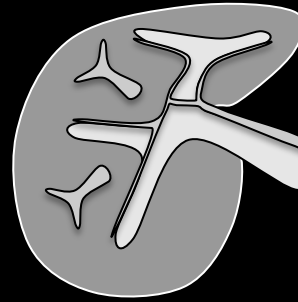
Pre\*



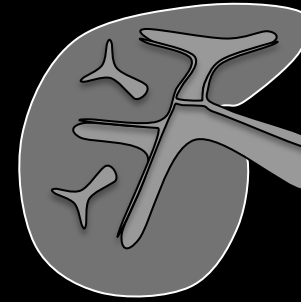
Late Arterial



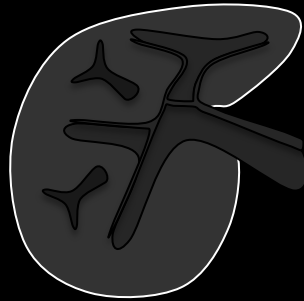
Portal Venous



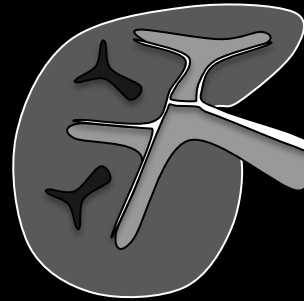
Delayed\*



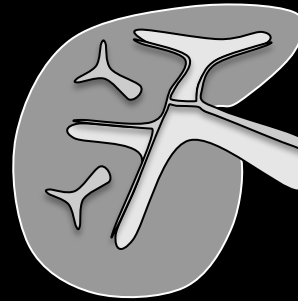
Pre



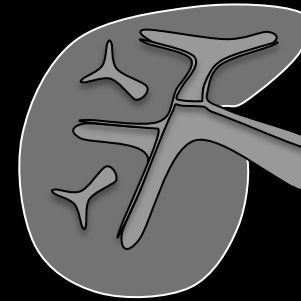
Late Arterial



Portal Venous

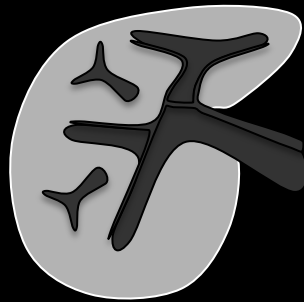


Delayed

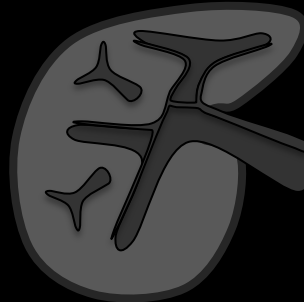


MRI with  
extra-cellular  
agents

T1w IP




T1w OP



T2w



DWI\*



**Technique:** Schematic diagrams illustrate optimal technique for CT and MRI with extra-cellular agents for HCC diagnosis and staging. \* = suggested sequences/phases. All other sequences/phases are required.



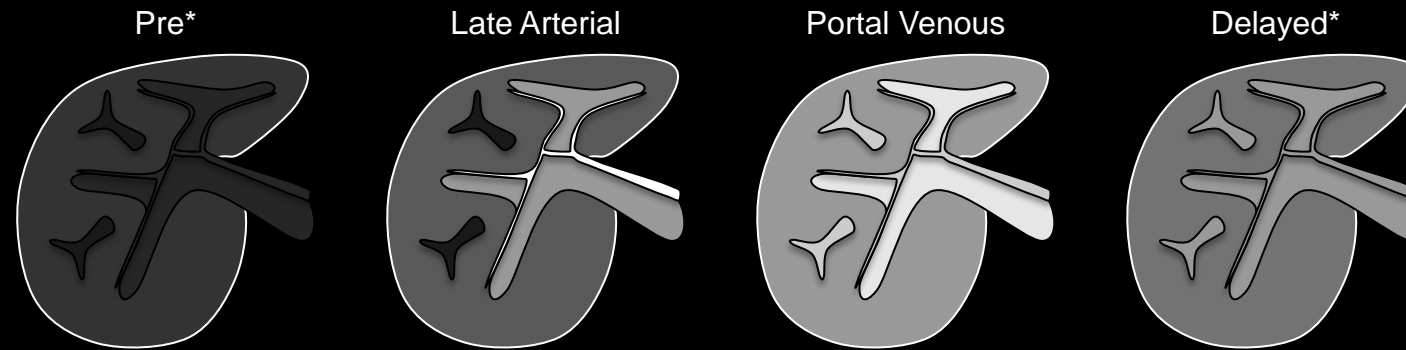


## Technical Requirements:

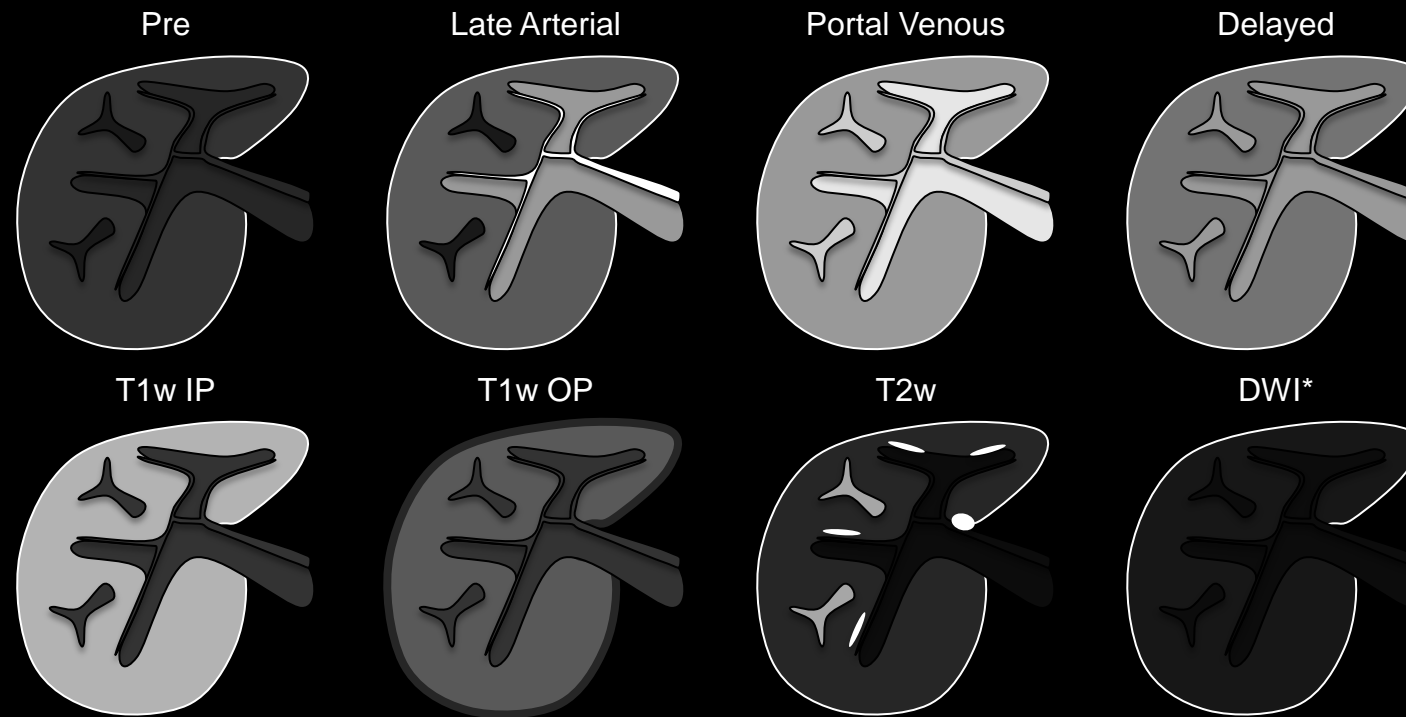
### LI-RADS Technical Requirements For MRI with EC agents and EC agents with modest HC uptake (e.g., gadobenate):

- Pre-contrast, arterial phase, portal venous phase, and delayed phase required.
  - [Late arterial phase](#) **strongly** preferred over [early arterial phase](#).
- Unenhanced T1w OP and IP required.
- T2w FSE or T2w SSFSE required.
- DWI suggested.
- Multi-planar acquisitions or reformations may be helpful.
- Post-processing with generation of subtraction images (arterial phase – pre; arterial phase – portal venous phase or arterial phase – delayed phase) may be helpful in select cases.
- **Note** – pre-contrast, arterial phase, portal venous phase, and delayed phase required for MRI per OPTN policy 3.6.4.4 to assign HCC exception points.
- [Rationale for LI-RADS Technical Requirements for MRI](#)

CT



MRI with extra-cellular agents



**Technique:** Schematic diagrams illustrate optimal technique for CT and MRI with extra-cellular agents for HCC diagnosis and staging. \* = suggested sequences/phases. All other sequences/phases are required.

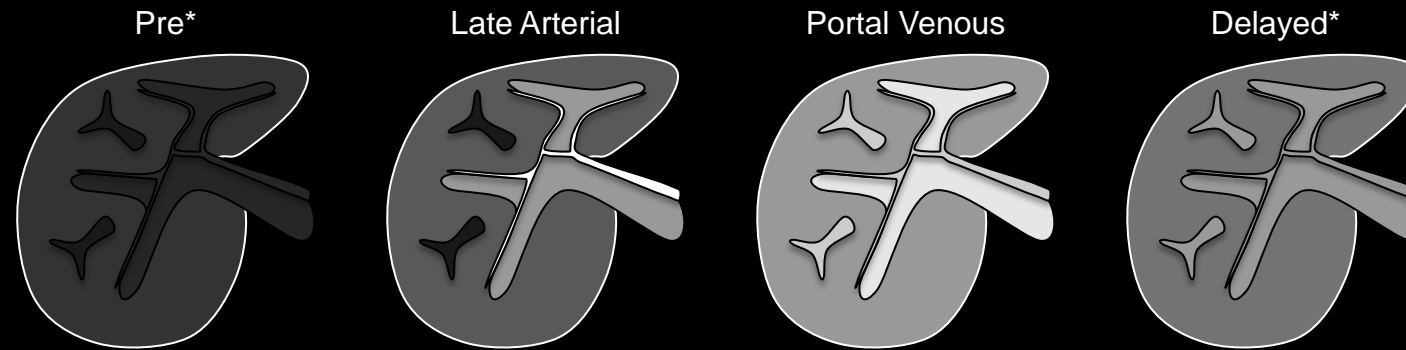


## Technical Requirements:

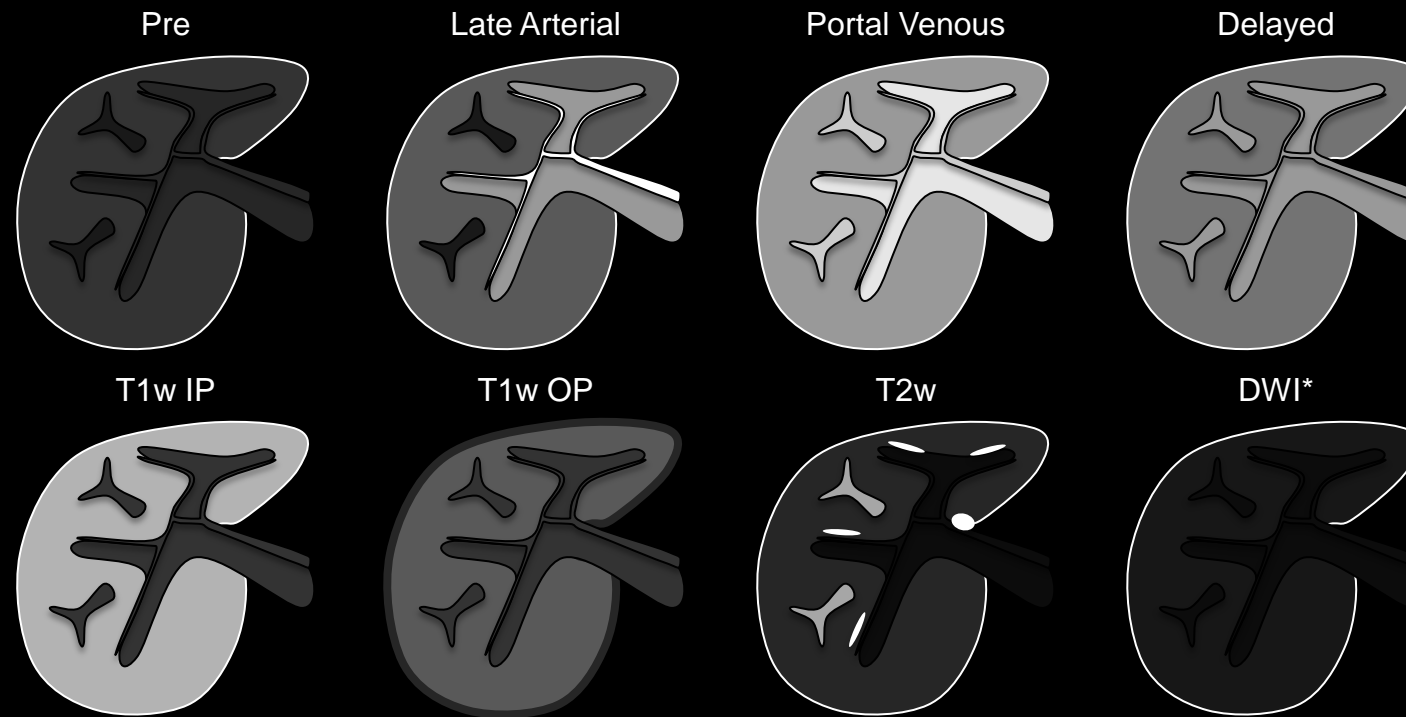
### Rationale for LI-RADS Technical Requirements for MRI:

- Each phase (pre, arterial phase, portal venous phase, and delayed phase) contributes to characterization of LI-RADS major features with little additional examination time and, unlike CT, no additional radiation exposure.
- Late arterial phase is **strongly** preferred. HCC enhancement usually is greater in the late than in the early arterial phase. Some HCCs show hyper-enhancement only in the late arterial phase.
- OP/IP allows identification of fat and iron and is necessary for assessment of some LI-RADS ancillary features.
- If available, acquire using a dual-echo sequence rather than as separate single-echo acquisitions to ensure image co-registration across echoes.
- For dual-echo sequences, OP-then-IP design is preferable to IP-then-OP design because it permits more reliable evaluation of fat and iron.
- T2w improves distinction between solid vs. nonsolid and is necessary for assessment of some ancillary LI-RADS features.

CT



MRI with extra-cellular agents



**Technique:** Schematic diagrams illustrate optimal technique for CT and MRI with extra-cellular agents for HCC diagnosis and staging. \* = suggested sequences/phases. All other sequences/phases are required.

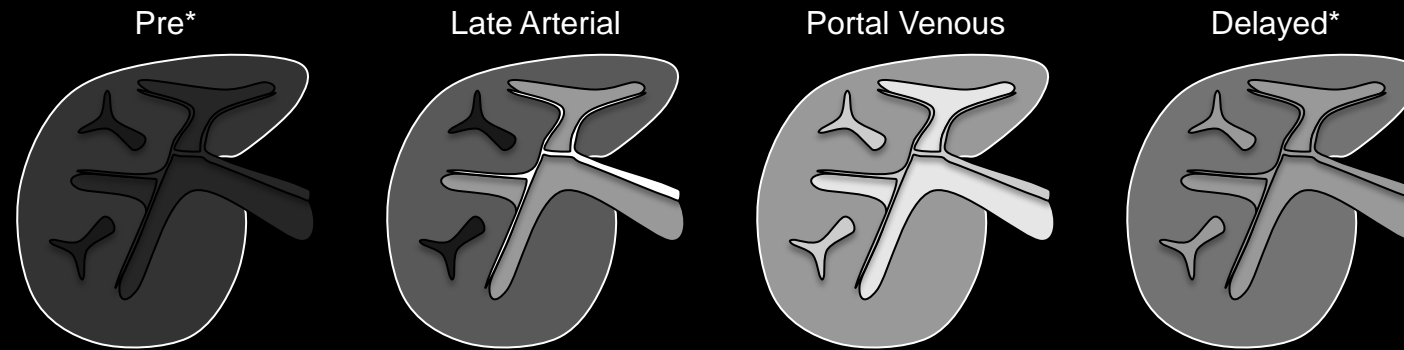


## Technical Requirements:

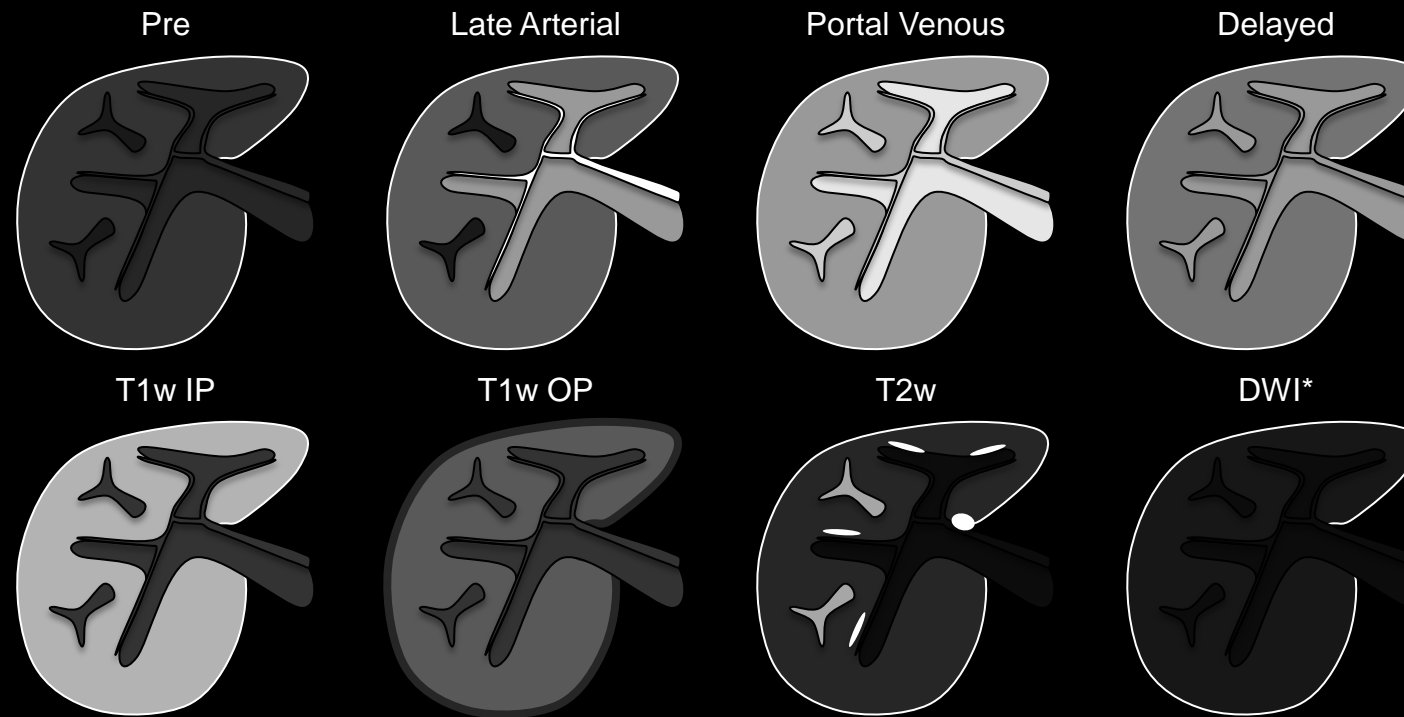
### Rationale for LI-RADS Technical Requirements for MRI (continued):

- DWI may be useful for detection of focal observations and is necessary for assessment of [restricted diffusion](#), but DWI is not as robust or widely available as other MRI sequences. Hence, DWI is suggested but not required.
- Multi-planar acquisitions or reformations may be helpful to differentiate [mass](#) from non-mass and to identify [capsule appearance](#). They also may be used to measure observation [diameter](#) if they depict observation margins more clearly than axial images.
- For observations that are hyper-intense pre-contrast, arterial phase – pre subtraction images may be helpful for evaluation of arterial phase enhancement. Also, for some observations, arterial phase – portal venous phase or arterial phase – delayed phase subtraction images may be helpful for evaluation of “washout”.
- For subtractions to be valid, source images need to be co-registered and acquired with the same technique.

CT



MRI with extra-cellular agents



**Technique:** Schematic diagrams illustrate optimal technique for CT and MRI with extra-cellular agents for HCC diagnosis and staging. \* = suggested sequences/phases. All other sequences/phases are required.

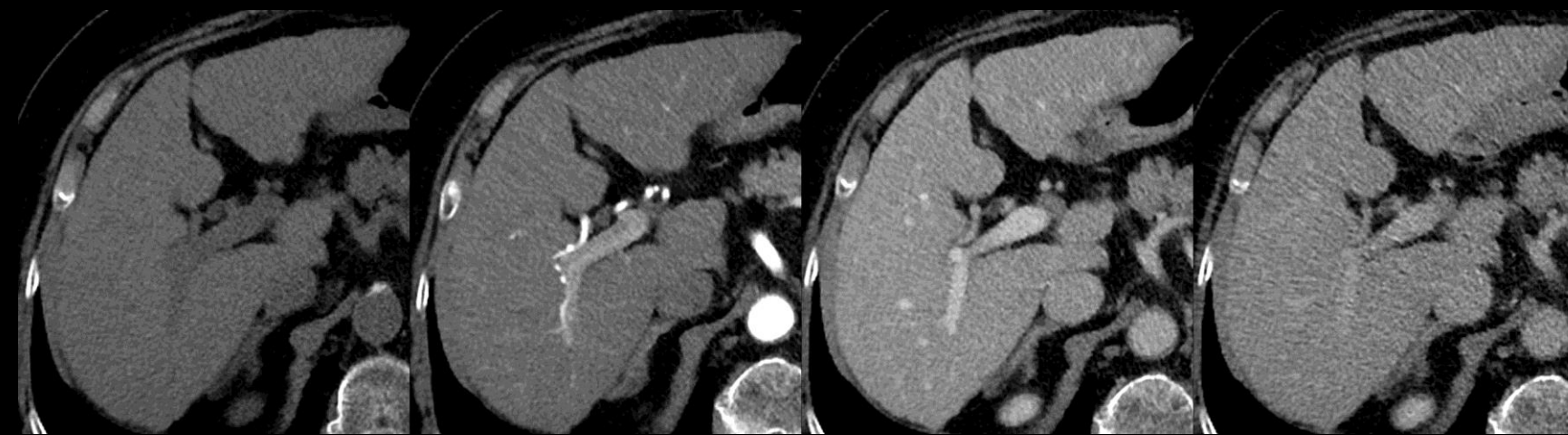

Pre\*

Late Arterial

Portal Venous

Delayed\*

**Technical Requirements:****LI-RADS Technical Requirements for CT:**

- [Arterial phase](#) and [portal venous phase](#) imaging are required.
  - [Late arterial phase](#) **strongly** preferred over [early arterial phase](#).
- [Pre-contrast](#) imaging suggested.
- [Delayed phase](#) imaging suggested.
- Multi-planar reformations suggested.
- **Note** – arterial phase, portal venous phase, and delayed phase all are required for CT per OPTN policy 3.6.4.4 to assign HCC exception points. Pre-contrast imaging not required per OPTN policy 3.6.4.4.
- [Rationale for LI-RADS Technical Requirements for CT](#)

**Technique (CT):** Arterial phase and portal venous phase images are required; late arterial phase is **strongly** preferred over early arterial phase. \*Pre-contrast and delayed phase images are suggested.



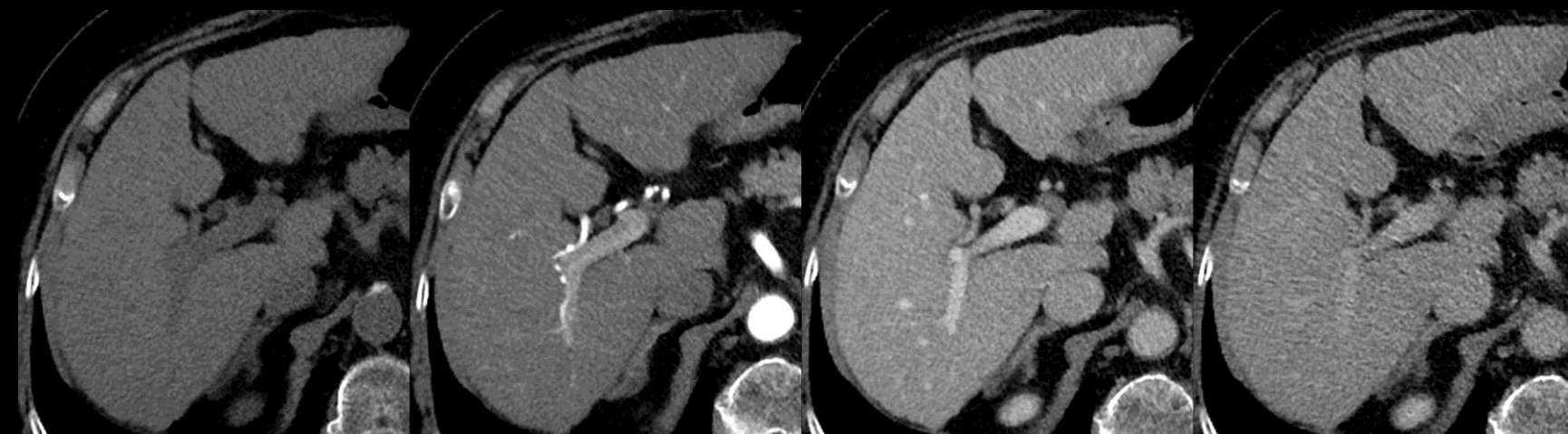

Pre\*

Late Arterial

Portal Venous

Delayed\*

**Technical Requirements:****• Rationale for LI-RADS Technical Requirements for CT:**

- Arterial phase and portal venous phase generally are the most useful phases for characterization of LI-RADS major features and hence are required.
  - Late arterial phase is **strongly** preferred. HCC enhancement usually is greater in the late than in the early arterial phase. Some HCCs show hyper-enhancement only in the late arterial phase.
- While pre-contrast and delayed phase CT imaging may contribute to LI-RADS categorization, the incremental benefit often is low, and the addition of these images increases radiation exposure. The risk-benefit of pre-contrast and delayed phase CT imaging is not established. Hence, LI-RADS suggests but does not mandate pre-contrast and delayed phase imaging.
- Multi-planar reformations may be helpful to differentiate [mass](#) from non-mass and to identify [capsule appearance](#). They also may be used to measure observation [diameter](#) if they depict observation margins more clearly than axial images.

**Technique (CT):** Arterial phase and portal venous phase images are required; late arterial phase is **strongly** preferred over early arterial phase. \*Pre-contrast and delayed phase images are suggested.





## Technical Requirements:

### LI-RADS Technical Requirements For MRI with EC agents and EC agents with modest HC uptake (e.g., gadobenate):

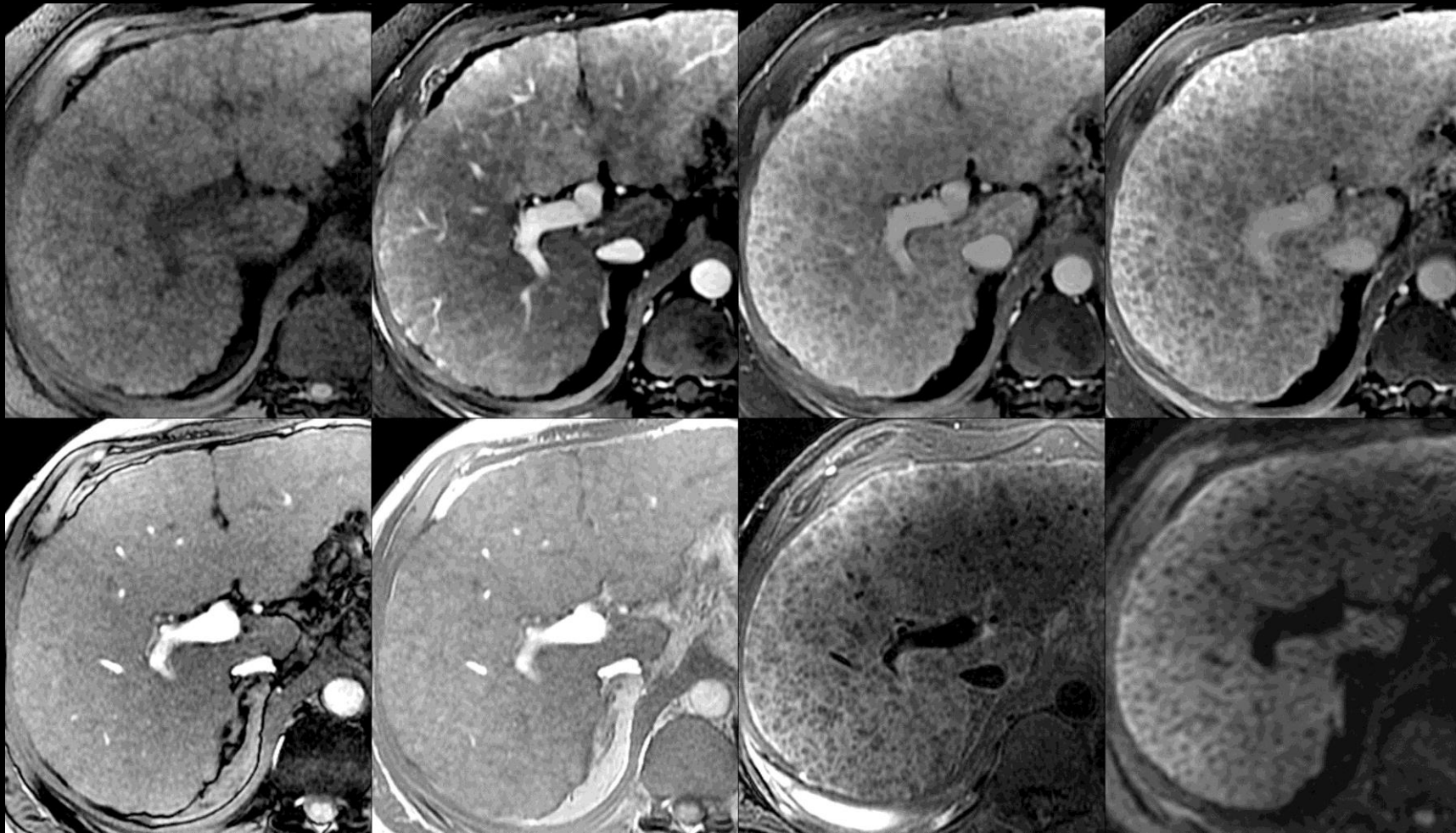
- Pre-contrast, arterial phase, portal venous phase, and delayed phase required.
  - [Late arterial phase](#) **strongly** preferred over [early arterial phase](#).
- Unenhanced T1w OP and IP required.
- T2w FSE or T2w SSFSE required.
- DWI suggested.
- Multi-planar acquisitions or reformations may be helpful.
- Post-processing with generation of subtraction images (arterial phase – pre; arterial phase – portal venous phase or arterial phase – delayed phase) may be helpful in select cases.
- **Note** – pre-contrast, arterial phase, portal venous phase, and delayed phase required for MRI per OPTN policy 3.6.4.4 to assign HCC exception points.
- [Rationale for LI-RADS Technical Requirements for MRI](#)

Pre

Late Arterial

Portal Venous

Delayed



T1w OP

T1w IP

T2w FSE

DW\*

**Technique (MRI):** Pre-contrast, late arterial phase, portal venous, 3-5-minute delayed phase, T1w OP, T1w IP, and T2w fast spin echo (FSE) or T2w single shot fast spin echo images are required. \*Diffusion-weighted (DW) images are suggested.





### Technical Requirements:

#### • Rationale for LI-RADS Technical Requirements for MRI:

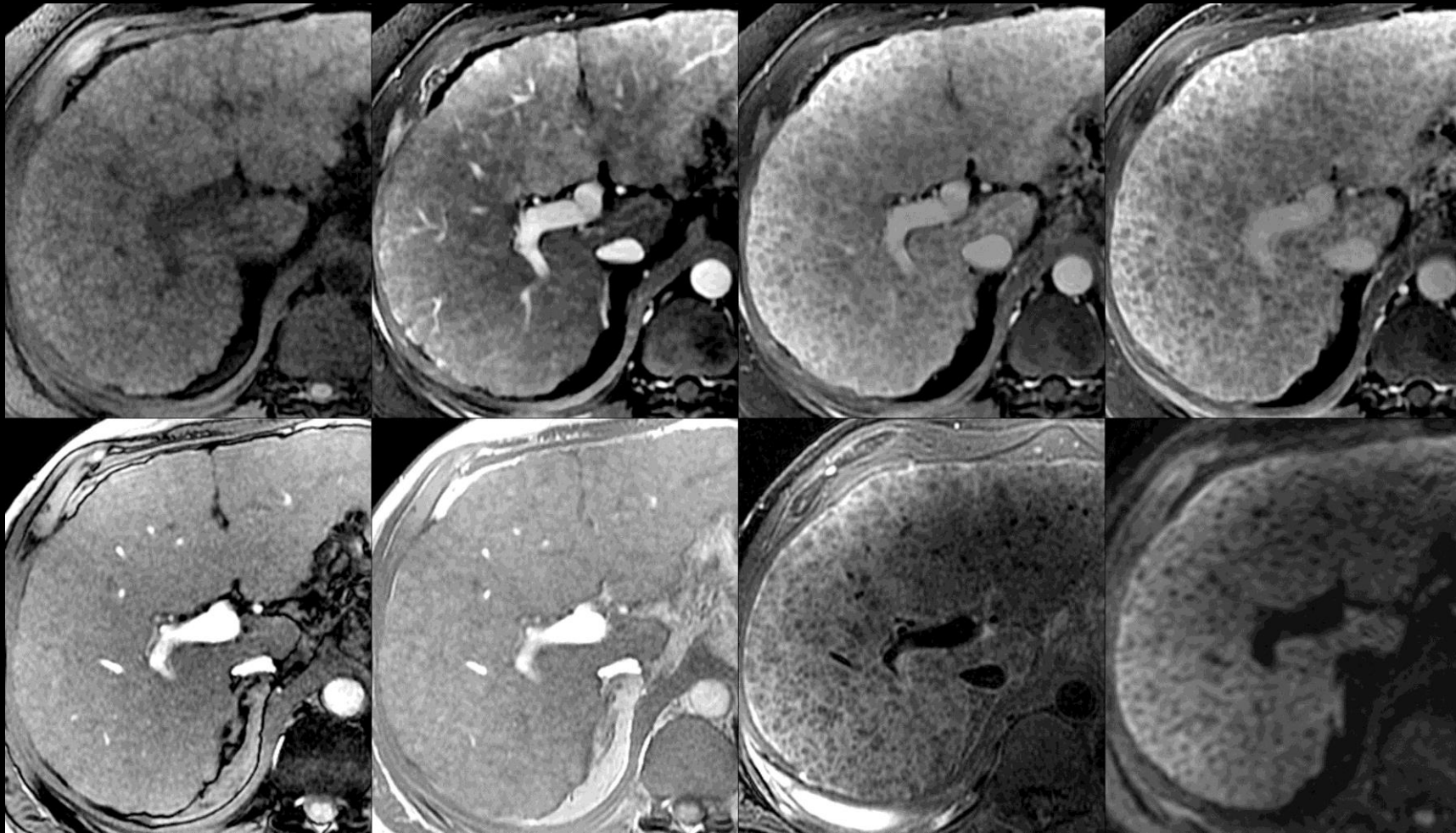
- Each phase (pre, arterial phase, portal venous phase, and delayed phase) contributes to characterization of LI-RADS major features with little additional examination time and, unlike CT, no additional radiation exposure.
- Late arterial phase is **strongly** preferred. HCC enhancement usually is greater in the late than in the early arterial phase. Some HCCs show hyper-enhancement only in the late arterial phase.
- OP/IP allows identification of fat and iron and is necessary for assessment of some LI-RADS ancillary features.
  - If available, acquire using a dual-echo sequence rather than as separate single-echo acquisitions to ensure image co-registration across echoes.
  - For dual-echo sequences, OP-then-IP design is preferable to IP-then-OP design because it permits more reliable evaluation of fat and iron.
- T2w improves distinction between solid vs. nonsolid and is necessary for assessment of some ancillary LI-RADS features.

Pre

Late Arterial

Portal Venous

Delayed



T1w OP

T1w IP

T2w FSE

DW\*

**Technique (MRI):** Pre-contrast, late arterial phase, portal venous, 3-5-minute delayed phase, T1w OP, T1w IP, and T2w fast spin echo (FSE) or T2w single shot fast spin echo images are required. \*Diffusion-weighted (DW) images are suggested.





### Technical Requirements:

#### • Rationale for LI-RADS Technical Requirements for MRI (continued):

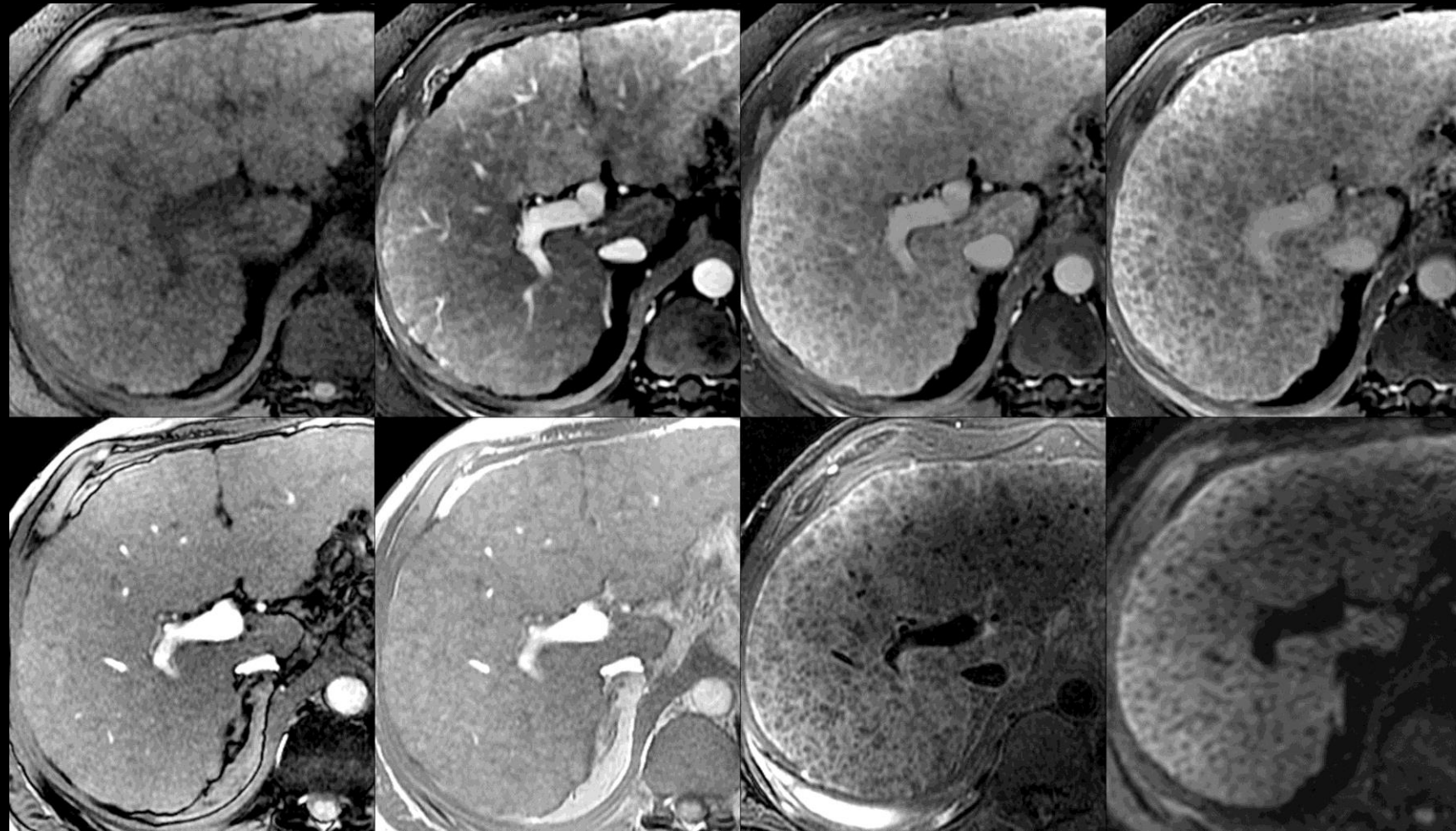
- DWI may be useful for detection of focal observations and is necessary for assessment of [restricted diffusion](#), but DWI is not as robust or widely available as other MRI sequences. Hence, DWI is suggested but not required.
- Multi-planar acquisitions or reformations may be helpful to differentiate [mass](#) from non-mass and to identify [capsule appearance](#). They also may be used to measure observation [diameter](#) if they depict observation margins more clearly than axial images.
- For observations that are hyper-intense pre-contrast, arterial phase – pre subtraction images may be helpful for evaluation of arterial phase enhancement. Also, for some observations, arterial phase – portal venous phase or arterial phase – delayed phase subtraction images may be helpful for evaluation of “washout”.
- For subtractions to be valid, source images need to be co-registered and acquired with the same technique.

Pre

Late Arterial

Portal Venous

Delayed



T1w OP

T1w IP

T2w FSE

DW\*

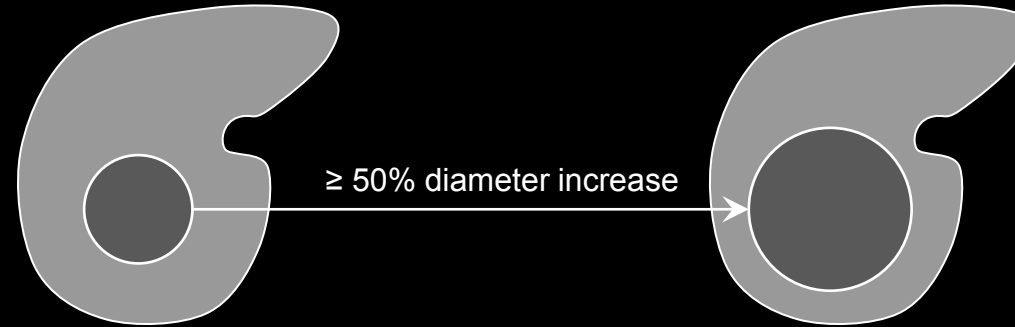
**Technique (MRI):** Pre-contrast, late arterial phase, portal venous, 3-5-minute delayed phase, T1w OP, T1w IP, and T2w fast spin echo (FSE) or T2w single shot fast spin echo images are required. \*Diffusion-weighted (DW) images are suggested.



Prior (Comparison) Exam

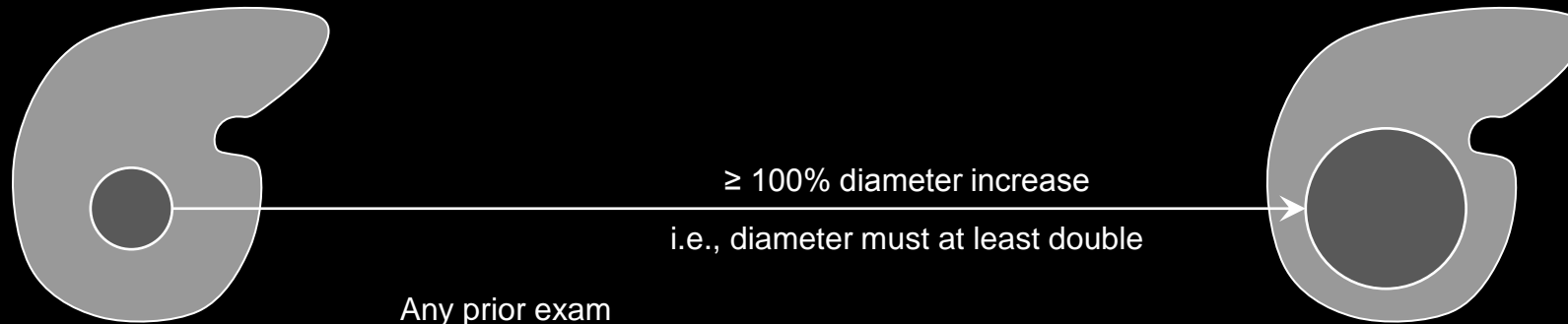
Current Exam

≤ 6 months earlier



≥ 50% diameter increase

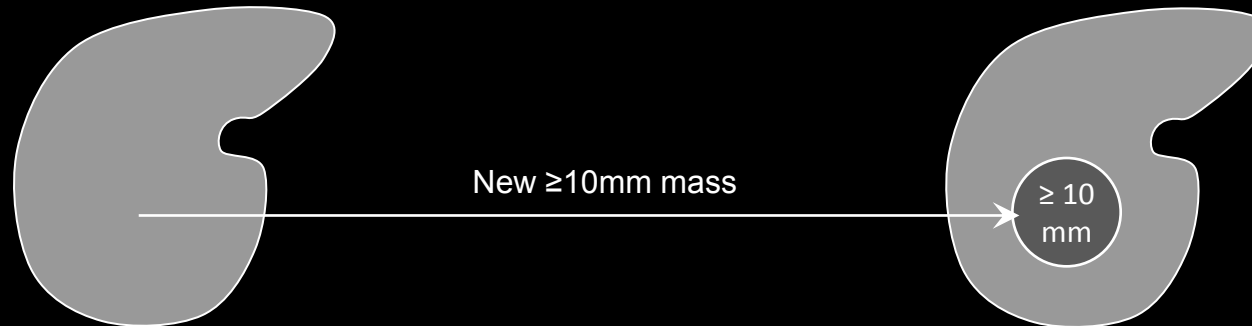
> 6 months earlier



≥ 100% diameter increase

i.e., diameter must at least double

Any prior exam



New ≥ 10mm mass

≥ 10 mm

## Threshold Growth:

[Diameter increase](#) of a [mass](#) by a minimum of 5mm AND, depending on the time interval between examinations, by the following amounts:

<u>Time interval</u>	<u>Diameter increase</u>
≤ 6 months	≥ 50%
> 6 months	≥ 100%

A new ≥10mm mass also represents threshold growth, regardless of the time interval. A new <10mm mass does not represent threshold growth.

## Comments:

- Threshold growth applies to masses; it does not apply to observations that are not masses (e.g., [perfusion alterations](#), [hepatic fat deposition](#)).
- Threshold growth is a LI-RADS [major feature](#) used to categorize masses that are neither [definite benign entities](#) nor [probable benign entities](#) and that lack features of [non-HCC malignancy](#) or [tumor in vein](#). For such masses, those with threshold growth may be categorized LR3, LR4, or LR5, depending on the observation's arterial phase enhancement, diameter, and other features. As shown in [Table](#), masses with threshold growth but without arterial phase hyper-enhancement cannot be categorized LR5.
- Threshold growth should be assessed on images in the same plane and, if possible, acquired in the same phase or sequence.

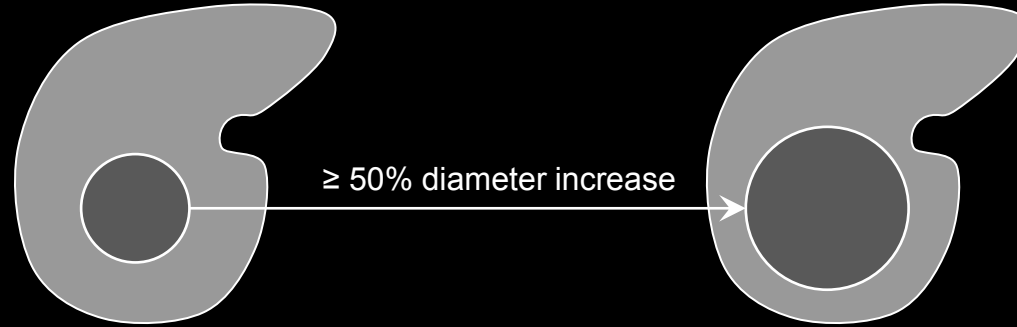
**Growth:** Schematic diagrams depict the increases in diameter that define threshold growth, depending on whether the prior examination was performed ≤ 6 months earlier (top row) or > 6 months earlier (bottom row). A new ≥10mm mass also represents threshold growth.



Prior (Comparison) Exam

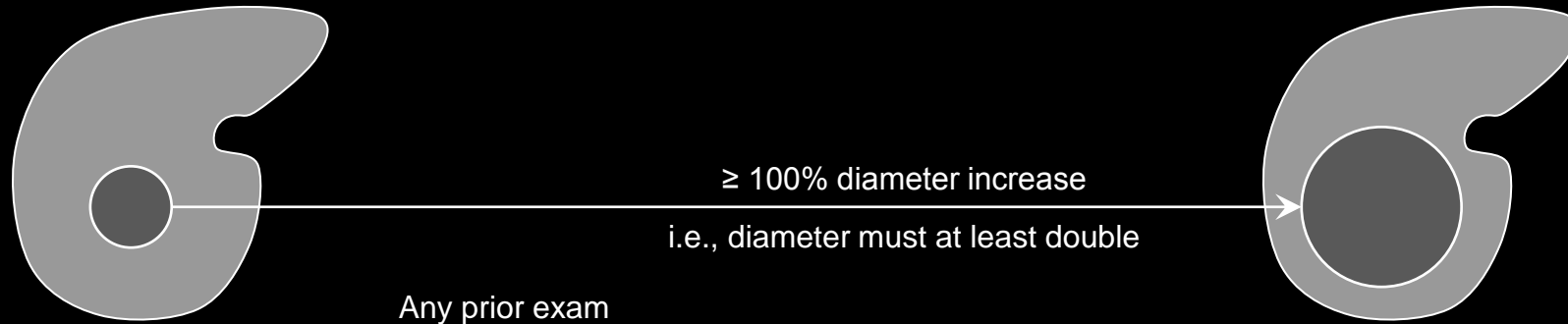
Current Exam

≤ 6 months earlier



≥ 50% diameter increase

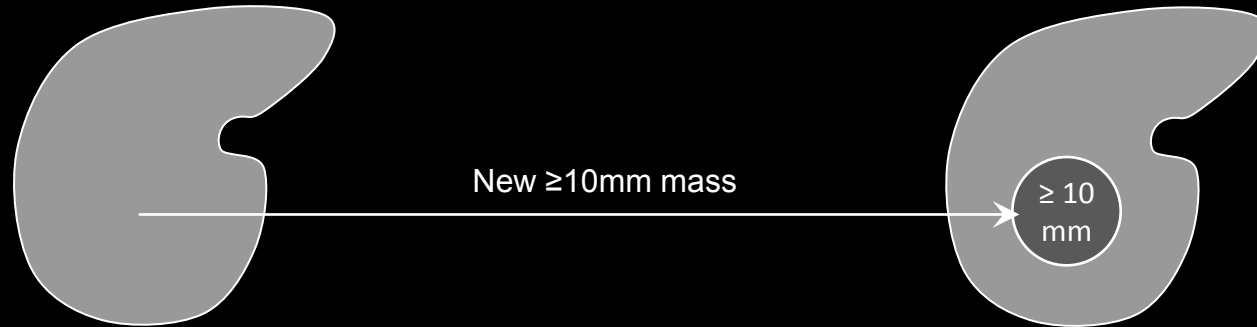
> 6 months earlier



≥ 100% diameter increase

i.e., diameter must at least double

Any prior exam



New ≥ 10mm mass

≥ 10 mm

## Threshold Growth:

### Comments (continued):

- Note that OPTN recognizes threshold growth only as ≥ 50% increase in diameter in ≤ 6 months.

**Growth:** Schematic diagrams depict the increases in diameter that define threshold growth, depending on whether the prior examination was performed ≤ 6 months earlier (top row) or > 6 months earlier (bottom row). A new ≥ 10mm mass also represents threshold growth.

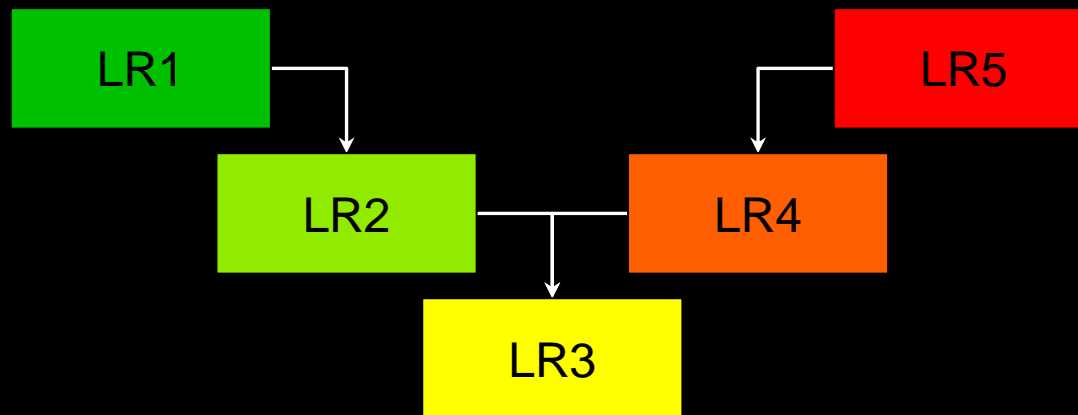


**Tie-Breaking Rules:**

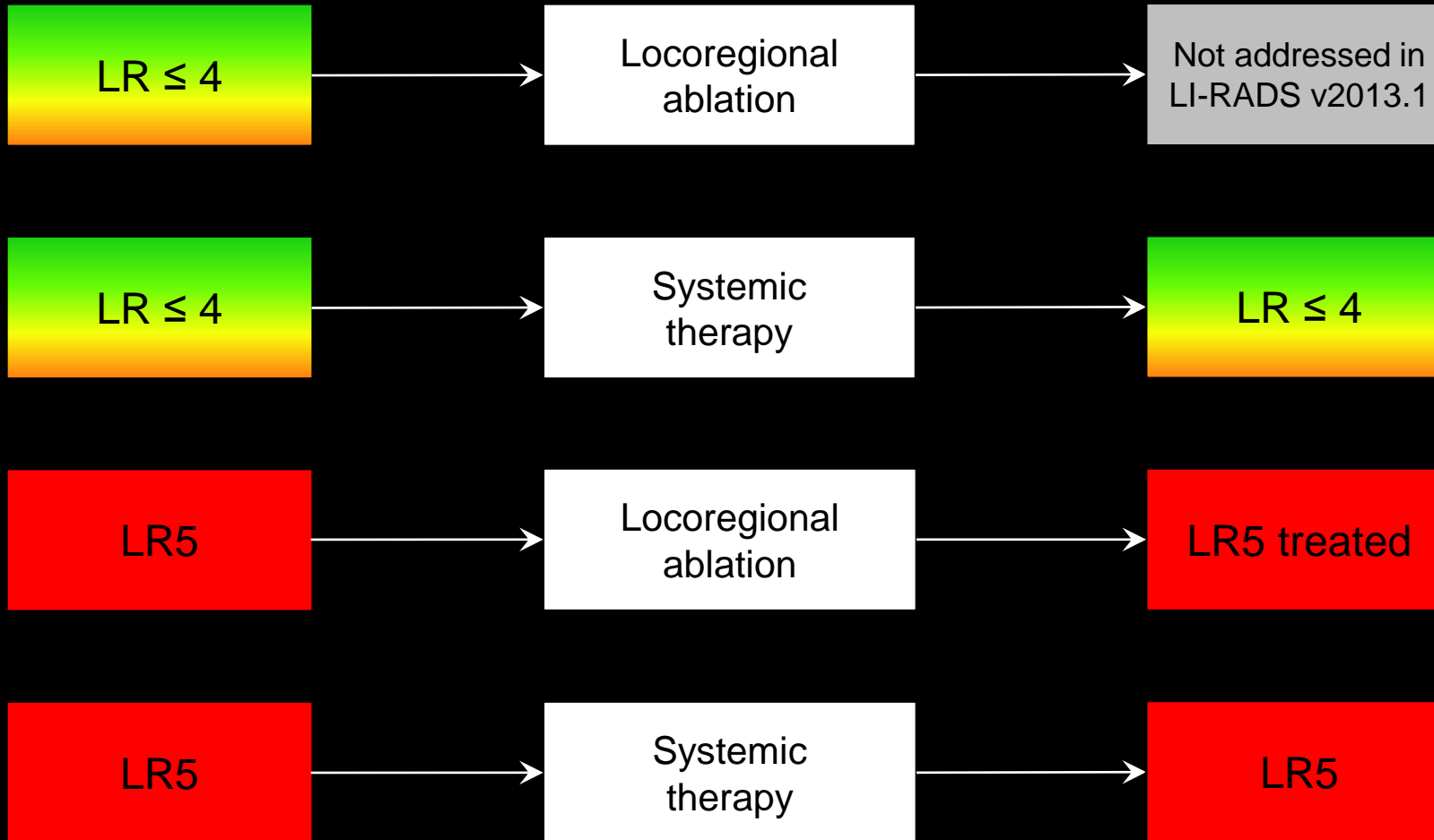
Rules to assign a final category when observation has features which place it between two categories.

**Comments:**

- If unsure about final category after application of ancillary features, apply tie-breaking rules according to schematic on left.
- Review when to apply tie-breaking rules to [adjust LI-RADS category](#).



**Tie-breaking rules:** Schematic diagram illustrates application of tie-breaking rules to adjust category. If, after application of ancillary features, a radiologist is still unsure about the final category for an observation, tie-breaking rules should be applied. The tie-breaking rules move observations to a category with a lower degree of certainty of benignity or HCC.



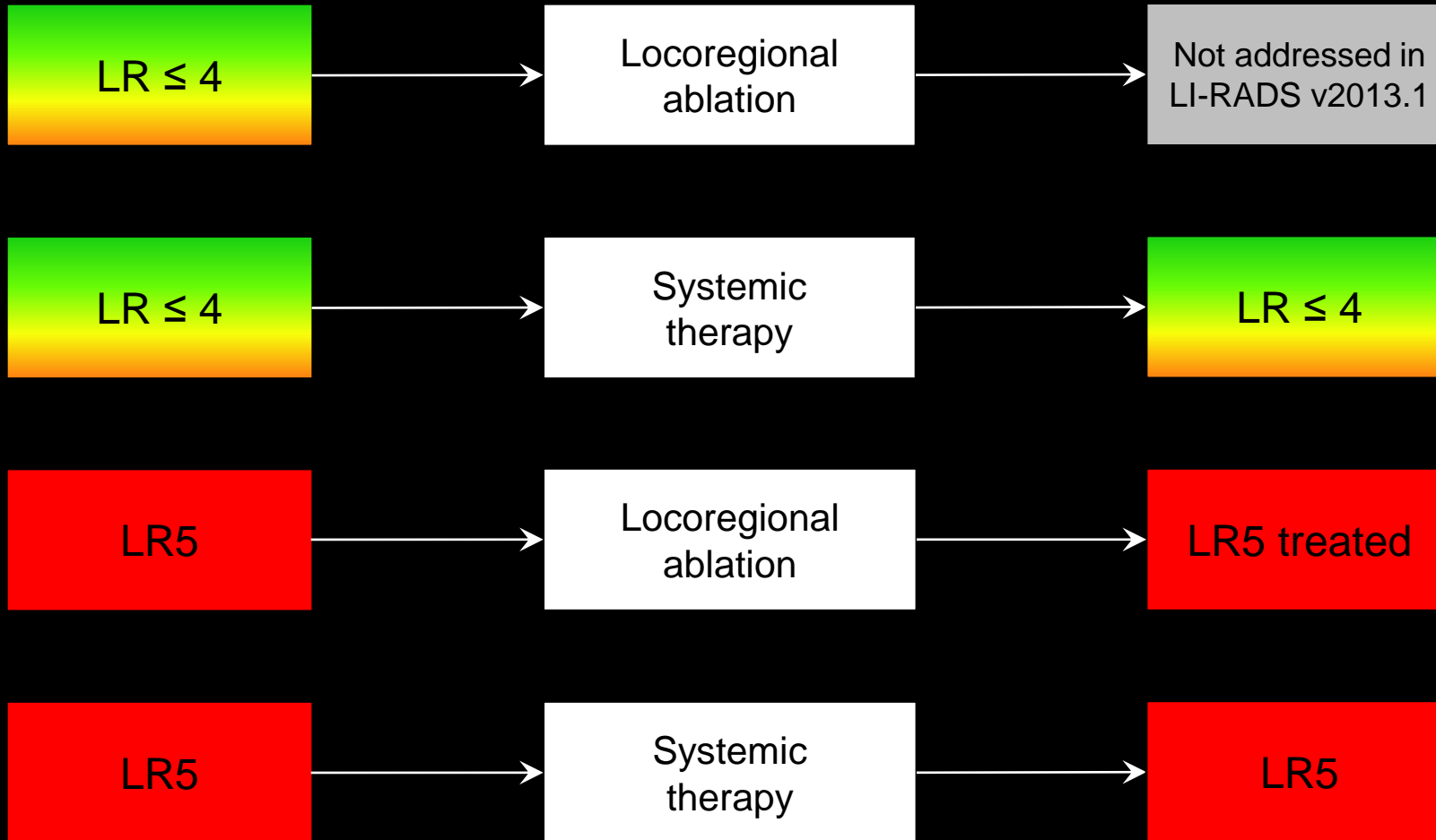
**LI-RADS Categorization of treated observations:** To maintain congruency with OPTN classification system, LR5 observations that have undergone locoregional ablation are categorized LR5 Treated. Observations undergoing systemic therapy without locoregional ablation should be assigned their pre-treatment category. The categorization of LR≤4 observations that have undergone locoregional ablation is not addressed in LI-RADS v2013.1.

## Treatment:

Intervention with the intent to slow the growth, cause necrosis, or resect from the liver an HCC.

## LI-RADS Categorization:

- LR5 observations and biopsy-proven HCC lesions treated by locoregional ablation (i.e., ablated or located within a region of the liver that was embolized) should be designated [LR5 Treated](#), regardless of whether treatment was successful.
- To maintain congruency between LI-RADS and OPTN classification, the following types of observations should not be designated LR5 Treated:
  - LR≤4 observations that have undergone locoregional ablation.
  - LR5 observations and biopsy-proven HCCs treated only with systemic therapies.
  - LR5 observations and biopsy-proven HCCs that have been resected.
  - LR5 observations and biopsy-proven HCCs located outside the ablation zone or embolization field.
- Observations undergoing systemic therapy should be assigned their pre-treatment LI-RADS category regardless of treatment-related changes in imaging features; the pre-treatment LI-RADS category should not be downgraded.



## Treatment:

### Comments:

- Examples of treatment include loco-regional ablation, surgical resection, and systemic chemotherapy.
- Examples of loco-regional ablation include transhepatic arterial chemo-embolization or ablation (e.g., radio-frequency ablation, cryoablation).
- As stated previously, to maintain congruency with OPTN, only LR5 observations treated by loco-regional ablation are designated LR5 Treated.

**LI-RADS Categorization of treated observations:** To maintain congruency with OPTN classification system, LR5 observations that have undergone locoregional ablation are categorized LR5 Treated. Observations undergoing systemic therapy without locoregional ablation should be assigned their pre-treatment category. The categorization of LR≤4 observations that have undergone locoregional ablation is not addressed in LI-RADS v2013.1.

**True tumor capsule:**

Rim of relatively pure fibrous tissue (composed predominantly of collagen) around a tumor.

**Comments:**

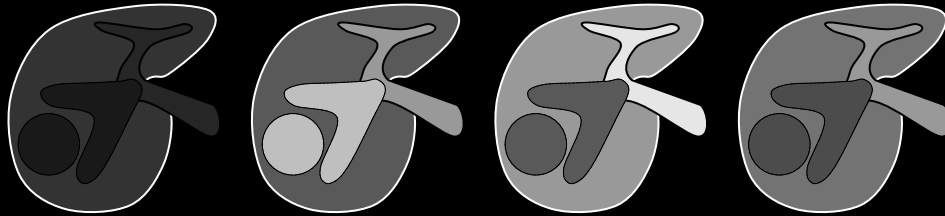
- The relatively pure fibrous tissue in a tumor capsule is distinct from the mixed fibrous tissue (containing bile ducts, blood vessels, and inflammatory cells in addition to collagen) around background cirrhotic nodules. This mixed fibrous tissue represents condensation of cirrhotic scarring.
- A rim of [increasing enhancement](#) in the portal venous phase or delayed phase around a mass at imaging is termed [capsule appearance](#) (synonym: portal venous/delayed phase peripheral rim enhancement).
- Capsule appearance may represent a true tumor capsule or a [pseudocapsule](#).
  - Imaging does not reliably differentiate between a true tumor capsule and a pseudocapsule.
  - The distinction between a true tumor capsule and pseudocapsule can only be made at pathology.
- In at-risk patients, capsule appearance has high positive predictive value for HCC, regardless of whether rim of enhancement represents a true tumor capsule or a pseudocapsule.

**Atlas:** CT, MR, histology

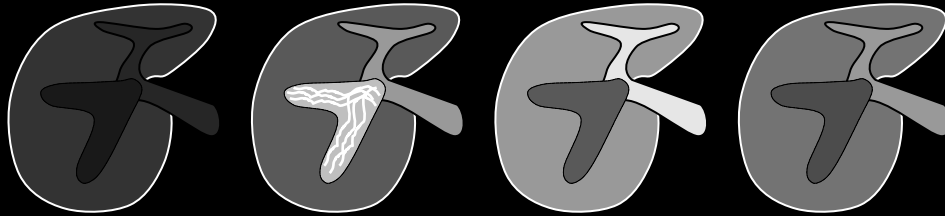


Pre      Arterial      Portal Venous      Delayed

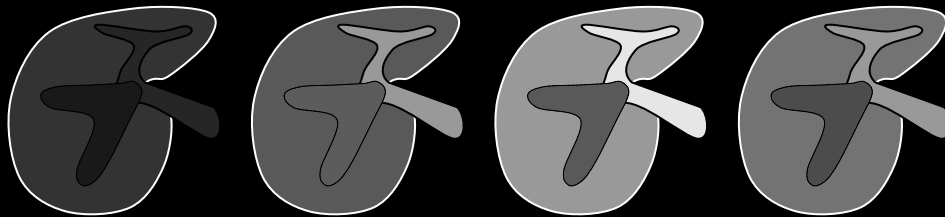
Tumor in vein



Arterial phase hyper-enhancing tumor in vein with associated parenchymal mass.




Arterial phase hyper-enhancing tumor in vein without associated parenchymal mass. Notice arterial phase hyper-enhancing streaks.



Arterial phase hypo- or iso-enhancing tumor in vein without associated parenchymal mass.

Not tumor in vein



Non-tumoral bland thrombus.

**Tumor in vein:** Schematic diagrams illustrate enhancing soft tissue in vein (top three rows), consistent with LR5V. The soft tissue characteristically expands the involved vein lumen. The soft tissue may (top two rows) or may not (third row) show arterial phase hyper-enhancement. Hyper-enhancing linear streaks may be present (“thread-and-streak” sign, second row). Compared to patent portal vein, tumor in vein usually is hypo-enhanced in portal venous and delayed phase. A parenchymal mass may (top row) or may not (second and third rows) be demonstrated. Non-tumoral bland thrombus does not enhance and usually does not expand lumen (bottom row).

## Tumor in vein:

Presence of tumor in vein lumen.

### If unsure about tumor in vein:

- Characterize as no tumor in vein.

### Criterion:

- [Definite](#) enhancing soft tissue in vein.

### Comments:

- Observations with tumor in vein are categorized [LR5V](#).
- The term tumor in vein is preferred over the term tumor thrombus.
  - **Rationale:** the pathological spectrum ranges from thrombus with scant tumor cells to solid tumor with scant thrombus.
- Parenchymal mass may or may not be demonstrated at imaging.
- While not diagnostic of tumor in vein, features that may alert radiologist to diagnosis include:
  - Occluded vein with any of the following: moderately to markedly expanded lumen, ill-defined walls, [restricted diffusion](#), or contiguity with LR5 observation
  - Obscured, partially visualized vein
  - Heterogeneous enhancement of vein not attributable to mixing artifact





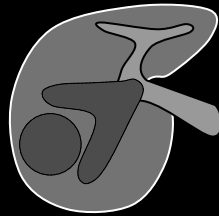
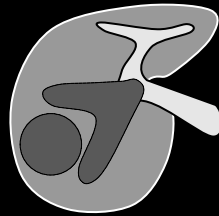
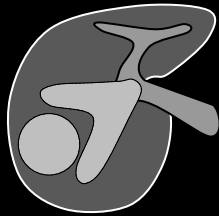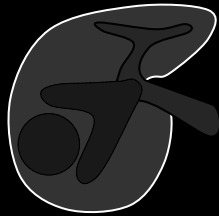Pre

Arterial

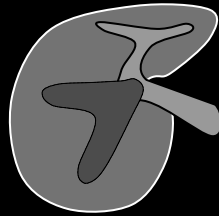
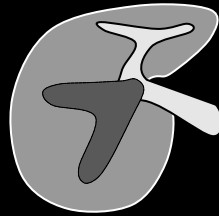
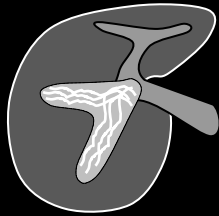
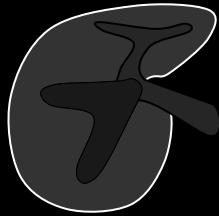
Portal Venous

Delayed

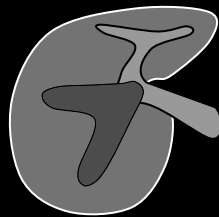
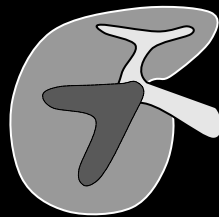
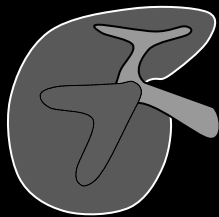
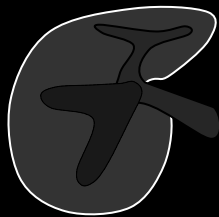Tumor  
in vein



Arterial phase hyper-enhancing tumor in vein with associated parenchymal mass.

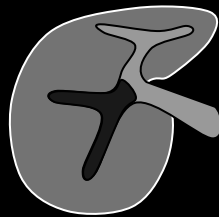
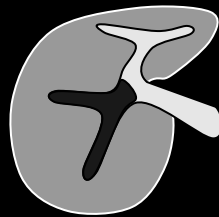
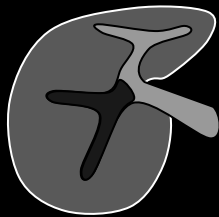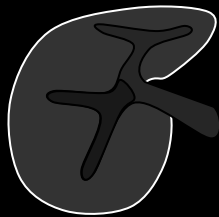Arterial phase hyper-enhancing tumor in vein without associated parenchymal mass. Notice arterial phase hyper-enhancing streaks.



Arterial phase hypo- or iso-enhancing tumor in vein without associated parenchymal mass.

Not  
tumor  
in vein



Non-tumoral bland thrombus.

**Tumor in vein:** Schematic diagrams illustrate enhancing soft tissue in vein (top three rows), consistent with LR5V. The soft tissue characteristically expands the involved vein lumen. The soft tissue may (top two rows) or may not (third row) show arterial phase hyper-enhancement. Hyper-enhancing linear streaks may be present (“thread-and-streak” sign, second row). Compared to patent portal vein, tumor in vein usually is hypo-enhanced in portal venous and delayed phase. A parenchymal mass may (top row) or may not (second and third rows) be demonstrated. Non-tumoral bland thrombus does not enhance and usually does not expand lumen (bottom row).

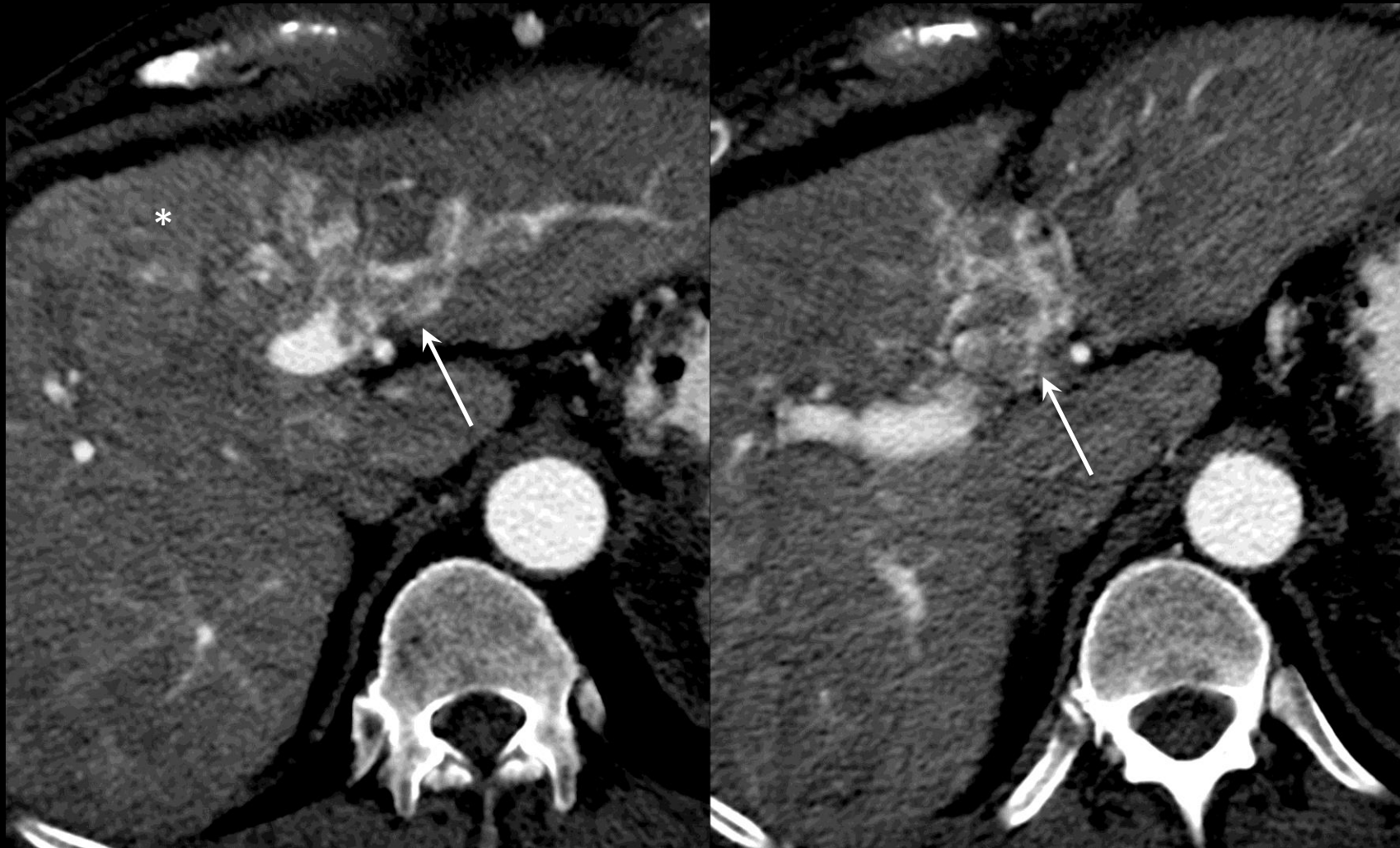Tumor in vein:

**Comments (continued):**

- By comparison, non-tumoral bland thrombus does not enhance and usually does not expand lumen to same degree as tumor in vein.



Arterial phase – Two slices through level of left portal vein



**Tumor in vein (CT):** Arterial phase axial CT images show enhancing soft tissue in left portal vein. There is mild expansion of the portal vein lumen with hyper-enhancing linear streaks, consistent with tumor in vein. As illustrated in this example, a parenchymal component (\*) may be difficult to visualize.

### Tumor in vein:

Presence of tumor in vein lumen.

### If unsure about tumor in vein:

- Characterize as no tumor in vein.

### Criterion:

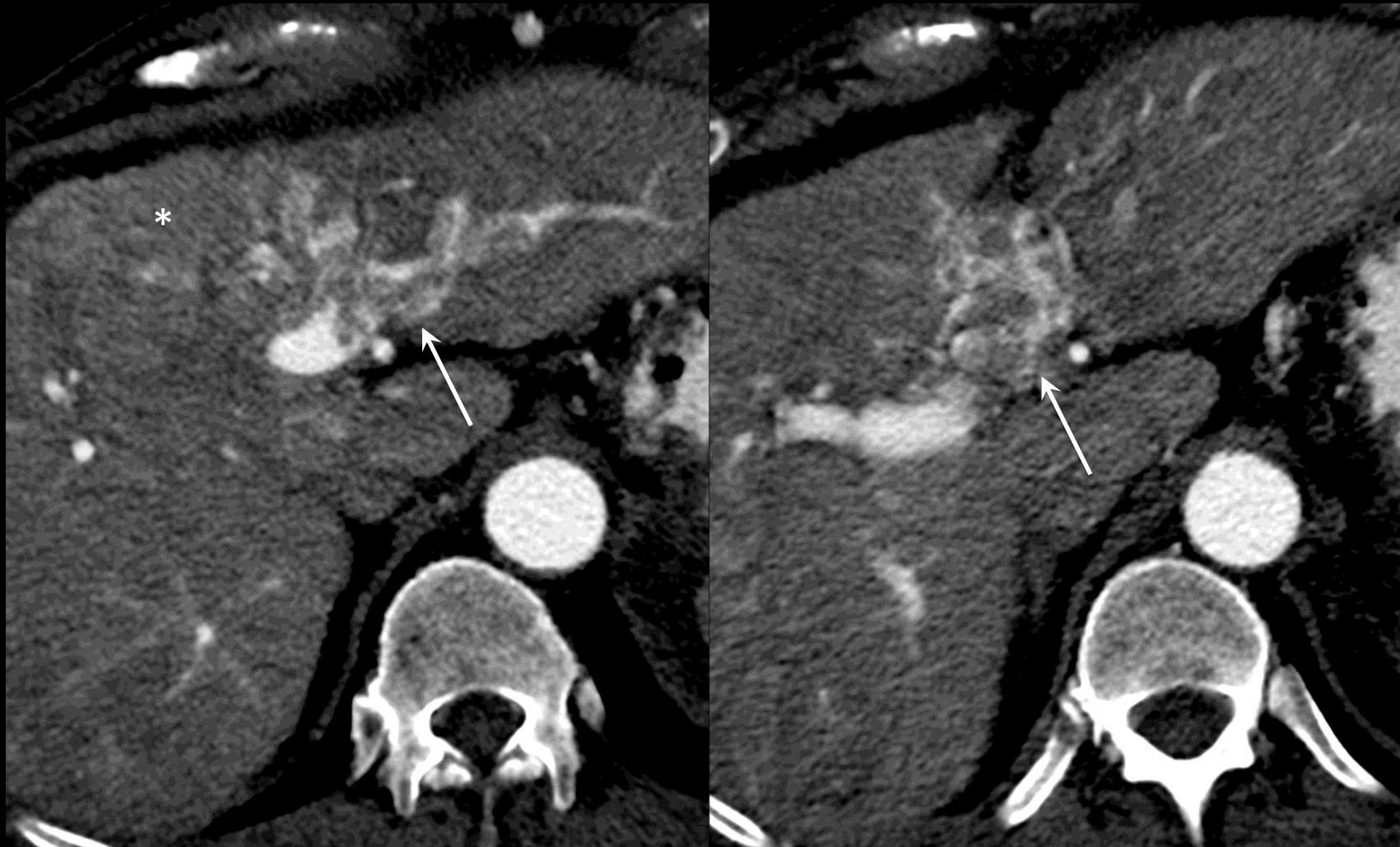- [Definite](#) enhancing soft tissue in vein.

### Comments:

- Observations with tumor in vein are categorized [LR5V](#).
- The term tumor in vein is preferred over the term tumor thrombus.
  - **Rationale:** the pathological spectrum ranges from thrombus with scant tumor cells to solid tumor with scant thrombus.
- Parenchymal mass may or may not be demonstrated at imaging.
- While not diagnostic of tumor in vein, features that may alert radiologist to diagnosis include:
  - Occluded vein with any of the following: moderately to markedly expanded lumen, ill-defined walls, [restricted diffusion](#), or contiguity with LR5 observation
  - Obscured, partially visualized vein
  - Heterogeneous enhancement of vein not attributable to mixing artifact



Arterial phase – Two slices through level of left portal vein



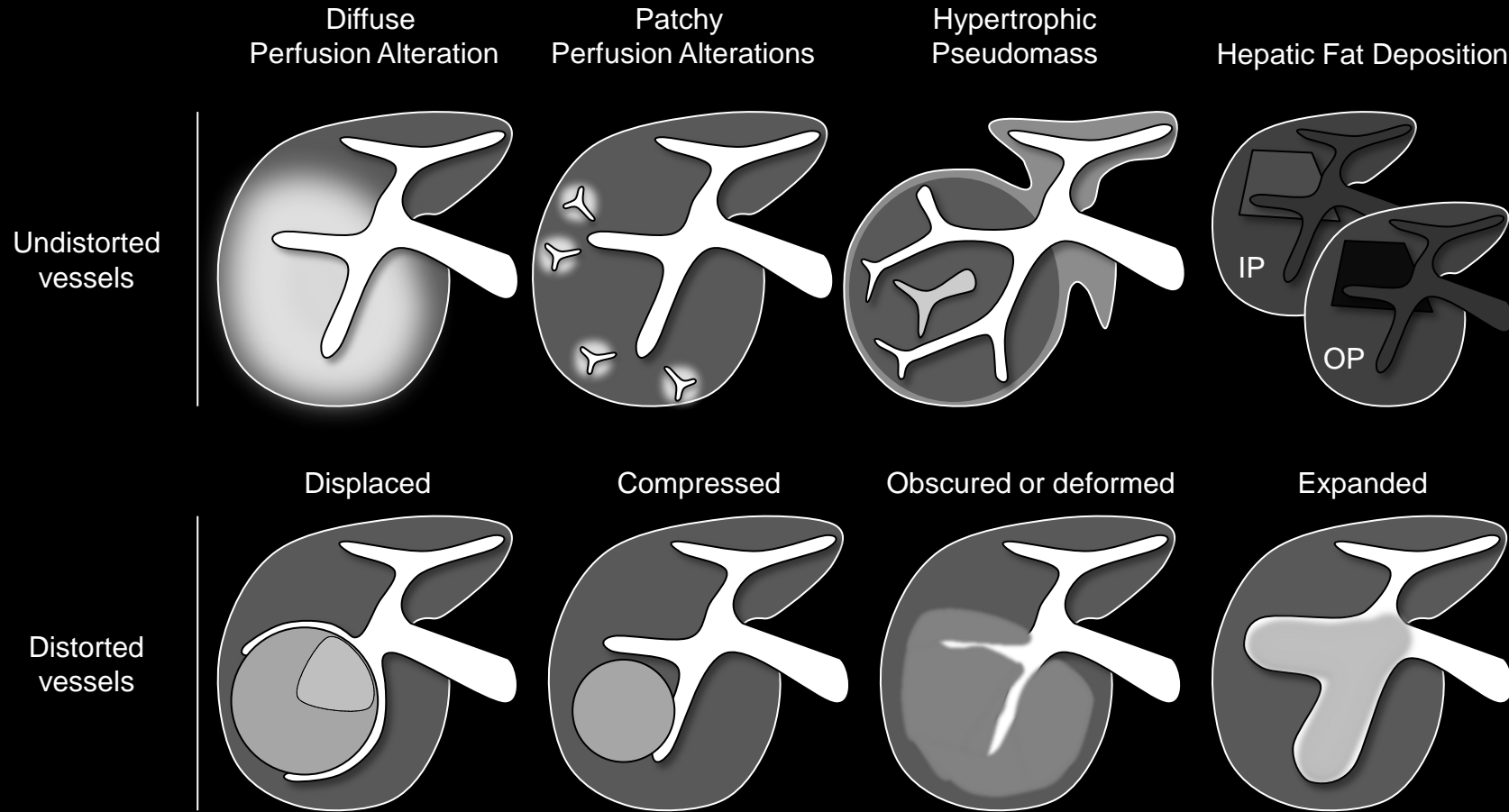
**Tumor in vein (CT):** Arterial phase axial CT images show enhancing soft tissue in left portal vein. There is mild expansion of the portal vein lumen with hyper-enhancing linear streaks, consistent with tumor in vein. As illustrated in this example, a parenchymal component (\*) may be difficult to visualize.

**Tumor in vein:**

**Comments (continued):**

- By comparison, non-tumoral bland thrombus does not enhance and usually does not expand lumen to same degree as tumor in vein.





## Undistorted vessels:

Vessels traversing an observation without displacement, deformation, or other alteration.

### Comments:

- Applies to observations through which vessels traverse without displacement, deformation, or other alteration.
- Presence of undistorted vessels traversing an observation is an [ancillary feature](#) favoring benignity.
- Radiologists at their discretion may apply undistorted vessels to downgrade category.

**Undistorted vessels:** Schematic diagrams illustrate undistorted vessels (top row) and distorted vessels (bottom row). Top row: Undistorted vessels follow a normal course without displacement, deformation, or other alteration, regardless of the presence of other observations. Bottom row: Distorted vessels are displaced or compressed by expansile masses, obscured or deformed by infiltrative masses, or expanded by intra-luminal masses. IP = in phase. OP = out of phase.



## **Unequivocal:**

Absolutely no doubt that the feature is present.  
Synonymous with [definite](#).

## **Comment:**

If there is any concern about the presence of the feature, it should be considered [equivocal](#).



**Vascular anomaly:**

Focal vascular abnormality.

**LI-RADS Categorization:**

- Observations thought to [definitely](#) represent vascular anomalies should be categorized [LR1](#).
- Observations thought to [probably](#) represent vascular anomalies should be categorized [LR2](#).
- Observations that are indeterminate for vascular anomalies versus HCC should be categorized [LR3](#) or [LR4](#).

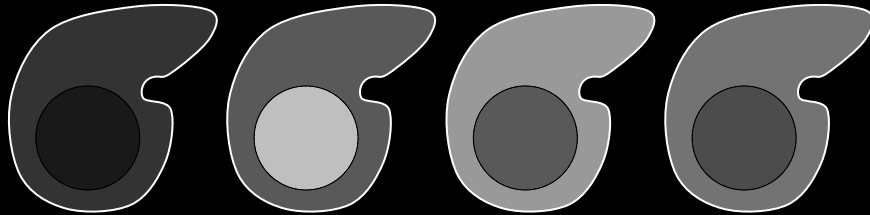
**Comments:**

- Most vascular anomalies are easily recognized, cause no diagnostic confusion, and do not require reporting. Radiologists may choose at their discretion to report a vascular anomaly.
- Examples of vascular anomalies that may be categorized [LR1](#) or [LR2](#), depending on level of certainty:
  - Aneurysm
  - Varix
  - Prominent vessel along liver surface
  - Cavernoma
  - Arterio-portal or arterio-venous fistula
  - Shunt vessel
  - Vascular malformation

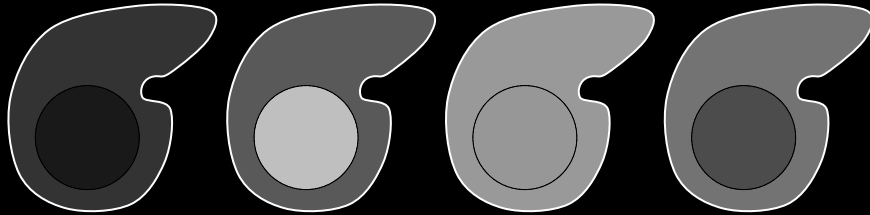
**Atlas:** CT, MR



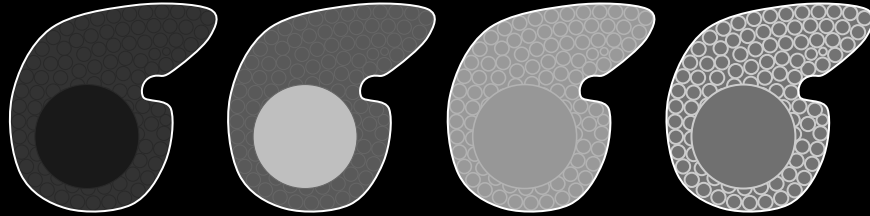
Pre      Arterial      Portal Venous      Delayed



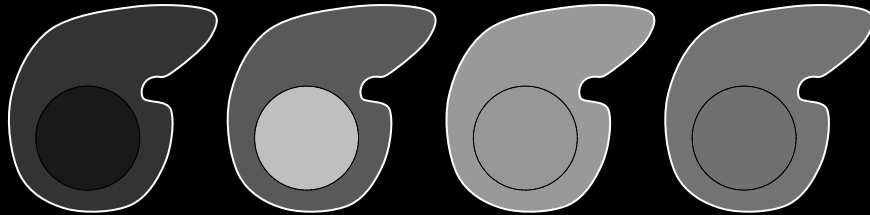
Arterial phase hyper-enhancement with “washout” of entire observation. Observation shows portal venous phase and delayed phase hypo-enhancement relative to liver parenchyma.



Arterial phase hyper-enhancement with “washout” of entire observation. Observation shows delayed phase hypo-enhancement relative to liver parenchyma.



Arterial phase hyper-enhancement with “washout” of entire observation. Observation shows portal venous and delayed phase hypo-enhancement relative to liver parenchyma. In this example, liver parenchyma visually consists of both nodules and fibrosis.



Arterial phase hyper-enhancement without portal venous or delayed phase “washout” of any part of observation. This is an example of [fade](#).

Washout appearance

Not washout appearance

**Washout appearance (in whole) after arterial phase hyper-enhancement:** Schematic diagrams illustrate arterial-phase hyper-enhancing observations with (top three rows) and without (bottom row) “washout”. If the liver parenchyma visually consists of both nodules and fibrosis (third row), then enhancement of the observation should be compared to that of the composite liver tissue. Observations may show “washout” in whole (this slide) or in part ([click here](#)). Also, they may show arterial phase hyper-enhancement (this slide) or arterial phase hypo- or iso-enhancement ([click here](#)).

## Washout appearance

Visually assessed temporal reduction in enhancement relative to liver from an earlier to a later phase resulting in [portal venous phase hypo-enhancement](#) or [delayed phase hypo-enhancement](#).

### If unsure about washout appearance:

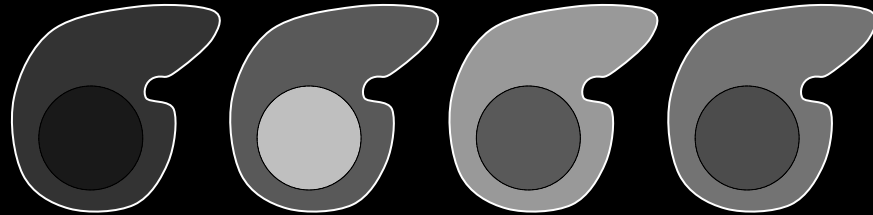
- Do not characterize as washout appearance.

### Comments:

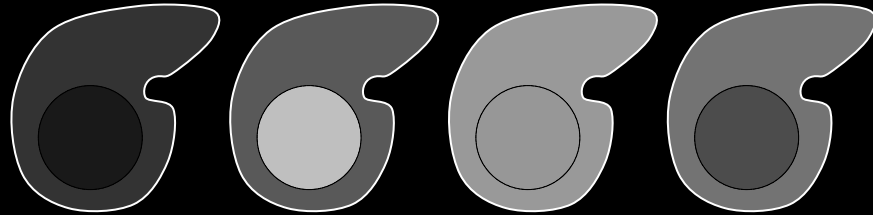
- Applies to observations that, by visual assessment, appear to “washout”:
  - In whole (see schematics on left) OR
  - In part ([click for schematics](#)).
- In the [arterial phase](#), the observations may be:
  - Hyper-enhancing (see schematics on left) OR
  - Hypo- or iso-enhancing ([click for schematics](#)).
- The enhancement of the observation should be compared to that of the adjacent liver parenchyma. If the liver parenchyma visually consists of both nodules and fibrosis, then enhancement of the observation should be compared to that of the composite liver tissue (i.e., a visual average of the nodules and fibrosis) (see schematics on left).



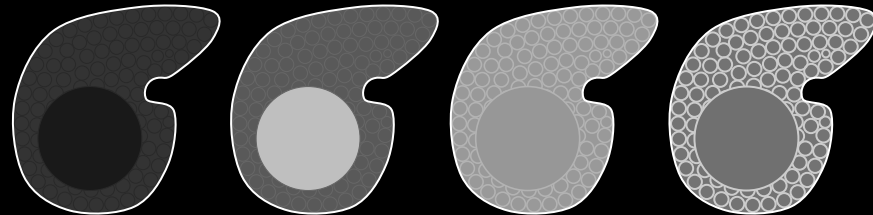
Pre      Arterial      Portal Venous      Delayed



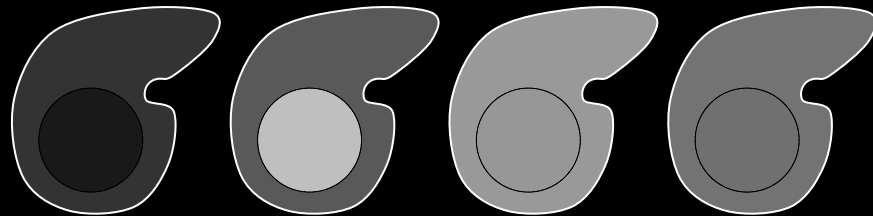
Arterial phase hyper-enhancement with “washout” of entire observation. Observation shows portal venous phase and delayed phase hypo-enhancement relative to liver parenchyma.



Arterial phase hyper-enhancement with “washout” of entire observation. Observation shows delayed phase hypo-enhancement relative to liver parenchyma.



Arterial phase hyper-enhancement with “washout” of entire observation. Observation shows portal venous and delayed phase hypo-enhancement relative to liver parenchyma. In this example, liver parenchyma visually consists of both nodules and fibrosis.



Arterial phase hyper-enhancement without portal venous or delayed phase “washout” of any part of observation. This is an example of [fade](#).

Washout appearance

Not washout appearance

**Washout appearance (in whole) after arterial phase hyper-enhancement:** Schematic diagrams illustrate arterial-phase hyper-enhancing observations with (top three rows) and without (bottom row) “washout”. If the liver parenchyma visually consists of both nodules and fibrosis (third row), then enhancement of the observation should be compared to that of the composite liver tissue. Observations may show “washout” in whole (this slide) or in part ([click here](#)). Also, they may show arterial phase hyper-enhancement (this slide) or arterial phase hypo- or iso-enhancement ([click here](#)).

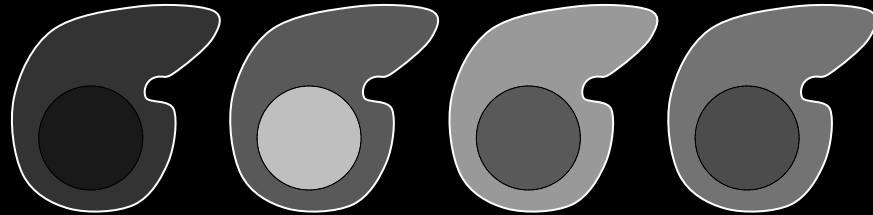
## Washout appearance

### Comments (continued):

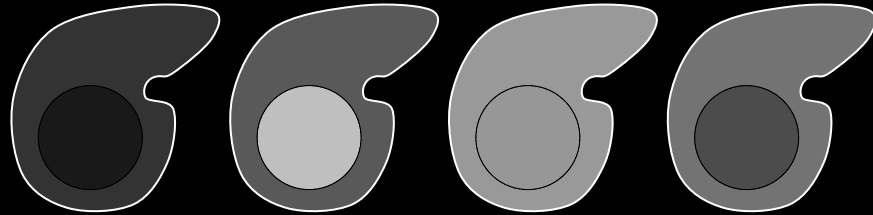
- Washout appearance is a LI-RADS [major feature](#) for categorization of masses that are neither [definite benign entities](#) nor [probable benign entities](#) and that lack features of [non-HCC malignancy](#) or [tumor in vein](#). For such masses, those with washout appearance may be categorized LR3, LR4, or LR5, depending on the observation’s arterial phase enhancement, diameter, and other features. As shown in [Table](#), masses with washout appearance but without arterial phase hyper-enhancement cannot be categorized LR5.
- As washout appearance is assessed visually, LI-RADS does not mandate objective assessment using ROI measurements, time-enhancement curves, or subtraction images.
- Radiologists at their discretion may use ROI measurements, time-enhancement curves, or, at MRI, subtraction images (e.g., arterial phase minus portal venous or delayed phase) to evaluate “washout”.
- For ROI measurements, time-enhancement curves, or subtractions to be valid, arterial phase and portal venous or delayed phase images need to be acquired with the same technique. In addition, subtractions require co-registration of the source images.



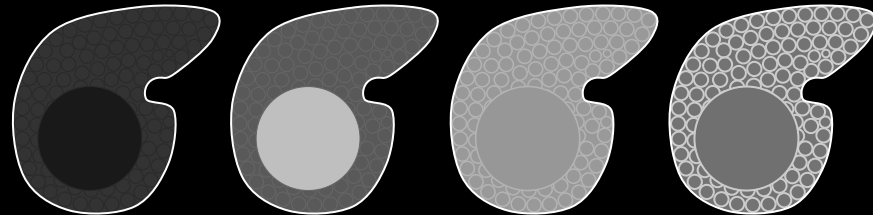
Pre      Arterial      Portal Venous      Delayed



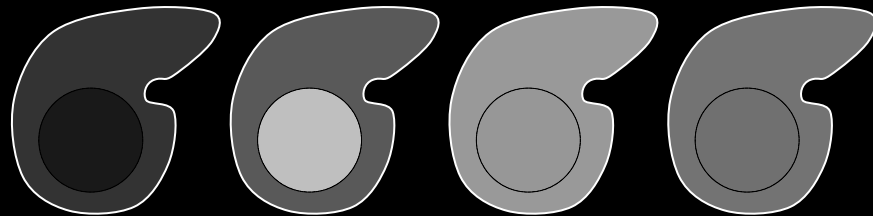
Arterial phase hyper-enhancement with “washout” of entire observation. Observation shows portal venous phase and delayed phase hypo-enhancement relative to liver parenchyma.



Arterial phase hyper-enhancement with “washout” of entire observation. Observation shows delayed phase hypo-enhancement relative to liver parenchyma.



Arterial phase hyper-enhancement with “washout” of entire observation. Observation shows portal venous and delayed phase hypo-enhancement relative to liver parenchyma. In this example, liver parenchyma visually consists of both nodules and fibrosis.



Arterial phase hyper-enhancement without portal venous or delayed phase “washout” of any part of observation. This is an example of [fade](#).

Washout appearance

Not washout appearance

## Washout appearance


### Comments (continued):

- The terms washout appearance and “washout” (with quotation marks) are preferred over the term washout.
- **Rationale:** The visually assessed temporal reduction in enhancement relative to liver may be due to progressive enhancement of the liver rather than actual de-enhancement of the observation.
- Delayed phase may be superior to portal venous phase for depicting washout appearance. Some observations may show washout appearance only in the delayed phase.

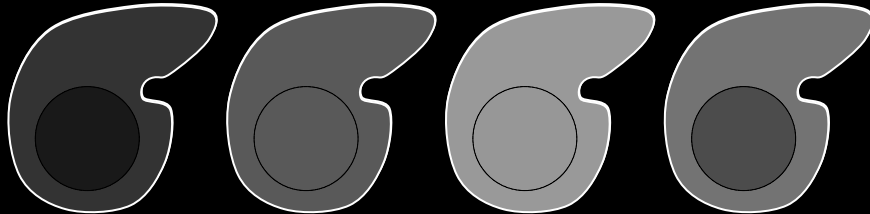
**Washout appearance (in whole) after arterial phase hyper-enhancement:** Schematic diagrams illustrate arterial-phase hyper-enhancing observations with (top three rows) and without (bottom row) “washout”. If the liver parenchyma visually consists of both nodules and fibrosis (third row), then enhancement of the observation should be compared to that of the composite liver tissue. Observations may show “washout” in whole (this slide) or in part ([click here](#)). Also, they may show arterial phase hyper-enhancement (this slide) or arterial phase hypo- or iso-enhancement ([click here](#)).



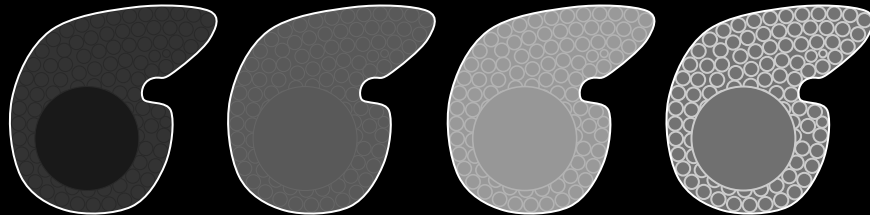
Pre      Arterial      Portal Venous      Delayed



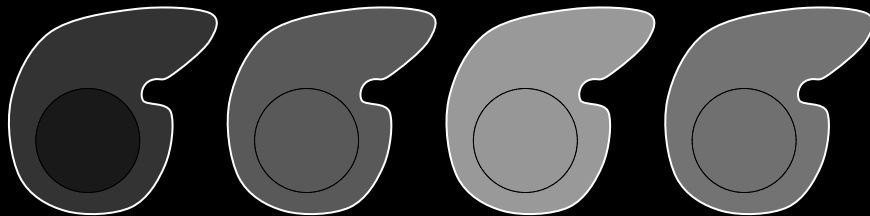
Arterial phase hypo-enhancement with “washout” of entire observation. Observation shows portal venous phase and delayed phase hypo-enhancement relative to liver parenchyma.



Arterial phase iso-enhancement with “washout” of entire observation. Observation shows delayed phase hypo-enhancement relative to liver parenchyma.



Arterial phase iso-enhancement with “washout” of entire observation. Observation shows portal venous and delayed phase hypo-enhancement relative to liver parenchyma. In this example, liver parenchyma visually consists of both nodules and fibrosis.



Arterial phase iso-enhancement without portal venous or delayed phase “washout” of any part of observation.

Washout appearance

Not washout appearance

**Washout appearance (in whole) after arterial phase hypo or iso-enhancement:** Schematic diagrams illustrate arterial-phase hypo- or iso-enhancing observations with (top three rows) and without (bottom row) “washout”. If the liver parenchyma visually consists of both nodules and fibrosis (third row), then enhancement of the observation should be compared to that of the composite liver tissue. Observations may show “washout” in whole (this slide) or in part ([click here](#)). Observations may show arterial phase hypo- or iso-enhancement (this slide) or hyper-enhancement ([click here](#)).

## Washout appearance

Visually assessed temporal reduction in enhancement relative to liver from an earlier to a later phase resulting in [portal venous phase hypo-enhancement](#) or [delayed phase hypo-enhancement](#).

### If unsure about washout appearance:

- Do not characterize as washout appearance.


### Comments:

- Applies to observations that, by visual assessment, appear to “washout”:
  - In whole (see schematics on left) OR
  - In part ([click for schematics](#)).
- In the [arterial phase](#), the observations may be:
  - Hyper-enhancing ([click for schematics](#)) OR
  - Hypo- or iso-enhancing (see schematics on left).
- The enhancement of the observation should be compared to that of the adjacent liver parenchyma. If the liver parenchyma visually consists of both nodules and fibrosis, then enhancement of the observation should be compared to that of the composite liver tissue (i.e., a visual average of the nodules and fibrosis) (see schematics on left).

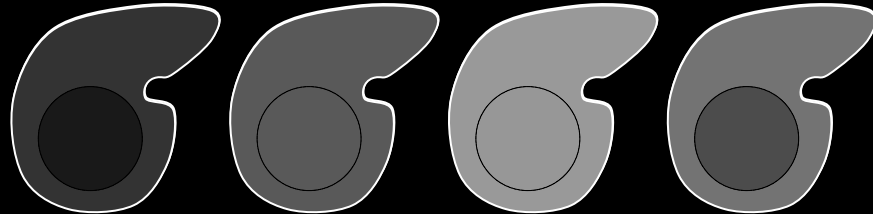





Pre      Arterial      Portal Venous      Delayed



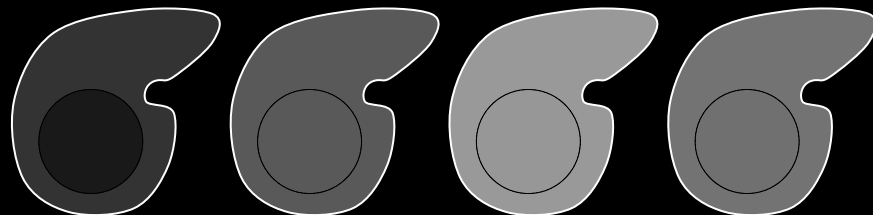
Arterial phase hypo-enhancement with “washout” of entire observation. Observation shows portal venous phase and delayed phase hypo-enhancement relative to liver parenchyma.



Arterial phase iso-enhancement with “washout” of entire observation. Observation shows delayed phase hypo-enhancement relative to liver parenchyma.



Arterial phase iso-enhancement with “washout” of entire observation. Observation shows portal venous and delayed phase hypo-enhancement relative to liver parenchyma. In this example, liver parenchyma visually consists of both nodules and fibrosis.



Arterial phase iso-enhancement without portal venous or delayed phase “washout” of any part of observation.

Washout appearance

Not washout appearance

**Washout appearance (in whole) after arterial phase hypo or iso-enhancement:** Schematic diagrams illustrate arterial-phase hypo- or iso-enhancing observations with (top three rows) and without (bottom row) “washout”. If the liver parenchyma visually consists of both nodules and fibrosis (third row), then enhancement of the observation should be compared to that of the composite liver tissue. Observations may show “washout” in whole (this slide) or in part ([click here](#)). Observations may show arterial phase hypo- or iso-enhancement (this slide) or hyper-enhancement ([click here](#)).

## Washout appearance

### Comments (continued):

- Washout appearance is a LI-RADS [major feature](#) for categorization of masses that are neither [definite benign entities](#) nor [probable benign entities](#) and that lack features of [non-HCC malignancy](#) or [tumor in vein](#). For such masses, those with washout appearance may be categorized LR3, LR4, or LR5, depending on the observation’s arterial phase enhancement, diameter, and other features. As shown in [Table](#), masses with washout appearance but without arterial phase hyper-enhancement cannot be categorized LR5.
- As washout appearance is assessed visually, LI-RADS does not mandate objective assessment using ROI measurements, time-enhancement curves, or subtraction images.
- Radiologists at their discretion may use ROI measurements, time-enhancement curves, or, at MRI, subtraction images (e.g., arterial phase minus portal venous or delayed phase) to evaluate “washout”.
- For ROI measurements, time-enhancement curves, or subtractions to be valid, arterial phase and portal venous or delayed phase images need to be acquired with the same technique. In addition, subtractions require co-registration of the source images.




## Washout appearance

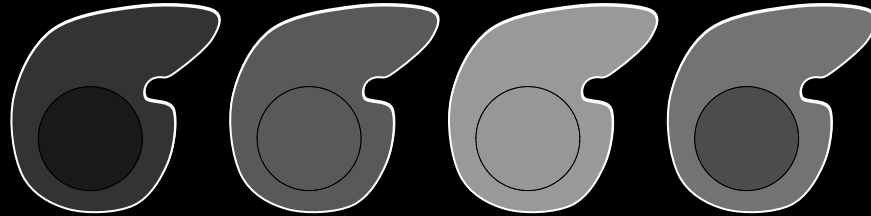
### Comments (continued):

- The terms washout appearance and “washout” (with quotation marks) are preferred over the term washout.
- **Rationale:** The visually assessed temporal reduction in enhancement relative to liver may be due to progressive enhancement of the liver rather than actual de-enhancement of the observation.
- Delayed phase may be superior to portal venous phase for depicting washout appearance. Some observations may show washout appearance only in the delayed phase.


Pre      Arterial      Portal Venous      Delayed



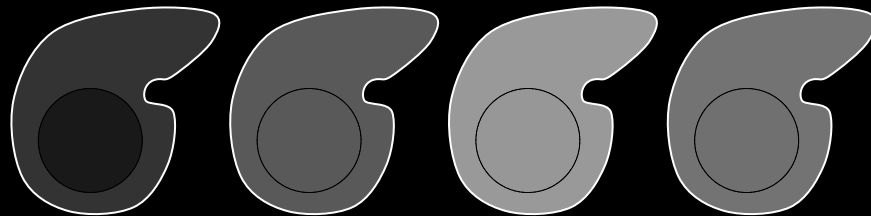
Arterial phase hypo-enhancement with “washout” of entire observation. Observation shows portal venous phase and delayed phase hypo-enhancement relative to liver parenchyma.



Arterial phase iso-enhancement with “washout” of entire observation. Observation shows delayed phase hypo-enhancement relative to liver parenchyma.



Arterial phase iso-enhancement with “washout” of entire observation. Observation shows portal venous and delayed phase hypo-enhancement relative to liver parenchyma. In this example, liver parenchyma visually consists of both nodules and fibrosis.



Arterial phase iso-enhancement without portal venous or delayed phase “washout” of any part of observation.

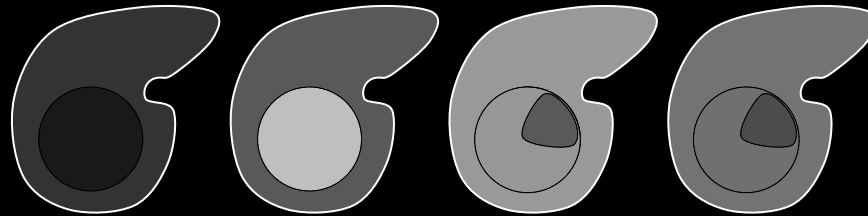
Washout appearance

Not washout appearance

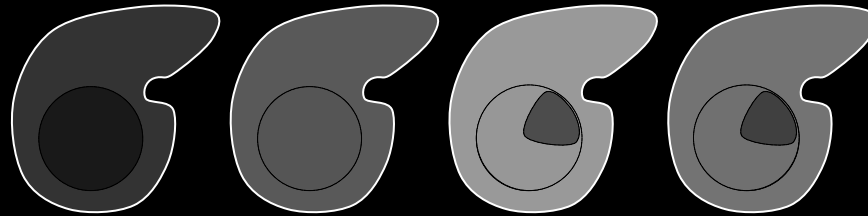
**Washout appearance (in whole) after arterial phase hypo or iso-enhancement:** Schematic diagrams illustrate arterial-phase hypo- or iso-enhancing observations with (top three rows) and without (bottom row) “washout”. If the liver parenchyma visually consists of both nodules and fibrosis (third row), then enhancement of the observation should be compared to that of the composite liver tissue. Observations may show “washout” in whole (this slide) or in part ([click here](#)). Observations may show arterial phase hypo- or iso-enhancement (this slide) or hyper-enhancement ([click here](#)).



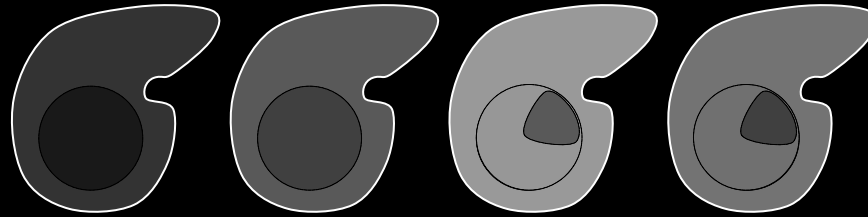
Pre      Arterial      Portal Venous      Delayed



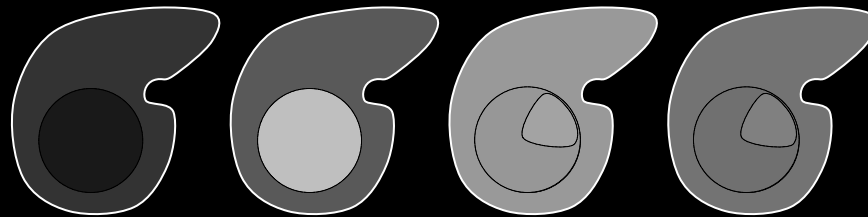
Arterial phase hyper-enhancement with portal venous and delayed phase “washout” of part of observation.



Arterial phase iso-enhancement with delayed phase “washout” of part of observation.



Arterial phase hypo-enhancement with delayed phase “washout” of part of observation.



Arterial phase hyper-enhancement without portal venous or delayed phase “washout” of any part of observation.

Washout appearance

Not washout appearance

## Washout appearance

Visually assessed temporal reduction in enhancement relative to liver from an earlier to a later phase resulting in [portal venous phase hypo-enhancement](#) or [delayed phase hypo-enhancement](#).

### If unsure about washout appearance:

- Do not characterize as washout appearance.

### Comments:

- Applies to observations that, by visual assessment, appear to “washout”
  - In whole ([click for schematics](#)) or
  - In part (see schematics on left).
- In the [arterial phase](#), the observations may be
  - Hyper-enhancing (see schematics on left) or
  - Hypo- or iso-enhancing ([click for schematics](#)).
- The enhancement of the observation should be compared to that of the adjacent liver parenchyma. If the liver parenchyma visually consists of both nodules and fibrosis, then enhancement of the observation should be compared to that of the composite liver tissue (i.e., a visual average of the nodules and fibrosis) (see schematics on left).

**Washout appearance (in part):** Schematic diagrams illustrate observations with (top three rows) and without (bottom row) “washout”. As shown on this slide, observations may show “washout” in part. Observations may show arterial phase arterial phase hyper-enhancement (top row), iso-enhancement (second row), or hypo-enhancement (third row).

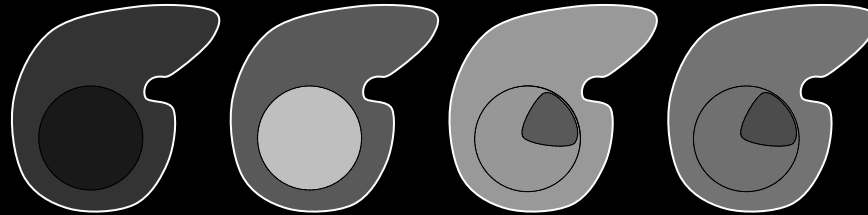


## Washout appearance

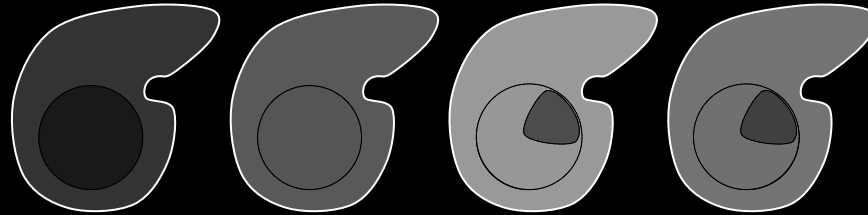
### Comments (continued):

- Washout appearance is a LI-RADS [major feature](#) for categorization of masses that are neither [definite benign entities](#) nor [probable benign entities](#) and that lack features of [non-HCC malignancy](#) or [tumor in vein](#). For such masses, those with washout appearance may be categorized LR3, LR4, or LR5, depending on the observation's arterial phase enhancement, diameter, and other features. As shown in [Table](#), masses with washout appearance but without arterial phase hyper-enhancement cannot be categorized LR5.
- As washout appearance is assessed visually, LI-RADS does not mandate objective assessment using ROI measurements, time-enhancement curves, or subtraction images.
- Radiologists at their discretion may use ROI measurements, time-enhancement curves, or, at MRI, subtraction images (e.g., arterial phase minus portal venous or delayed phase) to evaluate "washout".
- For ROI measurements, time-enhancement curves, or subtractions to be valid, arterial phase and portal venous or delayed phase images need to be acquired with the same technique. In addition, subtractions require co-registration of the source images.

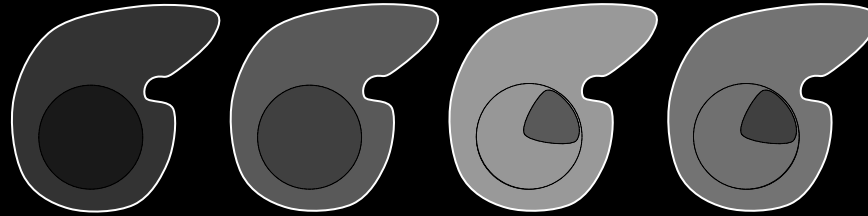
Pre      Arterial      Portal Venous      Delayed



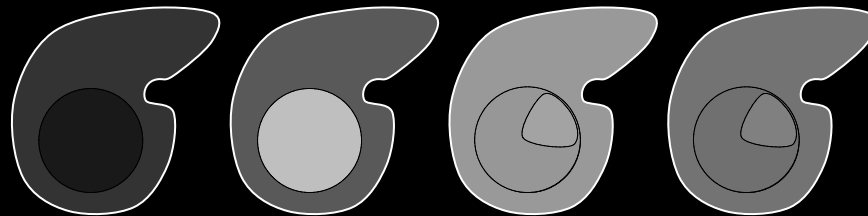
Arterial phase hyper-enhancement with portal venous and delayed phase "washout" of part of observation.



Arterial phase iso-enhancement with delayed phase "washout" of part of observation.



Arterial phase hypo-enhancement with delayed phase "washout" of part of observation.



Arterial phase hyper-enhancement without portal venous or delayed phase "washout" of any part of observation.

Washout appearance

Not washout appearance

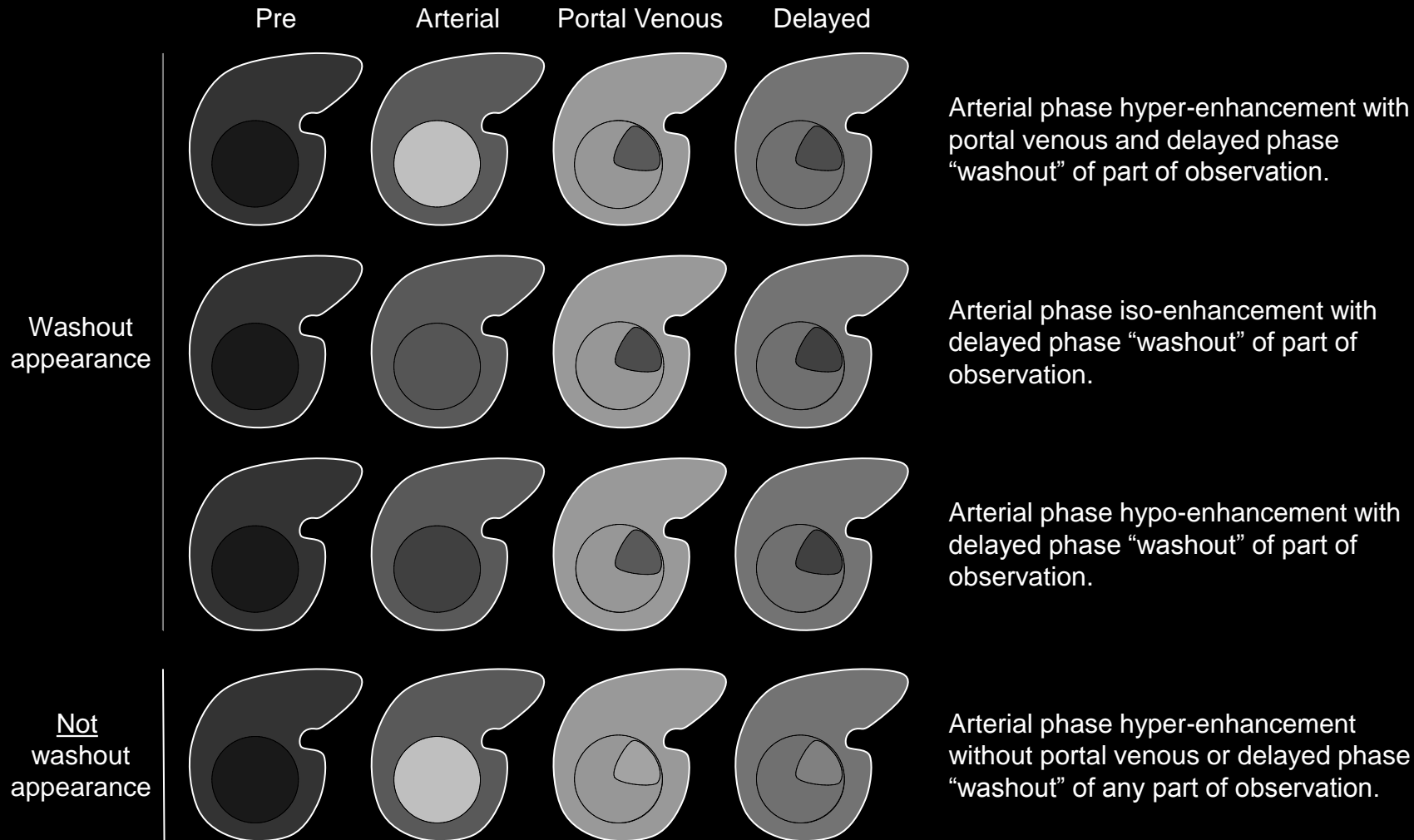
**Washout appearance (in part):** Schematic diagrams illustrate observations with (top three rows) and without (bottom row) "washout". As shown on this slide, observations may show "washout" in part. Observations may show arterial phase arterial phase hyper-enhancement (top row), iso-enhancement (second row), or hypo-enhancement (third row).



## Washout appearance

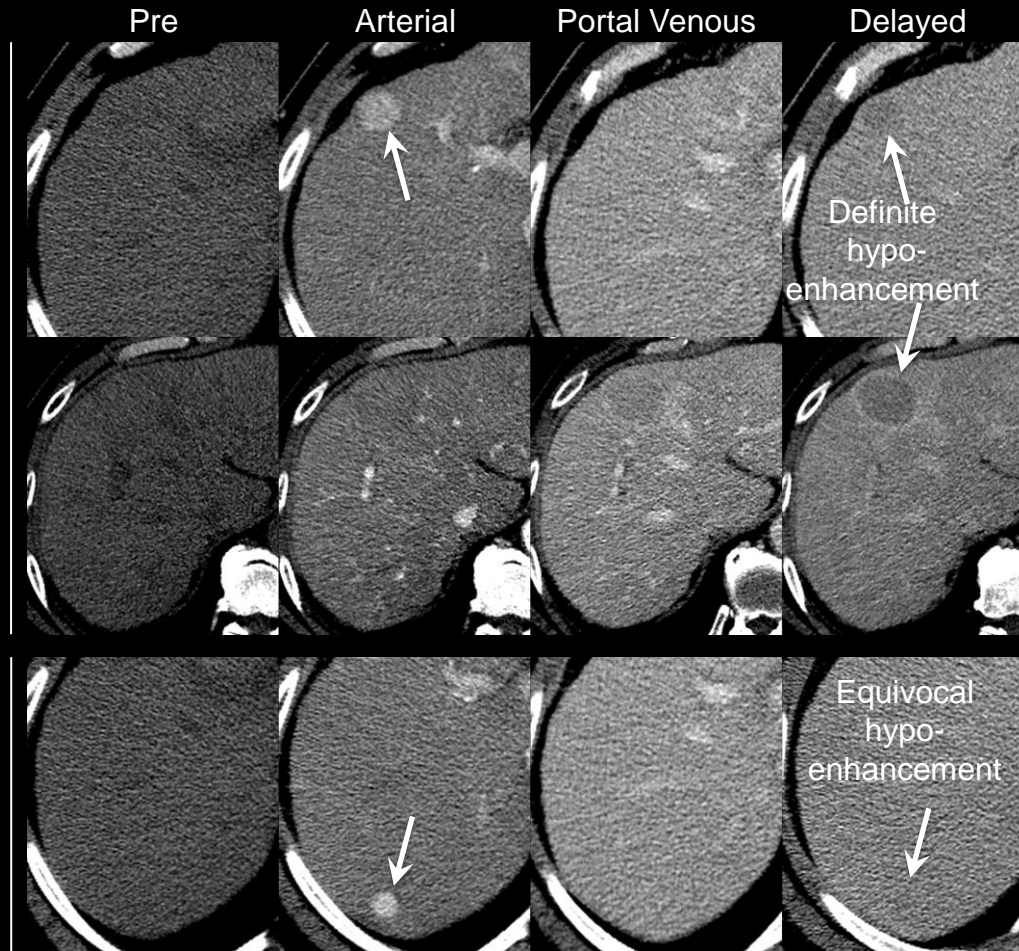
### Comments (continued):

- The terms washout appearance and “washout” (with quotation marks) are preferred over the term washout.
- Rationale:** The visually assessed temporal reduction in enhancement relative to liver may be due to progressive enhancement of the liver rather than actual de-enhancement of the observation.
- Delayed phase may be superior to portal venous phase for depicting washout appearance. Some observations may show washout appearance only in the delayed phase.



**Washout appearance (in part):** Schematic diagrams illustrate observations with (top three rows) and without (bottom row) “washout”. As shown on this slide, observations may show “washout” in part. Observations may show arterial phase arterial phase hyper-enhancement (top row), iso-enhancement (second row), or hypo-enhancement (third row).





Washout appearance

Not washout appearance

Arterial phase hyper-enhancement with delayed phase “washout” of observation.

Arterial phase iso-enhancement with portal venous and delayed phase “washout” of observation. “Capsule” also present.

Arterial phase hyper-enhancement with equivocal delayed phased hypo-enhancement. Do not characterize as “washout”.

## Washout appearance

Visually assessed temporal reduction in enhancement relative to liver from an earlier to a later phase resulting in [portal venous phase hypo-enhancement](#) or [delayed phase hypo-enhancement](#).

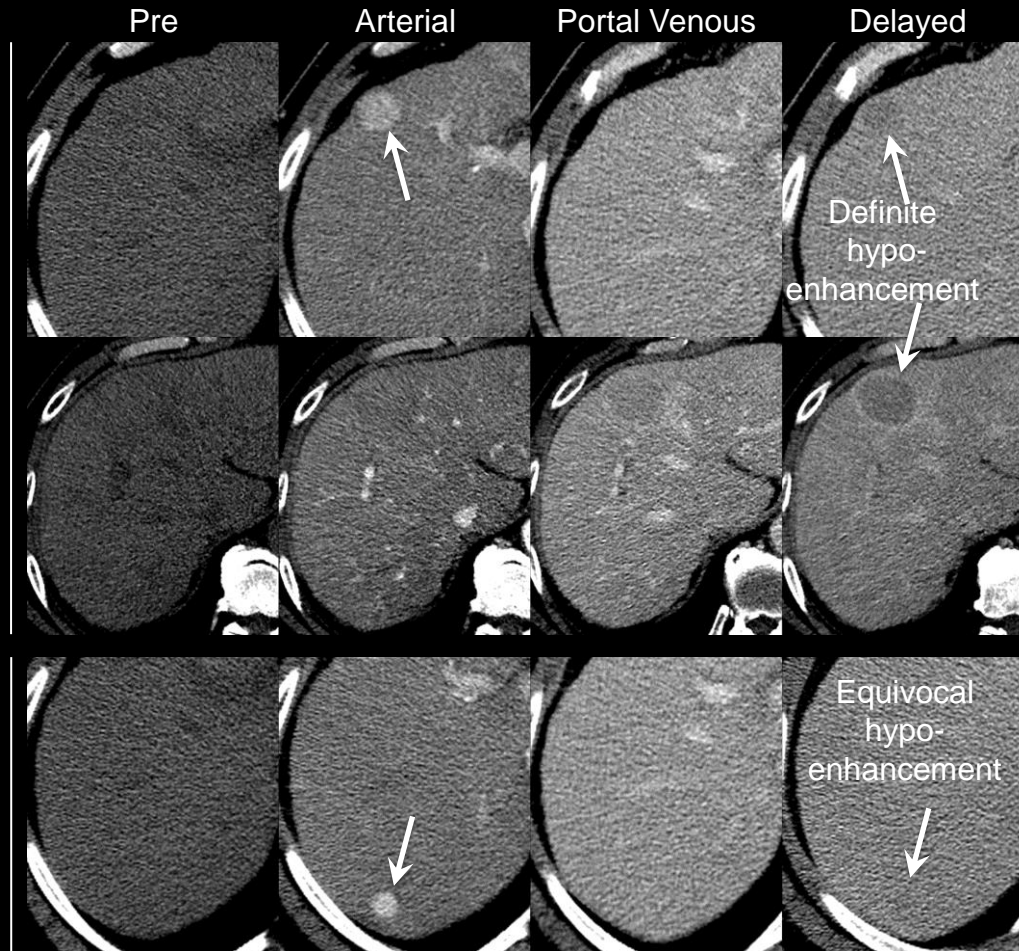
### If unsure about washout appearance:

- Do not characterize as washout appearance.

### Comments:

- Applies to observations that, by visual assessment, appear to “washout”:
  - In whole ([click for schematics](#)) OR
  - In part ([click for schematics](#)).
- In the [arterial phase](#), the observations may be:
  - Hyper-enhancing ([click for schematics](#)) OR
  - Hypo- or iso-enhancing ([click for schematics](#)).
- The enhancement of the observation should be compared to that of the adjacent liver parenchyma. If the liver parenchyma visually consists of both nodules and fibrosis, then enhancement of the observation should be compared to that of the composite liver tissue (i.e., a visual average of the nodules and fibrosis) (see schematics on left).

**Washout appearance (CT):** CT images of masses with (top two rows) and without (bottom row) washout appearance. Top row: arterial phase hyper-enhancing 23mm mass hypo-enhances in delayed phase (washout appearance). Mass is iso-attenuating to liver in portal venous phase. Middle row: arterial phase iso-enhancing 35mm mass hypo-enhances in portal venous and delayed phase (washout appearance). Notice incidentally presence of “capsule”. As shown in both cases, delayed phase images may show “washout” to better advantage than portal venous phase images. Bottom row: arterial phase hyper-enhancing 11mm mass fades to iso-attenuation in portal venous phase. There is equivocal delayed phase hypo-enhancement. Equivocal hypo-enhancement should not be characterized as “washout”.



Washout appearance

Not washout appearance

Arterial phase hyper-enhancement with delayed phase “washout” of observation.

Arterial phase iso-enhancement with portal venous and delayed phase “washout” of observation. “Capsule” also present.

Arterial phase hyper-enhancement with equivocal delayed phased hypo-enhancement. Do not characterize as “washout”.

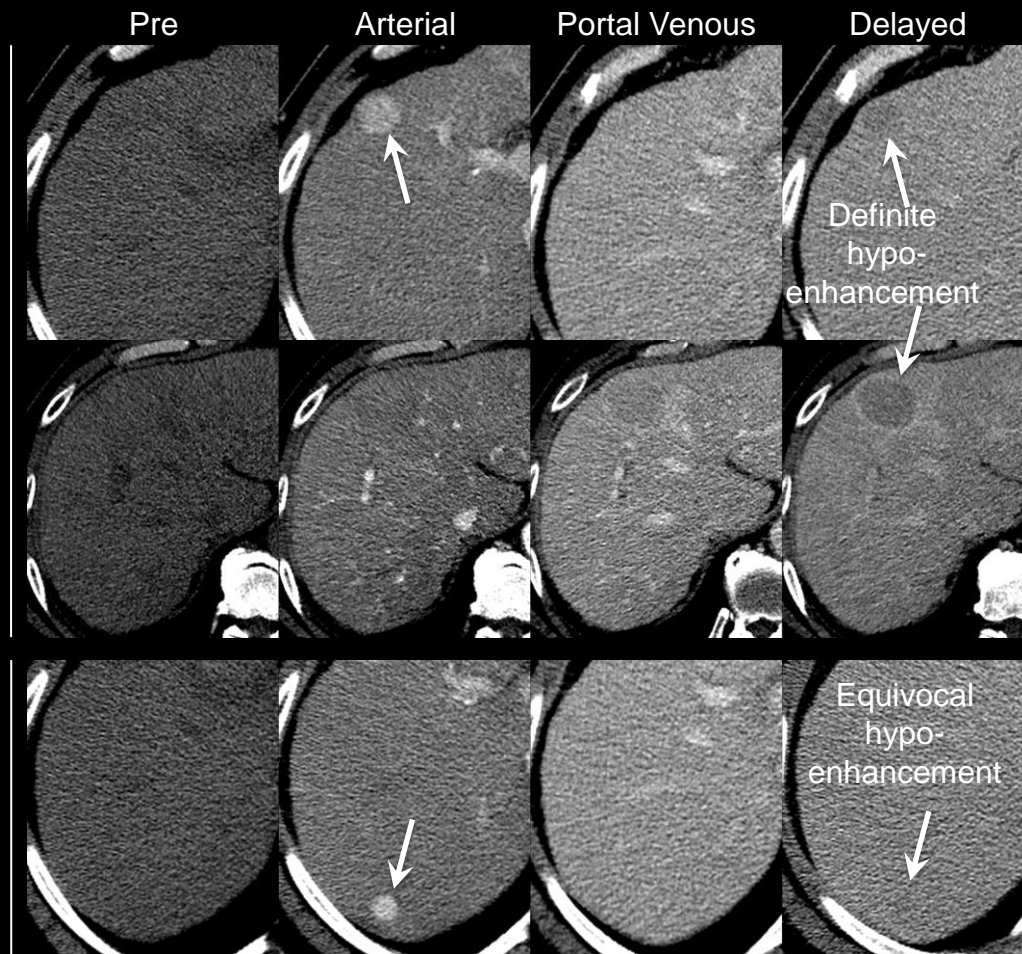
## Washout appearance

### Comments (continued):

- Washout appearance is a LI-RADS [major feature](#) for categorization of masses that are neither [definite benign entities](#) nor [probable benign entities](#) and that lack features of [non-HCC malignancy](#) or [tumor in vein](#). For such masses, those with washout appearance may be categorized LR3, LR4, or LR5, depending on the observation’s arterial phase enhancement, diameter, and other features. As shown in [Table](#), masses with washout appearance but without arterial phase hyper-enhancement cannot be categorized LR5.
- As washout appearance is assessed visually, LI-RADS does not mandate objective assessment using ROI measurements, time-enhancement curves, or subtraction images.
- Radiologists at their discretion may use ROI measurements, time-enhancement curves, or, at MRI, subtraction images (e.g., arterial phase minus portal venous or delayed phase) to evaluate “washout”.
- For ROI measurements, time-enhancement curves, or subtractions to be valid, arterial phase and portal venous or delayed phase images need to be acquired with the same technique. In addition, subtractions require co-registration of the source images.

**Washout appearance (CT):** CT images of masses with (top two rows) and without (bottom row) washout appearance. Top row: arterial phase hyper-enhancing 23mm mass hypo-enhances in delayed phase (washout appearance). Mass is iso-attenuating to liver in portal venous phase. Middle row: arterial phase iso-enhancing 35mm mass hypo-enhances in portal venous and delayed phase (washout appearance). Notice incidentally presence of “capsule”. As shown in both cases, delayed phase images may show “washout” to better advantage than portal venous phase images. Bottom row: arterial phase hyper-enhancing 11mm mass fades to iso-attenuation in portal venous phase. There is equivocal delayed phase hypo-enhancement. Equivocal hypo-enhancement should not be characterized as “washout”.





**Washout appearance (CT):** CT images of masses with (top two rows) and without (bottom row) washout appearance. Top row: arterial phase hyper-enhancing 23mm mass hypo-enhances in delayed phase (washout appearance). Mass is iso-attenuating to liver in portal venous phase. Middle row: arterial phase iso-enhancing 35mm mass hypo-enhances in portal venous and delayed phase (washout appearance). Notice incidentally presence of “capsule”. As shown in both cases, delayed phase images may show “washout” to better advantage than portal venous phase images. Bottom row: arterial phase hyper-enhancing 11mm mass fades to iso-attenuation in portal venous phase. There is equivocal delayed phase hypo-enhancement. Equivocal hypo-enhancement should not be characterized as “washout”.

## Washout appearance

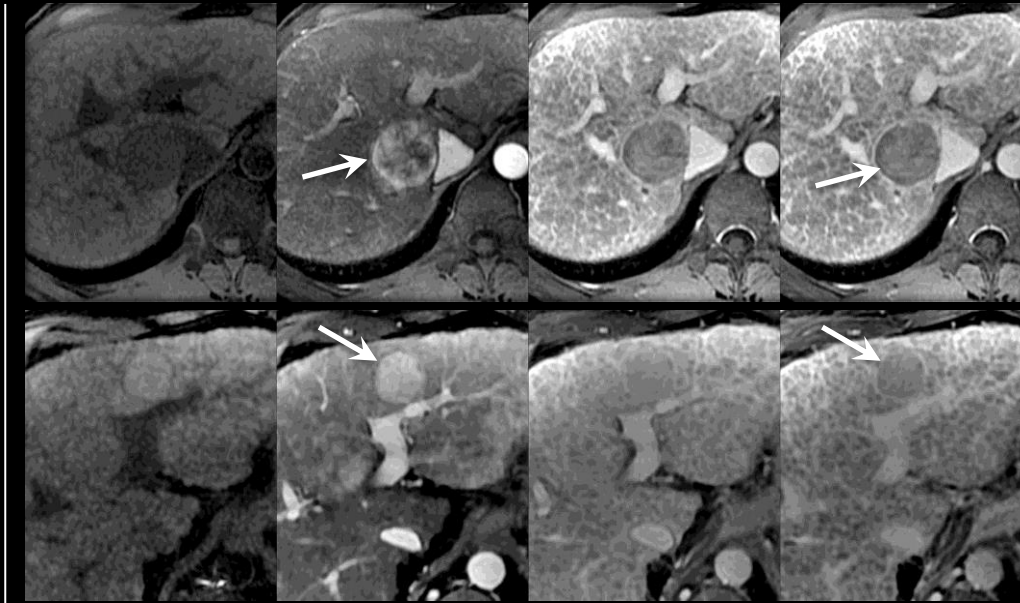
### Comments (continued):

- The terms washout appearance and “washout” (with quotation marks) are preferred over the term washout.
- Rationale:** The visually assessed temporal reduction in enhancement relative to liver may be due to progressive enhancement of the liver rather than actual de-enhancement of the observation.
- Delayed phase may be superior to portal venous phase for depicting washout appearance. Some observations may show washout appearance only in the delayed phase.



Washout appearance

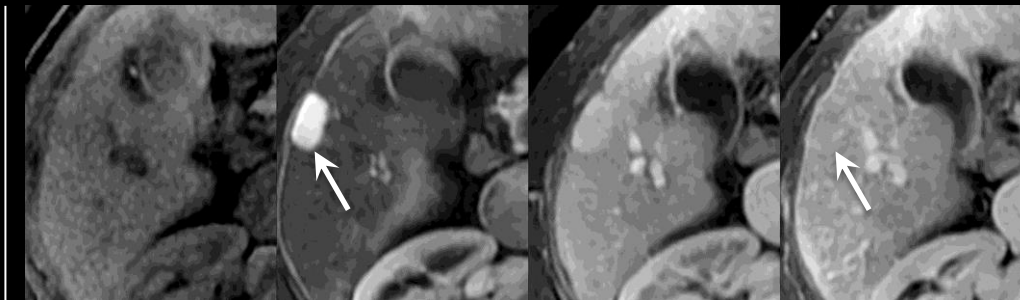
Pre Arterial Portal Venous Delayed



Arterial phase hyper-enhancement with portal venous and delayed phase “washout” of observation. “Capsule” also present.

Arterial phase hyper-enhancement with delayed phase “washout” of observation compared to background composite liver tissue. “Capsule” also present.

Not washout appearance



Arterial phase hyper-enhancement with equivocal delayed phased hypo-enhancement. Do not characterize as “washout”.

**Washout appearance (MRI):** MR images of masses with (top two rows) and without (bottom row) washout appearance. Top row: arterial phase hyper-enhancing 38mm mass hypo-enhances in portal venous and delayed phase (washout appearance). Notice incidentally presence of “capsule”. Middle row: arterial phase hyper-enhancing 27mm mass hypo-enhances in delayed phase compared to background composite liver tissue (washout appearance). Notice incidentally presence of “capsule”. Bottom row: arterial phase hyper-enhancing 20mm mass fades to faint residual hyper-enhancement in portal venous phase. There is equivocal delayed phase hypo-enhancement. Equivocal hypo-enhancement should not be characterized as “washout”.

## Washout appearance

Visually assessed temporal reduction in enhancement relative to liver from an earlier to a later phase resulting in [portal venous phase hypo-enhancement](#) or [delayed phase hypo-enhancement](#).

### If unsure about washout appearance:

- Do not characterize as washout appearance.

### Comments:

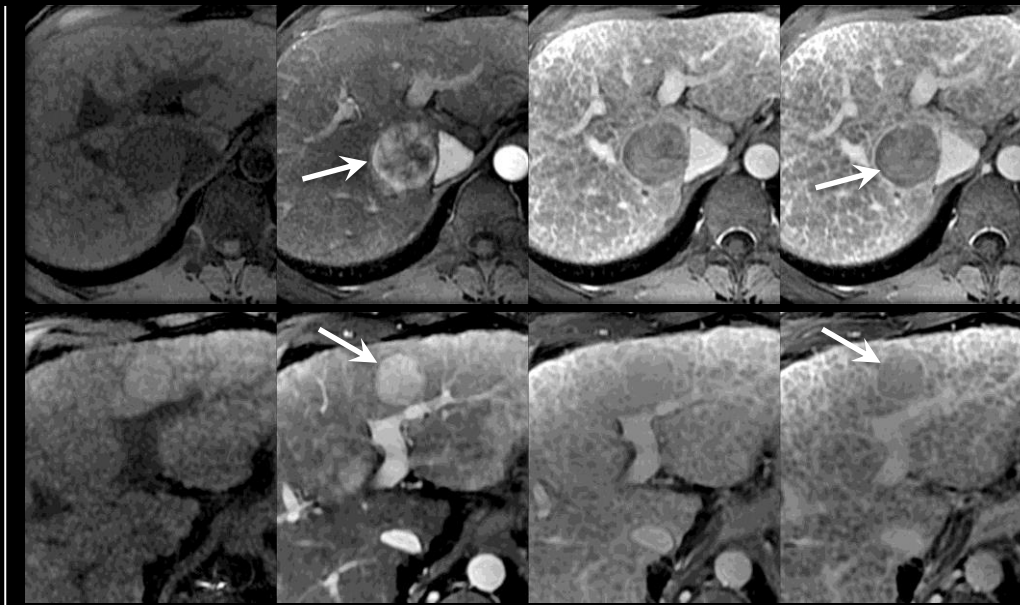
- Applies to observations that, by visual assessment, appear to “washout”:
  - In whole ([click for schematics](#)) OR
  - In part ([click for schematics](#)).
- In the [arterial phase](#), the observations may be:
  - Hyper-enhancing ([click for schematics](#)) OR
  - Hypo- or iso-enhancing ([click for schematics](#)).
- The enhancement of the observation should be compared to that of the adjacent liver parenchyma. If the liver parenchyma visually consists of both nodules and fibrosis, then enhancement of the observation should be compared to that of the composite liver tissue (i.e., a visual average of the nodules and fibrosis) (see schematics on left).





Washout appearance

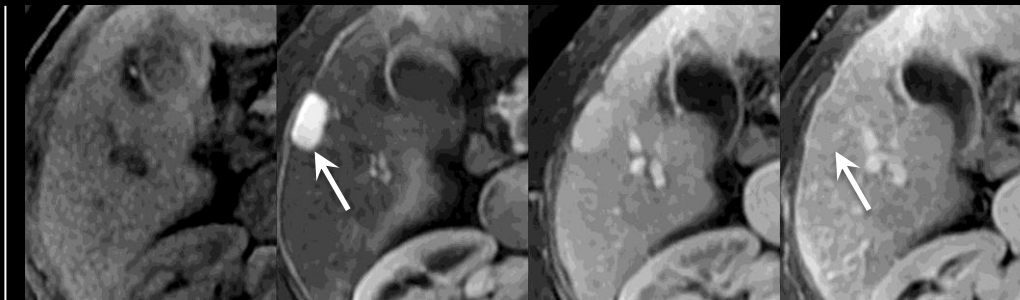
Pre      Arterial      Portal Venous      Delayed



Arterial phase hyper-enhancement with portal venous and delayed phase “washout” of observation. “Capsule” also present.

Arterial phase hyper-enhancement with delayed phase “washout” of observation compared to background composite liver tissue. “Capsule” also present.

Not washout appearance



Arterial phase hyper-enhancement with equivocal delayed phased hypo-enhancement. Do not characterize as “washout”.

**Washout appearance (MRI):** MR images of masses with (top two rows) and without (bottom row) washout appearance. Top row: arterial phase hyper-enhancing 38mm mass hypo-enhances in portal venous and delayed phase (washout appearance). Notice incidentally presence of “capsule”. Middle row: arterial phase hyper-enhancing 27mm mass hypo-enhances in delayed phase compared to background composite liver tissue (washout appearance). Notice incidentally presence of “capsule”. Bottom row: arterial phase hyper-enhancing 20mm mass fades to faint residual hyper-enhancement in portal venous phase. There is equivocal delayed phase hypo-enhancement. Equivocal hypo-enhancement should not be characterized as “washout”.

## Washout appearance

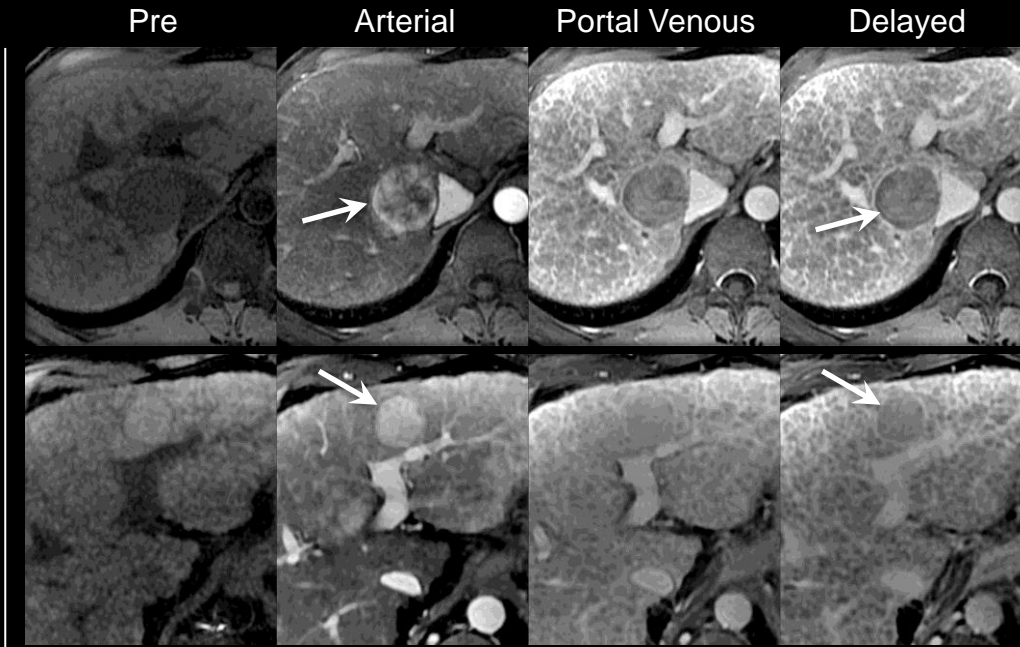
### Comments (continued):

- Washout appearance is a LI-RADS [major feature](#) for categorization of masses that are neither [definite benign entities](#) nor [probable benign entities](#) and that lack features of [non-HCC malignancy](#) or [tumor in vein](#). For such masses, those with washout appearance may be categorized LR3, LR4, or LR5, depending on the observation’s arterial phase enhancement, diameter, and other features. As shown in [Table](#), masses with washout appearance but without arterial phase hyper-enhancement cannot be categorized LR5.
- As washout appearance is assessed visually, LI-RADS does not mandate objective assessment using ROI measurements, time-enhancement curves, or subtraction images.
- Radiologists at their discretion may use ROI measurements, time-enhancement curves, or, at MRI, subtraction images (e.g., arterial phase minus portal venous or delayed phase) to evaluate “washout”.
- For ROI measurements, time-enhancement curves, or subtractions to be valid, arterial phase and portal venous or delayed phase images need to be acquired with the same technique. In addition, subtractions require co-registration of the source images.





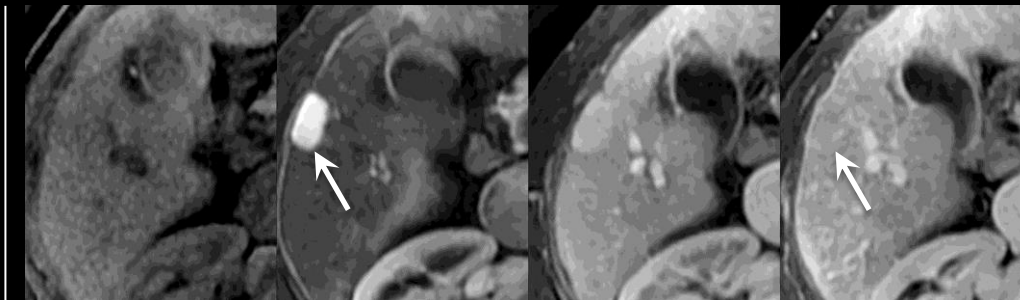
Washout appearance



Arterial phase hyper-enhancement with portal venous and delayed phase “washout” of observation. “Capsule” also present.

Arterial phase hyper-enhancement with delayed phase “washout” of observation compared to background composite liver tissue. “Capsule” also present.

Not washout appearance



Arterial phase hyper-enhancement with equivocal delayed phased hypo-enhancement. Do not characterize as “washout”.

**Washout appearance (MRI):** MR images of masses with (top two rows) and without (bottom row) washout appearance. Top row: arterial phase hyper-enhancing 38mm mass hypo-enhances in portal venous and delayed phase (washout appearance). Notice incidentally presence of “capsule”. Middle row: arterial phase hyper-enhancing 27mm mass hypo-enhances in delayed phase compared to background composite liver tissue (washout appearance). Notice incidentally presence of “capsule”. Bottom row: arterial phase hyper-enhancing 20mm mass fades to faint residual hyper-enhancement in portal venous phase. There is equivocal delayed phase hypo-enhancement. Equivocal hypo-enhancement should not be characterized as “washout”.

## Washout appearance

### Comments (continued):

- The terms washout appearance and “washout” (with quotation marks) are preferred over the term washout.
- **Rationale:** The visually assessed temporal reduction in enhancement relative to liver may be due to progressive enhancement of the liver rather than actual de-enhancement of the observation.
- Delayed phase may be superior to portal venous phase for depicting washout appearance. Some observations may show washout appearance only in the delayed phase.

**Wedge-shaped:**

Triangular in shape.

**Comments:**

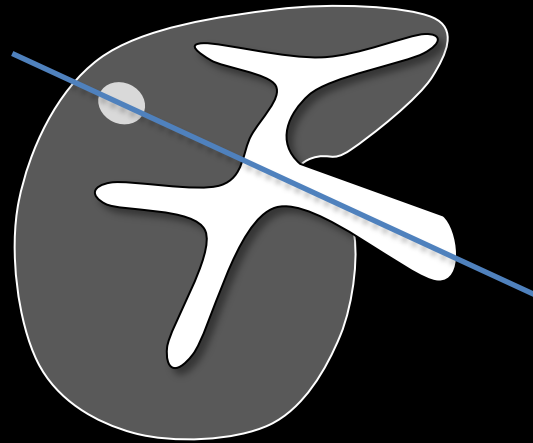
- Applies to observations that are roughly triangular in shape in one or more planes.
- Such observations frequently are peripherally located within the liver.
- Borders may be
  - Well-defined or ill-defined
  - Straight, concave, or convex
- Depending on their orientation to the imaging plane, some observations may appear rounded in the imaging plane but wedge shaped in a reformatted image.

**Atlas:** CT, MR

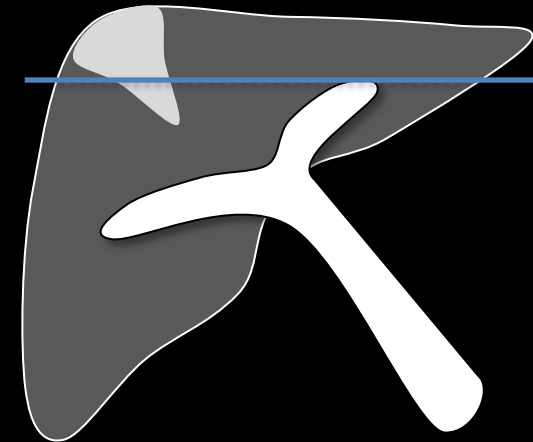
Wedge-shaped observations



Axial source image



3D Oblique Coronal Reformatted Image



**Wedge shaped:** Left: schematic diagrams illustrates wedge-shaped observations. Such observations may be of variable size. Borders may be well-defined or ill-defined, and they may be straight, concave, or convex. Right: some observations may not appear wedge-shaped on source images but appear wedge-shaped on reformatted images.



## Acknowledgments

### LI-RADS Committee

Mustafa Bashir <sup>1,2</sup>	Alexander Kagen
Giuseppe Brancatelli	Daniel Margolis
James Brink	Frank Miller <sup>1</sup>
Jeffrey Brown	Don Mitchell <sup>1,2</sup>
Irene Cruite <sup>1,2</sup>	Mariam Moshiri
Guilherme Cunha <sup>2</sup>	Aliya Qayyum
Richard Do	Daniel Rubin <sup>1</sup>
Michael Federle	Dushyant Sahani
Sebastian Flacke <sup>1</sup>	Riad Salem
Kathryn Fowler	Cynthia Santillan <sup>1,2</sup>
Alessandro Furlan	Amol Shah <sup>2</sup>
Karthik Ganesan <sup>1</sup>	Claude Sirlin, Chair <sup>1,2</sup>
Jeff Geschwind	An Tang <sup>1,2</sup>
Jay Heiken <sup>1,2</sup>	Bachir Taouli <sup>1</sup>
Tom Hope <sup>1,2</sup>	Jeff Weinreb <sup>1</sup>
Hero Hussain <sup>1</sup>	Benjamin Yeh <sup>1,2</sup>
Shahid Hussain	
Reena Jha <sup>1</sup>	

### Image Contribution

Emil Achmad  
 Giuseppe Brancatelli  
 Irene Cruite  
 Guilherme Cunha  
 Richard Do  
 Karthik Ganesan  
 Reena Jha  
 Alexander Kagen  
 Daniel Margolis  
 Arian Mashhood  
 Dushyant Sahani  
 Cynthia Santillan  
 Amol Shah  
 Claude Sirlin  
 An Tang  
 Bachir Taouli

### Phase 1 & 2 Readers

Dean Asher  
 Garney Fendley  
 Karthik Ganesan Alexander  
 Guimaraes Masoom Haider  
 Jay Heiken  
 Reena Jha  
 Kartik Jhaveri  
 Donald Mitchell  
 Irene Cruite  
 Jinha Park  
 Cynthia Santillan  
 Claude Sirlin  
 Jeffrey Weinreb  
 Benjamin Yeh

### Consultants to LI-RADS Committee

Elizabeth Brunt	Rajender Reddy
Robert Gish	Mario Strazzabosco
Zachary Goodman	Christoph Wald
Marquis Hart	
Julie Heimbach	
Alan Hemming	

### Design

Guilherme Cunha  
 Amol Shah  
 Claude Sirlin  
 An Tang

### ACR

Laura Coombs  
 Mythreyi B Chatfield

<sup>1</sup>Steering committee, <sup>2</sup>Working group



<a href="#">Adjusting LI-RADS category</a>	<a href="#">Diffuse</a>	<a href="#">LR1</a>	<a href="#">Radiologic T-staging</a>
<a href="#">Ancillary features</a>	<a href="#">Disappearance</a>	<a href="#">LR2</a>	<a href="#">Reporting</a>
<a href="#">Arterial phase</a>	<a href="#">Early arterial phase</a>	<a href="#">LR3</a>	<a href="#">Restricted diffusion</a>
<a href="#">Arterial phase hyper-enhancement</a>	<a href="#">Equivocal</a>	<a href="#">LR4</a>	<a href="#">Rounded</a>
<a href="#">Arterial phase hypo-enhancement</a>	<a href="#">Fade</a>	<a href="#">LR5</a>	<a href="#">Scar</a>
<a href="#">Arterial phase iso-enhancement</a>	<a href="#">Feature</a>	<a href="#">LR5 Treated</a>	<a href="#">Subcapsular</a>
<a href="#">Atypical</a>	<a href="#">Focal</a>	<a href="#">LR5V</a>	<a href="#">Suggestive</a>
<a href="#">Benign entity</a>	<a href="#">Focal scar</a>	<a href="#">Major features</a>	<a href="#">Table</a>
<a href="#">Blood products</a>	<a href="#">Hemangioma</a>	<a href="#">Management</a>	<a href="#">Technical requirements</a>
<a href="#">Capsule appearance</a>	<a href="#">Hepatic fat deposition</a>	<a href="#">Mass</a>	<a href="#">Threshold growth</a>
<a href="#">Categories</a>	<a href="#">Hepatic fat sparing</a>	<a href="#">Mild-moderate T2 hyper-intensity</a>	<a href="#">Tie-breaking rules</a>
<a href="#">Categorize</a>	<a href="#">Heterogeneous</a>	<a href="#">Mosaic architecture</a>	<a href="#">Treatment</a>
<a href="#">Cholangiocellular carcinoma</a>	<a href="#">Heterogeneous enhancement</a>	<a href="#">Nodule-in-nodule</a>	<a href="#">True tumor capsule</a>
<a href="#">Cirrhosis associated nodule(s)</a>	<a href="#">Homogeneous</a>	<a href="#">Nodule-like arterial phase hyper-enhancement (NAPH)</a>	<a href="#">Tumor in vein</a>
<a href="#">Confluent fibrosis</a>	<a href="#">Homogeneous enhancement</a>	<a href="#">Non-enhancement</a>	<a href="#">Undistorted vessels</a>
<a href="#">Corona enhancement</a>	<a href="#">Homogeneous marked T2 hyper-intensity</a>	<a href="#">Non-HCC Malignancy</a>	<a href="#">Unequivocal</a>
<a href="#">Cyst</a>	<a href="#">Homogeneous marked T2 or T2* hypo-intensity</a>	<a href="#">Observation</a>	<a href="#">Vascular anomaly</a>
<a href="#">Definite</a>	<a href="#">Hyper-enhancement</a>	<a href="#">OPTN Class 5</a>	<a href="#">Washout appearance</a>
<a href="#">Definite benign entities</a>	<a href="#">Hypertrophic pseudomass</a>	<a href="#">Other Malignancy</a>	<a href="#">Wedge-shaped</a>
<a href="#">Delayed phase</a>	<a href="#">Hypo-enhancement</a>	<a href="#">Overview</a>	
<a href="#">Delayed phase hypo-enhancement</a>	<a href="#">Increasing enhancement</a>	<a href="#">Parallels blood pool enhancement</a>	
<a href="#">Designate/designations</a>	<a href="#">Infiltrative HCC</a>	<a href="#">Patchy</a>	
<a href="#">Diagnostic</a>	<a href="#">Intralesional fat</a>	<a href="#">Perfusion alteration</a>	
<a href="#">Diameter</a>	<a href="#">Iron-rich CAN</a>	<a href="#">Perivascular</a>	
<a href="#">&lt;10mm</a>	<a href="#">Iso-attenuation</a>	<a href="#">Portal venous phase</a>	
<a href="#">10-19mm</a>	<a href="#">Iso-enhancement</a>	<a href="#">Portal venous phase hypo-enhancement</a>	
<a href="#">&lt; 20mm</a>	<a href="#">Iso-intensity</a>	<a href="#">Pre-contrast imaging</a>	
<a href="#">≥ 20mm</a>	<a href="#">Late arterial phase</a>	<a href="#">Probable</a>	
<a href="#">Diameter increase</a>	<a href="#">Lesional fat sparing</a>	<a href="#">Probable benign entities</a>	
<a href="#">Diameter reduction</a>	<a href="#">Lesional iron sparing</a>	<a href="#">Pseudocapsule</a>	
<a href="#">Diameter stability</a>			