

ACR–AIUM–SPR–SRU PRACTICE PARAMETER FOR THE PERFORMANCE OF THE ULTRASOUND EXAMINATION FOR DETECTION AND ASSESSMENT OF DEVELOPMENTAL DYSPLASIA OF THE HIP

Revised 2023 (Resolution 34)*

The American College of Radiology, with more than 30,000 members, is the principal organization of radiologists, radiation oncologists, and clinical medical physicists in the United States. The College is a nonprofit professional society whose primary purposes are to advance the science of radiology, improve radiologic services to the patient, study the socioeconomic aspects of the practice of radiology, and encourage continuing education for radiologists, radiation oncologists, medical physicists, and persons practicing in allied professional fields.

The American College of Radiology will periodically define new practice parameters and technical standards for radiologic practice to help advance the science of radiology and to improve the quality of service to patients throughout the United States. Existing practice parameters and technical standards will be reviewed for revision or renewal, as appropriate, on their fifth anniversary or sooner, if indicated.

Each practice parameter and technical standard, representing a policy statement by the College, has undergone a thorough consensus process in which it has been subjected to extensive review and approval. The practice parameters and technical standards recognize that the safe and effective use of diagnostic and therapeutic radiology requires specific training, skills, and techniques, as described in each document. Reproduction or modification of the published practice parameter and technical standard by those entities not providing these services is not authorized.

PREAMBLE

This document is an educational tool designed to assist practitioners in providing appropriate radiologic care for patients. Practice Parameters and Technical Standards are not inflexible rules or requirements of practice and are not intended, nor should they be used, to establish a legal standard of care¹. For these reasons and those set forth below, the American College of Radiology and our collaborating medical specialty societies caution against the use of these documents in litigation in which the clinical decisions of a practitioner are called into question.

The ultimate judgment regarding the propriety of any specific procedure or course of action must be made by the practitioner considering all the circumstances presented. Thus, an approach that differs from the guidance in this document, standing alone, does not necessarily imply that the approach was below the standard of care. To the contrary, a conscientious practitioner may responsibly adopt a course of action different from that set forth in this document when, in the reasonable judgment of the practitioner, such course of action is indicated by variables such as the condition of the patient, limitations of available resources, or advances in knowledge or technology after publication of this document. However, a practitioner who employs an approach substantially different from the guidance in this document may consider documenting in the patient record information sufficient to explain the approach taken.

The practice of medicine involves the science, and the art of dealing with the prevention, diagnosis, alleviation, and treatment of disease. The variety and complexity of human conditions make it impossible to always reach the most appropriate diagnosis or to predict with certainty a particular response to treatment. Therefore, it should be recognized that adherence to the guidance in this document will not assure an accurate diagnosis or a successful outcome. All that should be expected is that the practitioner will follow a reasonable course of action based on current knowledge, available resources, and the needs of the patient to deliver effective and safe medical care. The purpose of this document is to assist practitioners in achieving this objective.

1 *Iowa Medical Society and Iowa Society of Anesthesiologists v. Iowa Board of Nursing*, 831 N.W.2d 826 (Iowa 2013) Iowa Supreme Court refuses to find that the "ACR Technical Standard for Management of the Use of Radiation in Fluoroscopic Procedures (Revised 2008)" sets a national standard for who may perform fluoroscopic procedures in light of the standard's stated purpose that ACR standards are educational tools and not intended to establish a legal standard of care. See also, *Stanley v. McCarver*, 63 P.3d 1076 (Ariz. App. 2003) where in a concurring opinion the Court stated that "published standards or guidelines of specialty medical organizations are useful in determining the duty owed or the standard of care applicable in a given situation" even though ACR standards themselves do not establish the standard of care.

I. INTRODUCTION

The clinical aspects contained in specific sections of this practice parameter (Introduction, Indications and Contraindications, Specifications of the Examination, and Equipment Specifications) were revised collaboratively by the American College of Radiology (ACR), the American Institute of Ultrasound in Medicine (AIUM), the Society for Pediatric Radiology (SPR), and the Society of Radiologists in Ultrasound (SRU). Recommendations for Qualifications and Responsibilities of Personnel, Written Request for the Examination, Documentation, and Quality Control and Improvement, Safety, Infection Control, and Patient Education vary among the organizations and are addressed by each separately.

This practice parameter is intended to assist practitioners performing sonographic studies for detection and assessment of developmental dysplasia of the hip (DDH). Adherence to the following recommendations will maximize the probability of detecting most of the abnormalities that relate to acetabular morphology, position of the femoral head, and stability.

Selective screening is currently performed in the United States. The strongest risk factors for DDH are female sex, history of a parent and/or a sibling with DDH, birth weight >4000 g, abnormal physical exam [1-3], and breech presentation [4].

Ultrasound is the preferred method for diagnostic imaging of the infant hip [5,6]. It affords direct visualization of the cartilaginous and other components of the hip joint and permits a dynamic examination that can be used to assess hip stability. The value of ultrasound diminishes as the femoral head ossifies [2,7]. When the relationship between the femoral head and the triradiate cartilage cannot be adequately visualized, radiographs of the hips are indicated [3,4].

There are no absolute contraindications to ultrasound of the infant hip for DDH. Because of the presence of physiologic laxity, hip sonography is usually not performed on patients younger than 6 weeks of age, unless indicated based on an abnormal finding on physical examination [8].

II. INDICATIONS

A. Common indications for ultrasound of the infant hip include, but are not limited to:

1. Abnormal or equivocal findings of hip instability on physical examination
2. Any family history of DDH
3. Breech presentation at birth
4. Neuromuscular conditions
5. Monitoring infants with DDH undergoing treatment

B. Relative indications for ultrasound of the infant hip include, but are not limited to:

1. Oligohydramnios
Other intrauterine causes of postural molding
2. Leg length discrepancy
3. Asymmetric thigh creases

III. QUALIFICATIONS AND RESPONSIBILITIES OF PERSONNEL

See the [ACR–SPR–SRU Practice Parameter For The Performance And Interpretation of Diagnostic Ultrasound Examinations](#). [9]

IV. SPECIFICATIONS OF THE EXAMINATION

The written or electronic request for an ultrasound examination for detecting developmental dysplasia of the hip should provide sufficient information to demonstrate the medical necessity of the examination and allow for its proper performance and interpretation.

Documentation that satisfies medical necessity includes 1) signs and symptoms and/or 2) relevant history (including known diagnoses). Additional information regarding the specific reason for the examination or a provisional diagnosis would be helpful and may at times be needed to allow for the proper performance and interpretation of the examination.

The request for the examination must be originated by a physician or other appropriately licensed health care provider. The accompanying clinical information should be provided by a physician or other appropriately licensed health care provider familiar with the patient’s clinical problem or question and consistent with the stated scope of practice requirements. (ACR Resolution 35 adopted in 2006 – revised in 2016, Resolution 12-b)

Both hips should be examined. The diagnostic examination for DDH incorporates two orthogonal planes: a coronal view in the standard plane in neutral position and a transverse view of the flexed hip with and without stress, as defined below. This enables an assessment of hip position, acetabular morphology, and stability.

If position, acetabular morphology, and/or stability cannot be assessed when attempting to perform a complete examination, the report should note the portion not performed. It is acceptable to perform the examination with the infant in each lateral decubitus position .

For the complete exam, morphology is assessed with the hip flexed without and with stress. . The stress maneuver (posterior push maneuver) is performed to evaluate for hip instability with the hip and knee flexed and the thigh adducted (Barlow maneuver). If the femoral head is subluxated, subluxable, dislocated, or dislocatable, reducibility can be assessed by abducting and externally rotating the hip (Ortolani maneuver). It is important that the infant be relaxed when hips are assessed for instability. To increase comfort and cooperation, it is suggested that the infant be kept nothing by mouth (NPO) for 3 hours before the sonogram so that the baby may be fed during the examination to maximize relaxation unless it is clear that the hip is normally aligned after which gentle stress maneuvers may be applied [13].

IV. SPECIFICATIONS OF THE EXAMINATION

A. Coronal View

The anatomic coronal plane is approximately parallel to the infant’s body. If the superior edge of the transducer is rotated 10 to 15 degrees (usually posteriorly) into an oblique coronal plane, the ilium will appear straight. After adjustment to assure that the imaging plane extends through the deepest part of the acetabulum (including visualization of the triradiate cartilage and the ischium), the resulting image will be a coronal view in the standard plane.

The standard plane is defined by identifying a straight iliac line, the tip of the acetabular labrum, and the transition from the os ilium to the triradiate cartilage (see Fig. 1). The coronal view in the standard plane can be obtained with the hip in the physiologic neutral position (15- to 20-degree flexion). Femoral head position and acetabular morphology are assessed, and the alpha angle (normally ≥ 60 degrees) is measured [14,15]. Performance of stress in this plane may be helpful.

Figure 1–a. Coronal view: Ultrasound transducer is placed parallel to the lateral aspect of the baby’s hip

Figure 1-b. Coronal ultrasound image

Normal Hip Coronal Plane

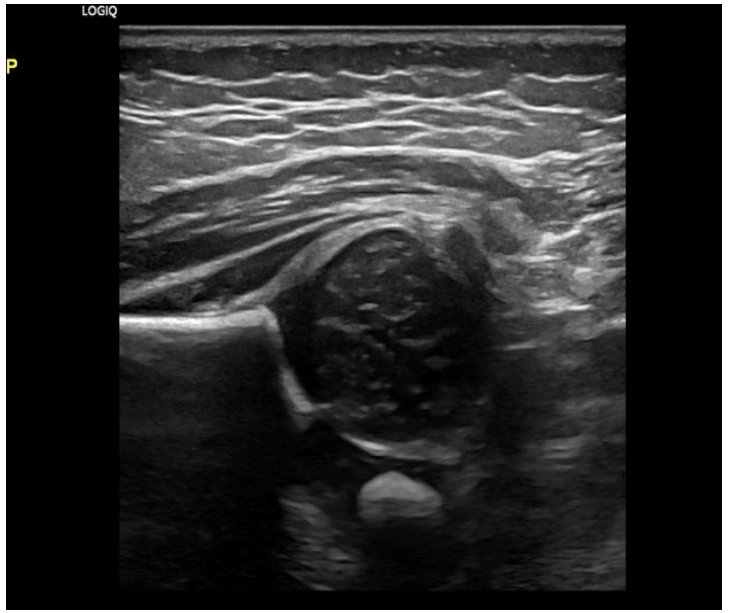
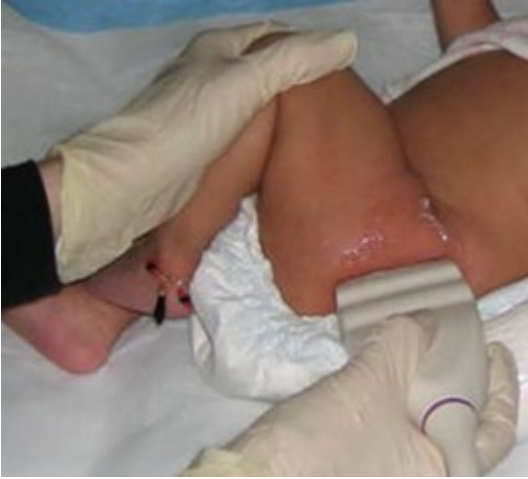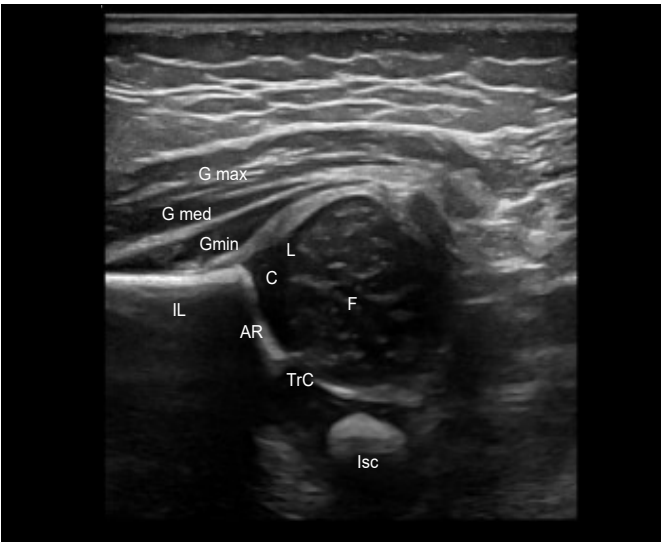


Figure 1-C. Labeled Coronal ultrasound image

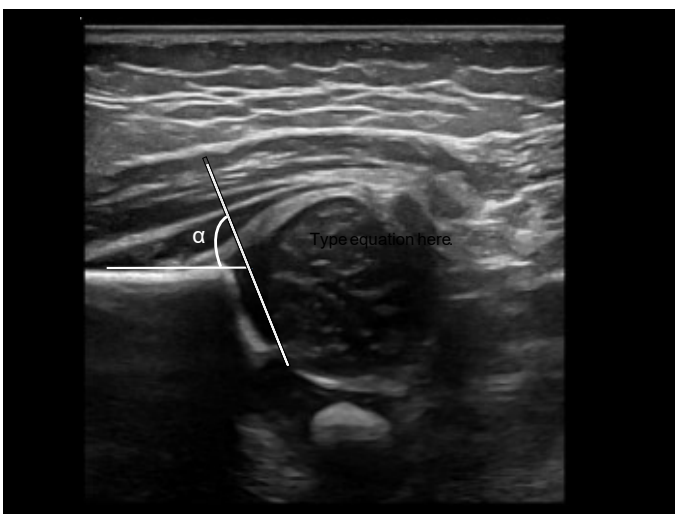
Normal Hip Coronal Plane



F	Femoral Head
Gmax	Gluteus maximus
Gmed	Gluteus medius
Gmin	Gluteus minimus
L	Labrum
IL	Iliac
AR	Acetabular Roof
Isc	Ischium
TrC	Triradiate cartilage

Figure 1-d. Coronal ultrasound image

Alpha angle measurement



IV. SPECIFICATIONS OF THE EXAMINATION

B. Transverse Flexion View

The examination is performed with the hip flexed at 90 degrees. The transverse plane is the anatomic transverse or axial plane with respect to the body, similar to the plane of an axial computed tomography (CT) image (Fig. 2). With the transducer nearly parallel to the femoral shaft, the femoral shaft is seen anteriorly, terminating in the femoral head, which rests on the ischium. The transducer is placed in a posterolateral position, parallel to the femoral shaft without stress. Next, gentle stress is applied to assess stability (Barlow maneuver). The Ortolani maneuver can be performed to test reducibility. Stress views are omitted when hips are being examined in a Pavlik harness or splint device.

Figure 2–a. Transverse flexion view: the hip and knee are flexed 90 degrees, and the ultrasound transducer is placed perpendicular to the lateral aspect of the baby’s hip nearly parallel to the femoral shaft

Figure 2–b. Transverse ultrasound
Normal Transverse View

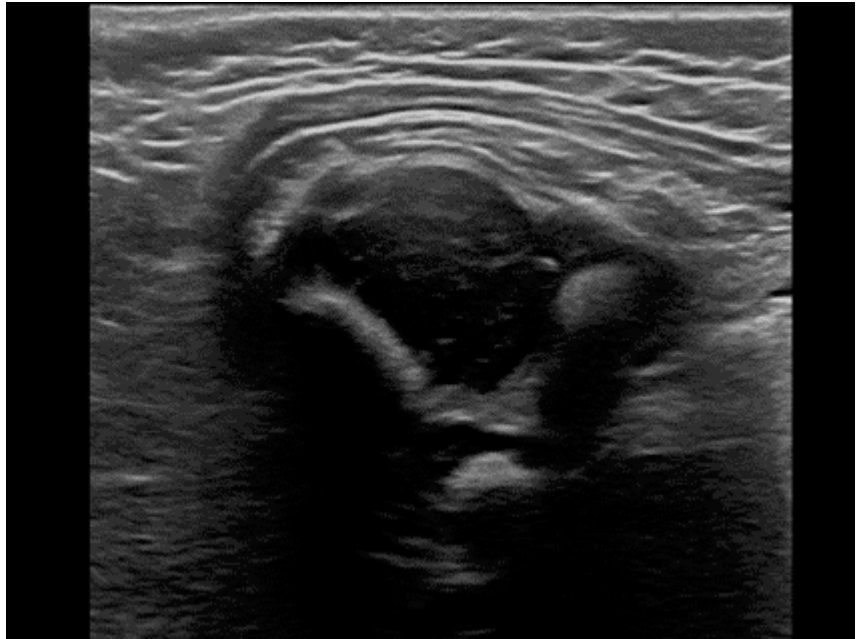
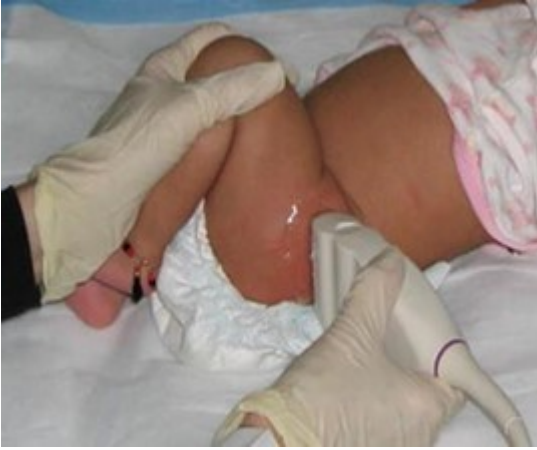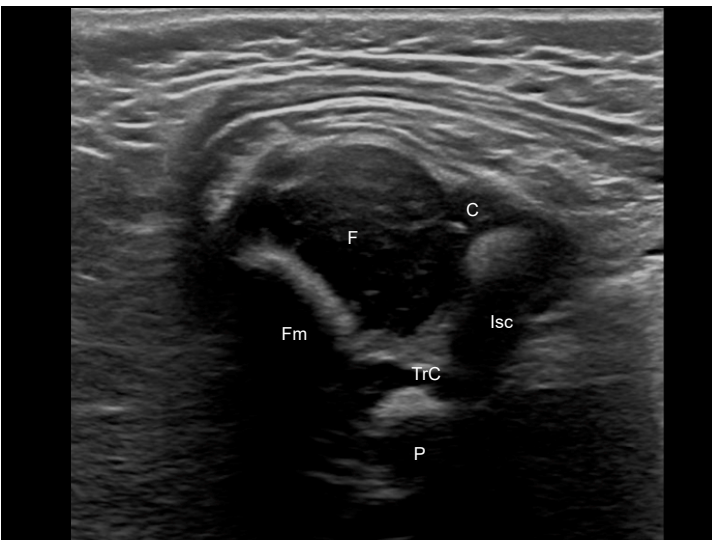


Figure 2–c. Labeled Transverse ultrasound image

Normal Transverse View



F	Femoral Head
Fm	Femoral Metaphysis
C	Acetabular Cartilage
P	Pubis
Isc	Ischium
TrC	Triradiate cartilage

V. DOCUMENTATION

Reporting should be in accordance with the [ACR Practice Parameter for Communication of Diagnostic Imaging Findings](#) [16].

Adequate documentation is essential for high-quality patient care. There should be a permanent record of the ultrasound examination and its interpretation. Comparison with prior relevant imaging studies may prove helpful. Images of all appropriate areas, both normal and abnormal, should be recorded. The Graf alpha angle should be measured because it is important for therapeutic decision making by orthopedic surgeons. Images should include patient identification, facility identification, examination date, hip being imaged, image orientation, and whether stress is being applied. An official interpretation (final report) of the ultrasound examination should be included in the patient's medical record, indicating acetabular morphology, position of femoral head, and stability [9]. Retention of the ultrasound examination images should be consistent both with clinical need and with relevant legal and local health care facility requirements.

VI. EQUIPMENT SPECIFICATIONS

Equipment performance monitoring should be in accordance with the [ACR-AAPM Technical Standard for Diagnostic Medical Physics Performance Monitoring of Real Time Ultrasound Equipment](#) [17].

Hip ultrasound for detecting DDH should be performed with a high-frequency linear transducer that permits penetration of the soft tissues. Total ultrasound exposure should be kept as low as reasonably achievable while optimizing diagnostic information.

VII. QUALITY CONTROL AND IMPROVEMENT, SAFETY, INFECTION CONTROL, AND PATIENT EDUCATION

Policies and procedures related to quality, patient education, infection control, and safety should be developed and implemented in accordance with the ACR Policy on Quality Control and Improvement, Safety, Infection Control, and Patient Education appearing under the heading *Position Statement on QC & Improvement, Safety, Infection Control, and Patient Education* on the ACR website (<https://www.acr.org/Advocacy-and-Economics/ACR-Position-Statements/Quality-Control-and-Improvement>).

ACKNOWLEDGEMENTS

This practice parameter was revised according to the process described under the heading *The Process for Developing ACR Practice Guidelines and Technical Standards* on the ACR website (<https://www.acr.org/Clinical-Resources/Practice-Parameters-and-Technical-Standards>) by the Committee on Practice Parameters – Ultrasound of the ACR Commission on Ultrasound and the Committee on Practice Parameters – Pediatric Radiology of the ACR Commissions on Pediatric Radiology in collaboration with the AIUM, the SPR, and the SRU.

Writing Committee – members represent their societies in the initial and final revision of this practice parameter

ACR

Sandra Allison, MD, FACR, FSRU, FAIUM, Co-Chair

Lynn A. Fordham, MD, FACR, FAIUM, FAAWR, Co-Chair

John Amodio, MD

AIUM

Susan J. Back, MD

Brian Douglas Coley, MD, FAIUM, FSRU, FACR, FAAP

Henrietta K. Rosenberg, MD, FACR

Arash R. Zandieh, MD

SPR

Patricia T. Acharya, MD, FAAP

Monica Epelman, MD

Judy Estroff, MD

SRU

Cassandra M. Sams, MD

Judy H. Squires, MD

Committee on Practice Parameters – Ultrasound

(ACR Committee responsible for sponsoring the draft through the process)

Nirvikar Dahiya, MD, FAIUM, FSRU, Chair

Michelle L. Melany, MD, FACR

Helena Gabriel, MD, FSRU, FACR, Vice Chair

Harriet J. Paltiel, MD

Javad Azadi, MD

Rupinder Penna, MD

Marcela Böhm-Velez, MD, FACR

Kristin L. Rebik, DO

Christopher Fung, MD

Judy H. Squires, MD

Jamie Hui, MD

Joel P. Thompson, MD

Committee on Practice Parameters – Pediatric Radiology

(ACR Committee responsible for sponsoring the draft through the process)

Terry L. Levin, MD, FACR, Chair

Jane Sun Kim, MD

Committee on Practice Parameters – Pediatric Radiology

John B. Amodio, MD, FACR

Jessica Kurian, MD

Tara M. Catanzano, MB, BCh

Helen R. Nadel, MD

Harris L. Cohen, MD, FACR

Erica Poletto, MD

Kassa Darge, MD, PhD

Richard B. Towbin, MD, FACR

Dorothy L. Gilbertson-Dahdal, MD

Andrew T. Trout, MD

Lauren P. Golding, MD

Esben S. Vogelius, MD

Adam Goldman-Yassen, MD

Jason Wright, MD

Safwan S. Halabi, MD

Lauren P. Golding, MD, Chair, Commission on Ultrasound

Richard A. Barth, MD, FACR, Chair, Commission on Pediatric Radiology

David B. Larson, MD, MBA, FACR, Chair, Commission on Quality and Safety

Mary S. Newell, MD, FACR, Chair, Committee on Practice Parameters and Technical Standards

Comments Reconciliation Committee

Lisa Ignacio, MD -CSC Chair

Lynn A. Fordham, MD, FACR, FAIUM, FAAWR

Nolan Kagetsu, MD-CSC Co-Chair

Amy L. Kotsenas, MD, FACR

Sandra Allison, MD, FACR, FSRU, FAIUM

Oliver Kripfgans, MD

John Amodio, MD

David A. Larson, MD

Patricia T. Acharya, MD, FAAP

Terry L. Levin, MD, FACR

Susan J. Back, MD

Mary S. Newell, MD, FACR

Richard A. Barth, MD, FACR

Lauren Nicola, MD

Comments Reconciliation Committee

Brian Douglas Coley, MD, FAIUM, FSRU, FACR, FAAP

Henrietta K. Rosenberg, MD, FACR

Timothy A. Crummy, MD, MHA, FACR

Cassandra M. Sams, MD

Nirvikar Dahiya, MD, FAIUM, FSRU

Judy H. Squires, MD

Monica Epelman, MD

Arash R. Zandieh, MD

Judy Estroff, MD

REFERENCES

1. Bache CE, Clegg J, Herron M. Risk factors for developmental dysplasia of the hip: ultrasonographic findings in the neonatal period. *Journal of pediatric orthopaedics. Part B* 2002;11:212-8.
2. Schaeffer EK, Study Group I, Mulpuri K. Developmental dysplasia of the hip: addressing evidence gaps with a multicentre prospective international study. *The Medical journal of Australia* 2018;208:359-64.
3. Roposch A, Protopapa E, Malaga-Shaw O, et al. Predicting developmental dysplasia of the hip in at-risk newborns. *BMC musculoskeletal disorders* 2020;21:442.
4. Oh EJ, Min JJ, Kwon S-S, et al. Breech Presentation in Twins as a Risk Factor for Developmental Dysplasia of the Hip. *Journal of Pediatric Orthopaedics* 2022;42:e55-e58.
5. Roposch A, Wright JG. Increased diagnostic information and understanding disease: uncertainty in the diagnosis of developmental hip dysplasia. *Radiology* 2007;242:355-9.
6. Smergel E, Losik SB, Rosenberg HK. Sonography of hip dysplasia. *Ultrasound quarterly* 2004;20:201-16.
7. Atalar H, Gunay C, Turanli S, Koktener A. Discrepancy between ultrasonographic and radiographic findings in patients treated for developmental dysplasia of the hip; hip maturation on ultrasonography may not be consistent with radiographic hip maturation. *Journal of pediatric orthopaedics. Part B* 2020;29:228-34.
8. Mulpuri K, Song KM, Gross RH, et al. The American Academy of Orthopaedic Surgeons Evidence-Based Guideline on Detection and Nonoperative Management of Pediatric Developmental Dysplasia of the Hip in Infants up to Six Months of Age. *J Bone Joint Surg Am* 2015;97:1717-8.
9. American College of Radiology. ACR–SPR–SRU Practice Parameter For The Performance And Interpretation of Diagnostic Ultrasound Examinations. Available at: <https://www.acr.org/-/media/ACR/Files/Practice-Parameters/us-perf-interpret.pdf?la=en>. Accessed February 7, 2022.
10. Harcke HT, Grissom LE. Performing dynamic sonography of the infant hip. *AJR. American journal of roentgenology* 1990;155:837-44.
11. Morin C, Harcke HT, MacEwen GD. The infant hip: real-time US assessment of acetabular development. *Radiology* 1985;157:673-7.
12. Grissom L, Harcke HT. Pearls and Pitfalls of Hip Ultrasound. *Seminars in ultrasound, CT, and MR* 2020;41:513-17.
13. Grissom LE, Harcke HT, Kumar SJ, Bassett GS, MacEwen GD. Ultrasound evaluation of hip position in the Pavlik harness. *Journal of ultrasound in medicine : official journal of the American Institute of Ultrasound in Medicine* 1988;7:1-6.
14. Harcke HT, Pruszczynski B. Hip ultrasound for developmental dysplasia: the 50% rule. *Pediatric radiology* 2017;47:817-21.
15. Graf R. Hip sonography: background; technique and common mistakes; results; debate and politics; challenges. *Hip Int* 2017;27:215-19.
16. American College of Radiology. ACR Practice Parameter for Communication of Diagnostic Imaging Findings. Available at: <https://www.acr.org/-/media/ACR/Files/Practice-Parameters/CommunicationDiag.pdf>. Accessed February 7, 2022.

17. American College of Radiology. ACR-AAPM Technical Standard for Diagnostic Medical Physics Performance Monitoring of Real Time Ultrasound Equipment. Available at: <https://www.acr.org/-/media/ACR/Files/Practice-Parameters/US-Equip.pdf>. Accessed February 7, 2022.

*Practice parameters and technical standards are published annually with an effective date of October 1 in the year in which amended, revised, or approved by the ACR Council. For practice parameters and technical standards published before 1999, the effective date was January 1 following the year in which the practice parameter or technical standard was amended, revised, or approved by the ACR Council.

Development Chronology for this Practice Parameter
1998 (Resolution 30)

Revised 2003 (Resolution 21)

Amended 2006 (Resolution 35)

Revised 2008 (Resolution 10)

Revised 2013 (Resolution 15)

Amended 2014 (Resolution 39)

Revised 2018 (Resolution 24)

Revised 2023 (Resolution 34)